

Kyphoscoliotic type of Ehlers Danlos syndrome in siblings

Le syndrome d'Ehlers Danlos de type cyphoscoliotique dans une fratrie

Kaissi A.¹, Smida M.², Ben Chehida F.³, Nassib M.N.², Ben Ghachem M.²

1- Orthopaedic Hospital of Speising, Paediatric Department, Vienna - Austria

2- Service d'Orthopédie Infantile, Hôpital d'Enfants de Tunis, Tunis - Tunisia

3- Center of Radiology- Department of Imaging Studies-Ibn Zohr Institute, Tunis - Tunisia

CORRESPONDENCE: **Dr Ali Al Kaissi**

Orthopaedic Hospital of Speising, Speisinger strasse 109, Vienna 1130, Austria

E-mail: ali.alkaissi@osteologie.at

I. ABSTRACT

We report on a 14-year-old boy and his younger female sibling of first related parents presented with awkward motor development, progressive kyphoscoliosis, joint dislocations, easy bruising, and hyper-elastic skin. The overall phenotypic features were suggestive of kyphoscoliotic type of Ehlers-Danlos syndrome (EDS).

The initial diagnosis for the older male sib in his first year of life was congenital myopathy and was labelled as non-heritable. Despite the normalcy of the repeated neuromuscular investigations, no further attempts were made to elicit the correct diagnosis. It is mandatory that the kyphoscoliotic type of EDS should be considered in the differential diagnosis of floppy infant syndrome.

II. INTRODUCTION

Ehlers-Danlos syndromes (EDS) form a heterogeneous group of hereditary connective tissue diseases characterized by joint hyperlaxity, cutaneous hyperelasticity and tissue fragility. The kyphoscoliotic form, formerly called EDS type VI or oculo-scoliotic EDS, is marked from birth onwards by progressive congenital scoliosis, severe muscle hypotonia, hyperextensibility of all joints, and fragile eyeballs. Ocular fragility can lead to retinal haemorrhage, glaucoma, scleral coloration, or even rupture of the ocular globe. The disease is very rare and is transmitted as an autosomal recessive trait. It is due to lysyl-hydroxylase deficiency, an enzyme involved in posttranslational modification of lysine in the alpha pro-chains of collagen. The LH1 gene (or PLOD gene) that codes for the enzyme is located on the short arm of chromosome 1 (1p36); it has been cloned and homozygous or compound heterozygous mutations have been identified in patients affected by kyphoscoliotic EDS. Type VIB is defined by normal lysyl-hydroxylase activity but mutations have been reported in the LH2 or LH3 genes (1-4). Our patients manifested skin features similar to those of

EDS type I. Blue sclerae, small corneas associated with generalized muscular weakness, spontaneous dislocations, arachnodactyly, progressive kyphoscoliosis and marfanoid habitus were present. The aim of this paper is two fold. First; the constellation of unusual physical features in neonatal period such as hypotonia, kyphoscoliosis, hyper-elastic skin and arachnodactyly in a consanguineous family should be considered as features in favor of kyphoscoliotic type EDS. Second; the kyphoscoliotic type of EDS is a rare autosomal recessively inherited disorder very much akin to myopathy.

III. CLINICAL REPORT

Because of hypotonia and delay in gross motor development, a neuromuscular disease was suspected. A series of vigorous neuromuscular investigations yielded normal results. These siblings were referred to our department for clinical assessment and diagnosis. They were the products of consanguineous parents (first cousins), born at term after uneventful gestation. Hypotonia since birth associated with kyphoscoliosis were developed in the neonatal period associated with hip and radio-humeral dislocations. The older male sib showed retarded motor development. A neuromuscular disorder was the prime diagnosis because of the severe floppiness. Extensive and repeated neuromuscular investigations (including muscle biopsy and electromyography) were normal. Clinical examination of the male sib showed a Marfanoid habitus associated with marked muscular weakness. Craniofacially they manifested ptosis, blue sclerae, downslanting palpebral fissures, ectropion, and long nose, puckering mouth, short philtrum and macrognathia (Figure 1). The skin was velvety and hype-elastic. He manifested thin and long extremities, the joints were hyperextensible and some were dislocated. Wrist drop associated with arachnodactyly were noted. Deep tendon reflexes were reduced as well as vibration sense in feet bilaterally and

impaired tandem gait (features suggestive of motor sensory neuropathy) were present.



Figure 1: Showed the phenotype of the male and female siblings; there was a Marfanoid habitus associated with marked muscular weakness. Craniofacially they manifested ptosis, downslanting palpebral fissures, ectropion, and long nose, puckering mouth, short philtrum and micrognathia

Neurological examination of the female sibling was normal. Her motor activity was normal. Progressive kyphoscoliosis, hyper-elastic skin, and hypermobility of joint but with and no dislocations were present. Her muscular mass was almost normal. Both siblings showed similar craniofacial dysmorphic features and they were of normal intelligence.

On the bases of skeletal survey; Anteroposterior hand radiograph showed arachnodactyly and wrist drop (Figure 2).

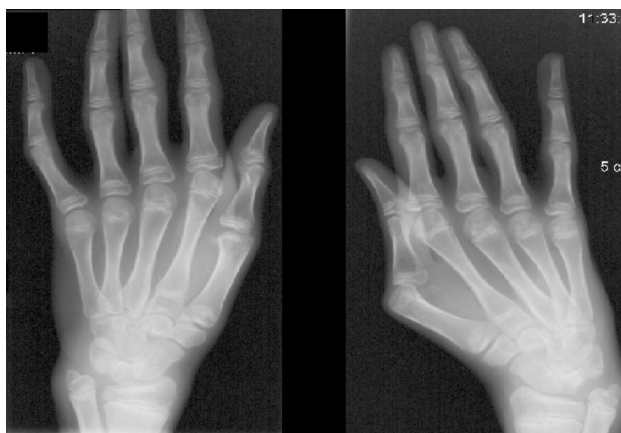

Figure 2: Anteroposterior hand radiograph showed arachnodactyly, wrist drop.

Anteroposterior spine radiograph showed severe thoraco-lumbar kyphoscoliosis (fig 3). Anteroposterior pelvis radiograph showed drastic unilateral hip dislocation and shortened femoral necks (fig 4). Serum kinase (CPK) was normal and other investigations including abdominal ultrasound, karyotyping, and metabolic tests, which aimed to test calcium, phosphorus, and vitamin D metabolism

were normal. The orthopaedic treatment of these children was symptomatic.

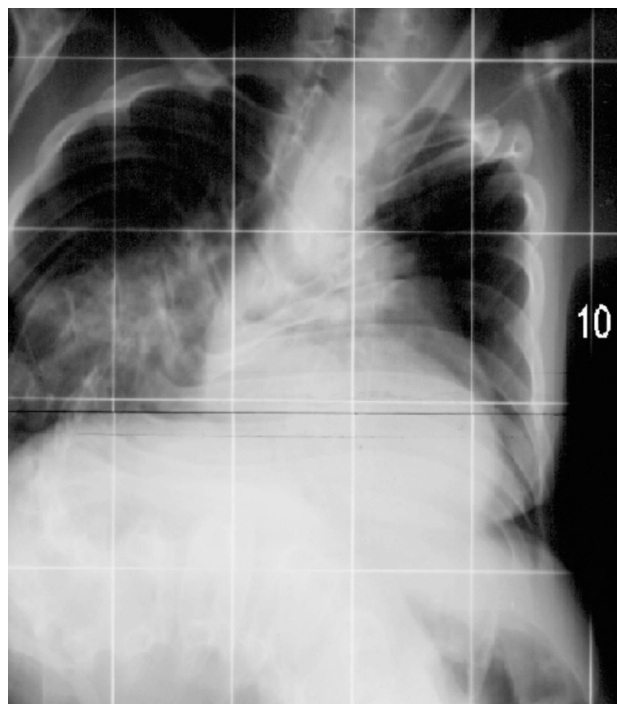


Figure 3: Anteroposterior spine radiograph showed severe thoraco-lumbar kyphoscoliosis.

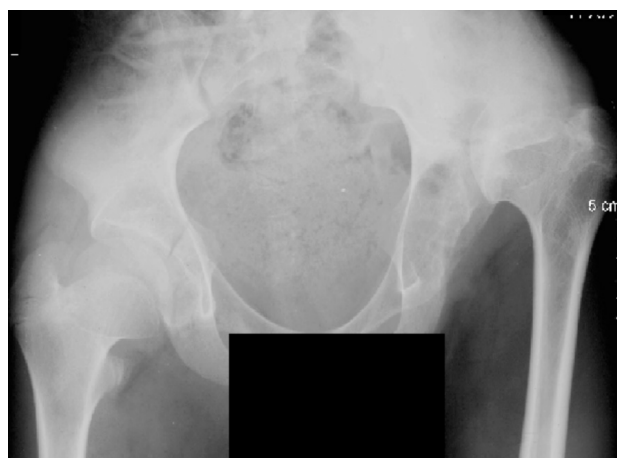

Figure 4: Anteroposterior pelvis radiograph showed drastic unilateral hip dislocation and shortened femoral necks.

IV. DISCUSSION

The kyphoscoliotic type of Ehlers-Danlos syndrome (EDS VI) is an inherited connective tissue disorder characterized by hypotonia and kyphoscoliosis at birth, joint hypermobility, and skin hyperelasticity and fragility. Biochemically, it is characterized by a deficiency of collagen lysyl hydroxylase (EC 1.14.11.4) due to mutations in PLOD1. This deficiency results in underhydroxylation of collagen lysyl residues and, hence, an abnormal pattern of lysyl pyridinoline (LP) and hydroxylysyl pyridinoline (HP) crosslinks excreted in the urine (1-4). Infants with floppyness are usually suspected to have congenital muscular dystrophy (autosomal recessive). Therefore, vigorous neuromuscular investigations have been carried out on these siblings and the results were completely normal. On the

other hand, children with congenital muscular dystrophy (Bethem myopathy) which is an autosomal dominant type may never walk independently. Proximal contractures associated with hyperextensibility of distal joints and early onset respiratory failures are characteristic features (1,5). Previous reports described different associations of malformation complex in patients with EDS type VI.

Pope and Burrows (6) point out that scoliosis is a consistent feature. This condition is also called the kyphoscoliotic form of EDS. Criss-cross lines on the soles and palms are also typical of EDS VI. Pinnell et al., (7) demonstrated a deficiency of lysyl hydroxylase. Those without the deficiency of lysyl hydroxylase are termed VIB. Kosho et al., (8) reported 2 unrelated girls with type VI B and increased the phenotype to include, ptosis, downslanting palpebral fissures, ectropion, short nose, small mouth and long philtrum. Tubular stenosis was prominent. Brunk et al., (9) reported a girl with the kyphoscoliotic type who had cystic malformation of the meninges and spinal cord. Vitreous haemorrhage and detachment were reported by Chikamoto et al., (10). Steinmann et al., (1) suggested that measurement of urinary pyridinium cross-links was a good screening test for the condition. Hautala et al., (11) demonstrated mutations in cases with EDS type VI.

V. CONCLUSION

Kyphoscoliotic type of EDS is a rare autosomal recessive disorder and has to be differentiated from congenital muscular dystrophies. Noteworthy clinical features in our patients of characteristic facial features, Marfanoid habitus associated with floppiness, dislocations, progressive kyphoscoliosis, ocular abnormalities associated with polyneuropathy in the male sib along with normal neuromuscular investigations were in favour of the diagnosis of EDS type VI. Due to logistical reasons we were unable to perform lysyl-hydroxylase activity in our patients. Finally we wish to stress that lack of awareness toward the reading of striking clinical features, can mislead pediatricians and neurologists about disorders mimicking myopathy.

VI. REFERENCES

- 1) Steinmann B, Royce PM and Superti-Furga A. The Ehlers-Danlos syndrome. In: P.M. Royce and B. Steinmann, Editors, *Connective Tissue and its Heritable Disorders* (2nd ed.), Wiley, New York (2002), pp. 431-523
- 2) Farag TI, Schimke RN. Ehlers-Danlos syndrome: a new oculo-scoliotic type with associated polyneuropathy?. *Clin Genet* 1989;35:121-124.
- 3) Ha VT, Marshall MK, Elsas LJ, et al. A patient with Ehlers-Danlos syndrome type VI is a compound heterozygote for mutations in the lysyl hydroxylase gene. *J Clin Invest* 1994;93:1716-1721.
- 4) Heim P, Raghunath M, Meiss L, Heise U, Myllyla R, Kohlschutter A, Steinmann B. Ehlers-Danlos syndrome type VI (EDS VI): problems of diagnosis and management. *Acta Paediatr* 1998;87:708-711.
- 5) Lampe AK and Bushby KM, Collagen VI related muscle disorders, *J Med Genet* 42 (2005), pp. 673-685.
- 6) Pope FM, Burrows NP. Ehlers-Danlos syndrome has varied molecular mechanisms. *J Med Genet* 1997;34:400-410.
- 7) Pinnell SR, Krane SM, et al. Heritable disorder with hydroxyllysine-deficient collagen: hydroxyllysine-deficient collagen disease. *New Engl J Med* 1972;286:1013-1020.
- 8) Kosho T, Takahashi J, Ohashi H, et al. Ehlers-Danlos syndrome type VIB with characteristic facies, decreased curvatures of the spinal column, and joint contractures in two unrelated girls. *Am J Med Genet* 2005;138A:282-287.
- 9) Brunk I, Stover B, Ikonomidou C, Brinckmann J, Neumann LM, et al. Ehlers-Danlos syndrome type VI with cystic malformations of the meninges in a 7-year-old girl. *Eur J Pediatr* 2004;163:214-217.
- 10) Chikamoto N, Teranishi S, Chikama T-i, et al. Abnormal retinal blood vessels in Ehlers-Danlos s Hautala T, Heikkinen J, Kivirikko KI, Myllyla R. A large duplication in the gene for lysyl hydroxylase accounts for the type VI variant of Ehlers-Danlos syndrome in two siblings. *Genomics* 1993;15:399-404.
- 11) Hautala T, Heikkinen J, Kivirikko KI, Myllyla R. A large duplication in the gene for lysyl hydroxylase accounts for the type VI variant of Ehlers-Danlos syndrome in two siblings. *Genomics* 1993;15:399-404.

