

KNOW Homoeopathy Journal

Bi-Annual, Indexed, Double-Blind, Peer-Reviewed, Research Scholarly, Online Journal in Field of Homoeopathy

KNOW Homoeopathy Journal Vol-4 & Issue-2, 18 October 2024, Published at

<https://www.knowhomoeopathyjournal.com/2024/10/volume-4-issue-2.html>, Pages: 68-74, Title: Herpes zoster: A case report on clinical manifestation and homoeopathic management, Authored By: Dr. Gayatri Deka (M.D (Hom.) Part-1, Batch 2021-2024, PG Department of Materia Medica, Bakson Homoeopathic Medical College And Hospital, Greater Noida, Uttar Pradesh, India.)



VOLUME-4 ISSUE-2
OCTOBER 2024

CASE-REPORT

Title: Herpes zoster: A case report on clinical manifestation and homoeopathic management

Authored By: Dr. Gayatri Deka

M.D (Hom.) Part-1, Batch 2021-2024, PG Department of Materia Medica, Bakson Homoeopathic Medical College And Hospital, Greater Noida, Uttar Pradesh, India.

ABSTRACT

Herpes Zoster (SHINGLES) a viral syndrome caused by reactivation of the latent varicella zoster virus. It is secondary to varicella (chicken pox) and is most common after the 6th decade of life, though it is also seen in individuals with weakened immunity. It is clinically manifested as a fluid filled blister with severe burning pain. This is a pictorial evidence based case report on how individualized similimum can act so fast in acute cases where immediate resolution is required.

Keywords:

Arsenicum album, Clinical manifestation, Herpes zoster, Varicella zoster

Received: 07/04/2024

Accepted: 30/04/2024

Published: 18/10/2024

How to cite this case report:

Deka G. Herpes zoster: A case report on clinical manifestation and homoeopathic management, 2024; 4(2):68-74, available at <https://www.knowhomoeopathyjournal.com/2024/10/Herpes-zoster-case-report-on-clinical-manifestation-and-homoeopathic-management.html>

© 2024 KNOW Homoeopathy Journal

[Know more about Journal's Copyright Policy](#)<https://www.knowhomoeopathyjournal.com/p/copyright-policy.html>

Scan-Quick Response Code

INTRODUCTION

Herpes Zoster is a sporadic disease commonly known as Shingles, derived from the latin word cingulum means, "belt" or "girdle", as the rash commonly appears in a band or belt-like sample that is why it is named so. Varicella zoster is the virus responsible for the causation of both chicken pox and herpes zoster^[1,2,5] It is a double stranded DNA virus which has the ability to remain dormant for lifelong and periodically reactivate. The former is due to primary infection of the virus which after treatment remains dormant in the sensory ganglia or dorsal root ganglia which due to the failure of immune defence leads to the replication of the virus and reactivation of infection. The dermatomes from T3 to L3 are most frequently involved.^[6] The immune status and the incidence of herpes is strongly correlated.^[3,6] The incidence of Herpes Zoster ranges from 1.2 to 3.9 per 1000 persons per year among younger adults to 3.9- 11.8 per 1000 persons per year in elderly patients(ie.>65 years).^[3] ICD 10 code for Herpes zoster is B02 ^[4]Age, stress, immune compromised status, immunosuppressive drugs are known factors for virus reactivation:^[8]

It begins with prodromal symptoms (pre eruptive stage) such as fever, malaise, headache, pain, burning discomfort in the affected dermatome, occasionally paraesthesia ,few days before the eruption of rash .Clinically the eruptions appear (eruptive stage) as characteristic skin lesions such as erythematous papules or macules which progress to vesicles in 12-24 hours,

to pustules in 1-7 days, and eventually crust over in 14-21 days. ^[6,7]

CASE**PRESENT COMPLAINT**

A 31 years old male patient presented with complaints of sudden severe pain with intense burning, small blisters in multiple areas first in the right side of lower trunk (above buttock) and then on rt. Inguinal region. It was very painful even wearing pant was difficult with < night. The patient consulted me 2 days after the 1st eruptions had appeared.

HISTORY OF PRESENT COMPLAINT

The pt. was having body ache and was feeling very tired since 3 days, which lead to burning pain and itching in the affected area one day prior to the appearance of blisters.

PAST HISTORY:

He has suffered from chicken pox at 10years of age.

History of H.pylori infection 5yrs ago

Suffered from COVID 19 at 2020 and again at 2021

FAMILY HISTORY:

Demise of father 4 months ago due to Multi system failure.

Mother has been operated for Cholelithiasis

Younger Sister: Healthy

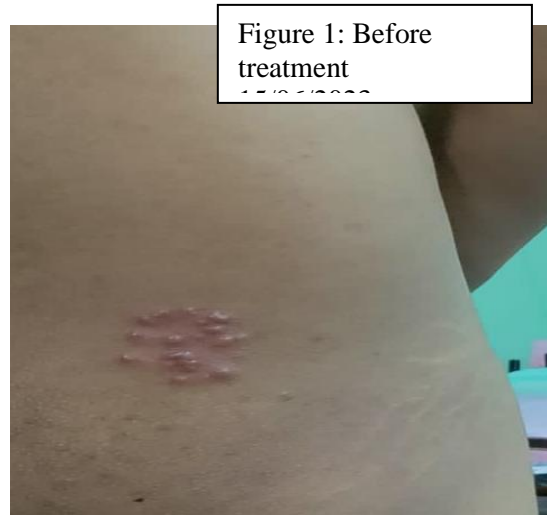PHYSICAL GENERALS:**Appetite:** Diminished since 3-4 months**Thirst:** Thirsty**Cravings:** N/S**Aversions:** N/S**Stool:** Irregular, passes every alternate days**Sleep:** Disturbed, due to pain**Thermal:** Chilly**Life Space :**

The patient is a banking professional and is always under heavy workload due to which he is under utmost stress. And the sudden demise of his father affected him deeply, he was stressed about the family and now felt he must do everything for his mother and sister. The patient was very much anxious about his eruptions and constantly inquiring about if there is anything serious, also asking about the expenses in the treatment as he has some life insurance policy from his bank. Extremely restless even after assuring that there is nothing serious constantly inquiring. When asked what is bothering him he replied please do something to reduce the pain , right

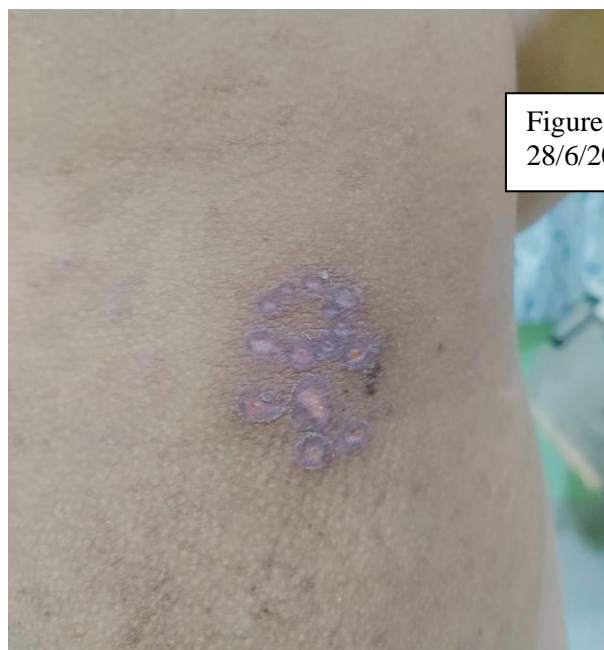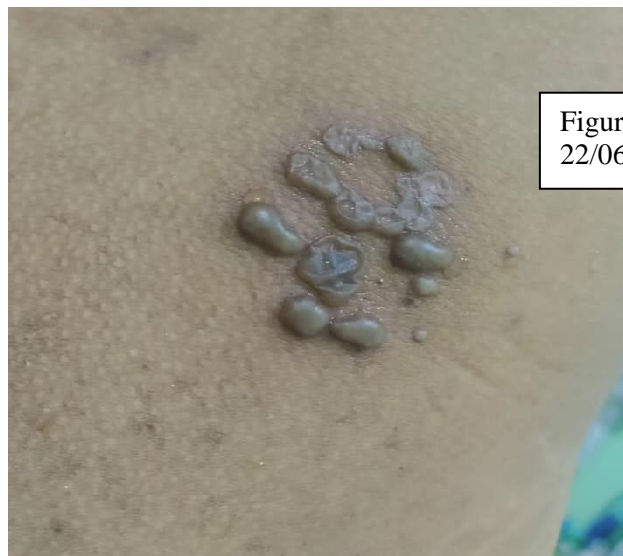now it is bothering me the most ,I can't even wear my formal pant properly to office I am wearing loose track pants there . I want my pain to be reduced anyhow. On asking more about his feeling he said his father has died few months ago and now he can't fall sick he just want to get well soon.

PHYSICIAN'S OBSERVATION:

The patient looked clean and nicely dressed though when he first came I did not know he was in so much pain unless he started explaining his symptoms very distressfully. He had shared the images via WhatsApp where it was seen that the he had multiple blisters, which after treatment has recovered.



The images via WhatsApp



PROBABLE DIAGNOSIS: Herpes Zoster (clinical basis)

ANALYSIS OF CASE

Mental generals:

- Worries about family++
- Anxious about pain+++
- Restlessness +++

Physical generals:

- Thirst: Extreme
- Thermal : Chilly

Particulars :

- Painful Blister+++
- Burning sensation +++

MIASMATIC ANALYSIS: Syco syphilis

REPERTORIZATION:

After analysis, Repertorization was done.

- **Working Method:** Computer method
- **Software used:** RADAR




Figure 5: Repertorization

RUBRIC SELECTION/ SYMPTOMS INTERPRETATION

1. MIND- CARES, full of- others, about : As he mentioned that he has to take care of his mother and sister after his father sudden demise
2. MIND- Carried – desire to be carried – fast: As he wanted anyhow the pain to be reduced
3. MIND- Fear- disease, of impending – incurable, of being: As he wanted constant assurance about the treatment and the disease if it serious
4. SKIN- ERUPTIONS-burning-night
5. STOMACH-THIRST-extreme

First prescription was given on 15th of June 2023, Arsenic album 200C /4 pills/ BD for 2 days based on individual similimum.

TABLE-1: FOLLOW UPS

DATES OF FOLLOW UP	SYMPTOMS	PRESCRIPTION + REMARKS
15/06/2023	Burning painful blisters, even touch of cloth was painful. Multiple vesicles were seen on the affected area.	Rx Ars alb 200C/4 pills /BD x 2 days
17/06/2023	Eruptions slightly increase in size, burning pain slightly decreased	Sac Lac 200C/ 4 pills x 5 days
22/06/2023	Eruptions reduced, marked decrease in pain	Sac Lac 200C/ 4 pills x 3days
28/06/2023	Blisters gone completely with marked improvement, Mentally also he was feeling better and body ache was reduced, malaise reduced. Sleep improved	Sac Lac 200C/ 4 pills x 2 days

DISCUSSION AND JUSTIFICATION

After taking the case it was very clear that the patient was distressed about his pain and wanted assurance about his treatment, so by looking into his sufferings then forming the totality, on repertorization Arsenic album came as the closest remedy which covered both his mental and physical state. If we look into the psyche of Arsenic individuals, they are very hard to reassure, if you tell him that everything will be alright, he may stop his pacing for a moment and then return to his despair and his agitation as if nothing has been said. They may surface occasionally as an irrational fear that finances are running out, that the spot on his arm is malignant, or that his children have some serious illness. They have insecurity in the background of their nature.^[9] On the physical plane Arsenic has vesicular eruptions, herpes, with vesicles, and violently burning, esp. at night.^[10]

Herpes zoster is clinically diagnosed with burning pain and characteristic unilateral dermatomal rash which begins with the appearance of macules and papules then

progress to pustules and crusts.^[11,12] The cutaneous eruptions in herpes zoster may be similar to herpes simplex, dermatitis herpetiformis, impetigo, contact dermatitis, drug reactions and insect bites.^[12] The post herpetic complications were not seen.

CONCLUSION

This case showed how the totality of symptom guided us to individualised similimum which gave relief to the patient from the very first day and also the impact of homoeopathic treatment in managing acute cases where immediate resolution is required.

DECLARATION OF PATIENT CONSENT

The author has taken consent from the patient for sharing their personal information and the clinical images of the case for publication purpose only. The confidentiality of the patient was maintained.

REFERENCES

1. Rai NP, Chattopadhyay J, Ghanta S. Herpes zoster infection of maxillary and mandibular branch: A case report and current trends in management. Available from: http://www.ijcmr.com/uploads/7/7/4/6/77464738/_herpes_zoster_infection_of_maxillary_and_mandibular_branchpo.pdf [[Last Accessed 15 October 2024]
2. Kala N, Role of lesser known homoeopathic medicines in the management of herpes zoster. *International Journal of Creative Research Thoughts*. 2023 Jan 11 (1); e292-296
3. Nair PA, Patel BC. Herpes zoster. In: *StatPearls*. Treasure Island (FL): StatPearls Publishing; 2024.
4. ICD 10 version 2019. Available from: <https://icd.who.int/browser10/2019/en#/B01.2> [Last Accessed on 24 Feb 24]
5. Soni A. Herpes zoster: a case series with varied clinical presentation. *Indian Journal of Case Reports*. 2018 Jul 31;4(4):253-7
6. Loscalzo J. *Harrison's principles of internal medicine*, twenty-First Edition . McGraw-Hill Education; 2022; p.1479-1481
7. Jianbo W, Koshy E, Mengting L, Kumar H. Epidemiology, treatment and prevention of herpes zoster: A comprehensive review. *Indian Journal of Dermatology, Venereology and Leprology*. 2018;84(3):251.
8. Parkar MissS, Kegade P, Gade A, Sawant R. A review on - herpes zoster. *Asian Journal of Research in Pharmaceutical Science*. 2020;10(4):282-6.
9. Baily PM. *Homoeopathic Psychology: Personality Profile of the Major Constitutional Remedies*. 16 th impression. USA-Europe-India: B.Jain publishers;2020;p. 16-27
10. Clarke JH. *A Dictionary Of Practical Materia Medica*. 36 th impression Vol 1. USA-Europe-India: B.Jain publishers;2020; p. 177-186
11. Schmader KE, Dworkin RH. Natural history and treatment of herpes zoster. *The Journal of Pain*. 2008 Jan;9(1):3-9.
12. Patil A, Goldust M, Wollina U. Herpes zoster: A review of Clinical Manifestations and management. *Viruses*. 2022 Jan 19;14(2):192.