

KNOW Homoeopathy Journal

Bi-Annual, Indexed, Double-Blind, Peer-Reviewed, Research Scholarly, Online Journal in Field of Homoeopathy

KNOW Homoeopathy Journal Vol-4 & Issue-2, 18 October 2024, Published at

<https://www.knowhomoeopathyjournal.com/2024/10/volume-4-issue-2.html>, Pages: 35-43, Title: A case of allergic dermatitis with hypothyroidism an evidence-based case, Authored By: Dr.Sangeeta Doshi (Professor,HOD, Dept.of Homoeopathic Materia Medica, Smt. K.B.Abad Homoeopathic Medical College, Chandwad, Nashik, Maharashtra State, India.) & Co-Authored By: Dr. Nilesh Deore (MD II (Practice of Medicine), Smt. K.B.Abad Homoeopathic Medical College, Chandwad, Nashik, Maharashtra, India.)



VOLUME-4 ISSUE-2
OCTOBER 2024

CASE-REPORT

Title: A case of allergic dermatitis with hypothyroidism an evidence-based case

Authored By: Dr. Sangeeta Doshi ^[1] & Co-Authored By: Dr. Nilesh Deore^[2]

^[1] Professor, HOD, Dept.of Homoeopathic Materia Medica, Smt.K.B.Abad Homoeopathic Medical College, Chandwad, Nashik, Maharashtra, India.

^[2]MD II (Practice of Medicine), Smt.K.B.Abad Homoeopathic Medical College, Chandwad, Nashik, Maharashtra, India.

ABSTRACT

Hypothyroidism is a common endocrine disorder very prevalent nowadays ,attributed especially to lifestyle and stress. Holistic approach of homeopathic treatment is most preferable in such cases with very good results presenting a case of hypothyroidism with allergic dermatitis of a female 47 years old suffering from allergic dermatitis and on examination revealed hypothyroidism.in this article a case of allergic dermatitis with hypothyroidism was treated with a well-selected homoeopathic constitutional remedy along with sarcode after a detailed case taking and repertorization. Patient recovered from dermatitis as well as TSH levels are reduced within six months of homoeopathic treatment.

Keywords: *Allergic dermatitis, Hypothyroidism, Homoeopathy, Constitutional medicine, Sarcode*

ABBREVIATIONS: C/O: Complaint of; BD: Twice a day, &: and; OD: Once a day; SD: Single dose

Received: 23/12/2023

Accepted: 28/04/2024

Published: 18/10/2024

How to cite this case report:

Doshi S, Deore N. A case of allergic dermatitis with hypothyroidism an evidence-based case, KNOW Homoeopathy Journal, 2024; 4(2):35-43, available at <https://www.knowhomoeopathyjournal.com/2024/10/case-allergic-dermatitis-with-hypothyroidism-an-evidence-based-case.html>

© 2024 KNOW Homoeopathy Journal

[Know more about Journal's Copyright Policy](https://www.knowhomoeopathyjournal.com/p/copyright-policy.html)<https://www.knowhomoeopathyjournal.com/p/copyright-policy.html>

Scan-Quick Response Code

INTRODUCTION

Hypothyroidism is a common endocrine disorder caused by a lack of thyroid hormones. This condition is also called hypothyroidism. The onset of hypothyroidism is insidious in most cases, and symptoms may appear relatively late in the disease process.

Primary hypothyroidism is caused by a disease of the thyroid gland itself. It accounts for approximately 99% of cases, with <1% due to TSH deficiency known as central or secondary hypothyroidism. Primary hypothyroidism can be further classified depending on whether it is associated with a goitre or an atrophic gland, and each of these entities can be either congenital or acquired in aetiology.

CLINICAL FEATURES

In hypothyroidism in adults, the clinical symptoms can largely be explained by a reduced metabolic rate and storage of glycosaminoglycans (GAGs) in various body compartments. Symptoms of hypothyroidism develop gradually. The term myxoedema refers to the swampy appearance of the skin and subcutaneous tissue in patients with severe hypothyroidism. In patients with secondary hypothyroidism, the peripheral manifestations of hypothyroidism are less noticeable. The skin is pale and cool, and the reduction of sweat and sebum secretion causes dryness and roughness.

The fragility of capillaries causes easy bruising. The scalp and body hair become dry and brittle and tend to fall out. GAG deposition in the pharynx and larynx contributes to hoarseness.^[1]

Allergic dermatitis

Allergic contact dermatitis (ACD) is a type 4 or delayed-type hypersensitivity (DTH) reaction by an individual's immune system to a small molecule (less than 500 daltons) or hapten that comes into contact with the skin of a sensitized individual. The initial or induction phase of ACD occurs when a hapten binds to a protein to form a complex that leads to the expansion of the allergen-specific population of T cells; the name for this process is sensitization. During the elicitation phase, re-exposure to the antigen leads to the development of dermatitis. ACD accounts for 20% of contact dermatoses and allergens vary greatly depending on geographic location, personal habits and preferences.

Allergic contact dermatitis is an inflammatory skin disease that is common in the general population. This is the most common type of occupational skin disease.

The disorder is more common in women than in men. In the elderly, the condition is often correlated with topical medications.

HOMEOPATHIC TREATMENT

Homeopathic medicines play an important role in all psychosomatic diseases as well as in autoimmune diseases. In the case of hypothyroidism, drugs have a strong effect on the hypothalamus-pituitary axis. Here the medicine acts on the sick person and changes the immune response to the desired level. This is called immunomodulation. In this way, homeopathic medicines normalize the secretion of T3, T4 and TSH and functionalize the thyroid gland at a normal level.

ROLE OF SARCODE

1. As a supplement to the constitutional remedy
2. As an organ stimulator when the affected organ is functionally or structurally impaired.
3. The disease manifests its, play" in some organs that are bound by the system, for example, a mixture of DM, hypothyroidism and PCOD in the case of endocrinological system involvement.

CASE PROFILE

A married female housewife aged 47 year old came with complaint of cracks on fingers (Hands) since 1 year.

Table 1: History of chief complaint

LOCATION	SENSATION	MODALITIES	CONCOMITANT	ASSOCIATED COMPLAINTS
Hands ↓ Fingers, Palm (Both Hands)	Intense itching++ with burning++ Itch until it bleeds	<washing detergent or soap <soil <eating brinjal >oil applying	Not specific	Fatigue Fullness of neck and body Increased weight-3 kg

PROGRESS: Initially cracks appeared on palms(fingers) when hands were exposed to detergent

/soil prior to cracks itching & burning also present when scratched bleeding occurred. The patient took allopathic (steroid)injection for same c/o, but it gave temporary relief & c/o reappeared.

Past History: For same Complaints took allopathic treatments

Family History:

Mother: Hypothyroidism with hypertension

Husband: DM

Personal History:

Appetite: Good

Desire: Spicy, Sour

Aversion: Not specific

Thirst :2/Lit /day

Thermal: Chilly

Perspiration: scanty

Sleep: Disturbed due itching

Menstrual History:

Menopause 3 years Ago

Mind/Mental Generals:

Worries about her mother, lost her brother in 2015 and grieves over against it.

Irritability increases after anything happened against her wish. +++

Anxious about children ++

Anxious about husband's health+

Industrious, wants to be busy+++

Very religious++

Brooding over small things+

Weeping disposition when emotional++

Physical Examination:

Built-Average
 Height-5’2”
 Weight-64 kg
 BP-130/90MMHG
 Pulse:72/ Min regular
 Tongue-Yellow coated

Systemic examination:

Investigation:

Thyroid profile: Sr.TSH:15.57µIU/ml

RS: A E B E

CVS: S1 & S2 Normal

CNS: Conscious & oriented

GIT: Soft & Non-tender

Local examination of Skin:

O/E Inspection: Look of skin: Dry, Rough
 Cracks at finger and palm
 Fingers-yellow crust
 No scaling, no plaques, no discharge

Final Diagnosis: Allergic dermatitis with Hypothyroidism

Remedy Name	Sep	Calc	Sulph	Ign	Aur	Lyc	Puls	Lach
Totally	20	17	17	15	15	14	14	13
Symptoms Covered	9	7	6	7	6	6	6	7
Kingdom								
[Kent] [Mind]Anger,irascibility (see irritability,quarrelsome):Contradiction,...	3			3	3	3		
[Kent] [Mind]Industrious: (38)	2	1		2	3			2
[Kent] [Mind]Religious affections (see anxiety,despair,fear: (53)	2	2	3	2	2	2	2	3
[Kent] [Mind]Weeping,tearful mood,etc.: (166)	3	3	3	3	2	3	3	1
[Kent] [Mind]Anxiety: (202)	2	3	3	2	3	3	3	2
[Kent] [Stomach]Desires:Pungent things: (9)								
[Kent] [Stomach]Desires:Sour,acids,etc.: (77)	2	2	2	2			2	2
[Kent] [Perspiration]Scanty sweat: (25)	1			1				1
[Kent] [Skin]Cracks:Itching: (2)								
[Kent] [Skin]Cracks:Washing,after: (15)	3	3	3			1	2	
[Kent] [Skin]Cracks:Burning: (3)								
[Kent] [Extremities]Cracks:Hands (see chapping): (41)	2	3	3		2	2	2	2

Figure 1: Repertorisation [2]

TOTALITY OF CASE:

1. Irritability increases after anything happened against her wish+++
2. Anxious about children ++
3. Industrious, wants to be busy+++
4. Very religious++
5. Weeping disposition when emotional++
6. Desire for sour things+++ , spicy food++
7. Perspiration scanty++
8. Sleep disturbed+
9. Cracks on fingers, hands, palm++
10. Itching++ with burning++
11. <washing with detergent or soap
12. <eating brinjal
13. <soil, >oil applying

PROBABLE MEDICINE^[3-4]:

Sepia
 Calcarea Carb
 Sulphur
 Ignatia

FINAL MEDICINE: Sepia

Prescription:**Rx**

Sepia 1 M Single dose stat
 Thyroidinum 6X 2BD X 1 month

Table 2: Follow up Date wise description of medicine

DATE	COMPLAINTS	PRESCRIPTION
12/10/2019	Itching, burning reduced Cracks are healing <washing with detergent <soil >applying oil Generally, patient feel better	Saclac BD X 1 month Thyroidinum 6X 2 BD X 1 month
13/11/2019	Cracks are healing No itching, No burning Generally, patient feel better No any new complaint Patient feels fresh	Sac lac BD X 1 Month Thyroidinum 6x 2 BD X 1 Month
13/12/2019	Cracks are healing No itching no burning Generals are better	Sepia 1 M SD stat Thyroidinum 6x 2BD X 1 month
14/01/2020	No any new complaints No cracks, Pt.is improved Generals are Improved Investigation: Serum TSH-5.33 μ IU/ml	Saclac BD X 1 month Thyroidinum 6x BD X 1 Month
15/02/2020	No, any new complaint Pt feel fresh	Sac lac stat dose Thyroidnum 6x OD X 1 month
16/03/2020	No new complaint Patient is improved	Saclac BD X 1 month

DISCUSSION

Instead of only constitutional homoeopathic medicine we tried the role of sarcodes as an adjuvant or complementary to see if it hastens the process of cure. Homoeopathic Medicines improve immunity, thus rectifying the hypersensitive reaction to allergens.

Medicinal substances used in homeopathy come from mineral, plant and animal sources and are used on the principle of like cures like. When a person is treated as a whole, the symptoms occurring in different parts of their body will naturally be cured because their overall health has been addressed, that is, all their mental, emotional and physical symptoms have been taken into account and treated by the homeopath. Sarcodes are one of the most curing agent in our system of medicine. we can use as catalyst or an adjuvant for process of cure.

Sarcodes are homeopathic drugs that are prepared from the secretions and tissues of healthy animals. They contain biological molecules that have physiological functions in humans. The codes contain information about an organ's biological structure and its energy-producing substance. They are used to remove toxins and improve organ function. Sarcodes are extracted from animal or human tissues and used to treat various conditions. They are also known as cellular homoeopathy. The use of sarcodes helps transfer genetic information from the nucleus to the cytoplasm of cells. It serves as a template for the synthesis of protein.

An evidence case report has been mentioned earlier. The case presented with hypothyroidism with the evidence of the TSH report points to an excellent illustration of how you can effectively treat yourself with homeopathy without any external supplements. The patient used thyroxine tablets regularly for 1 year and after 1 year she stopped the hormone supplementation herself. Despite the intake of supplements, the patient had elevated TSH levels. Natrum Muraticum 200 was selected based on the

summary of the individual's symptoms after a proper and detailed collection of case reports. With the 1st dose of the drug, the TSH levels tend to decrease and then with subsequent doses, the hormonal balance stabilizes in a short time. Subsequently, her thyroid swelling decreased, her periods became regular, her anxiety decreased, and her acne and hair loss improved. The case was followed for 1 year to ensure the stability of the patient's overall improvement.^[5]

The goal of homeopathic treatment is to stimulate the body's hemostatic mechanism. In the following situations

To achieve this, we need to give the right similimum at the right time. So homeopathy should be the first choice for hypothyroidism as it works quickly and effectively and treats the disease from its roots

CONCLUSION

This case report of allergic dermatitis with hypothyroidism shows that with the help of constitutional medicines along with sarcodes, we can treat the patient in a very gentle way and constitutional medicine & sarcodes as booster, shows great results, Proper medicine selection not only improve the health care but also improves the quality of life in patient.

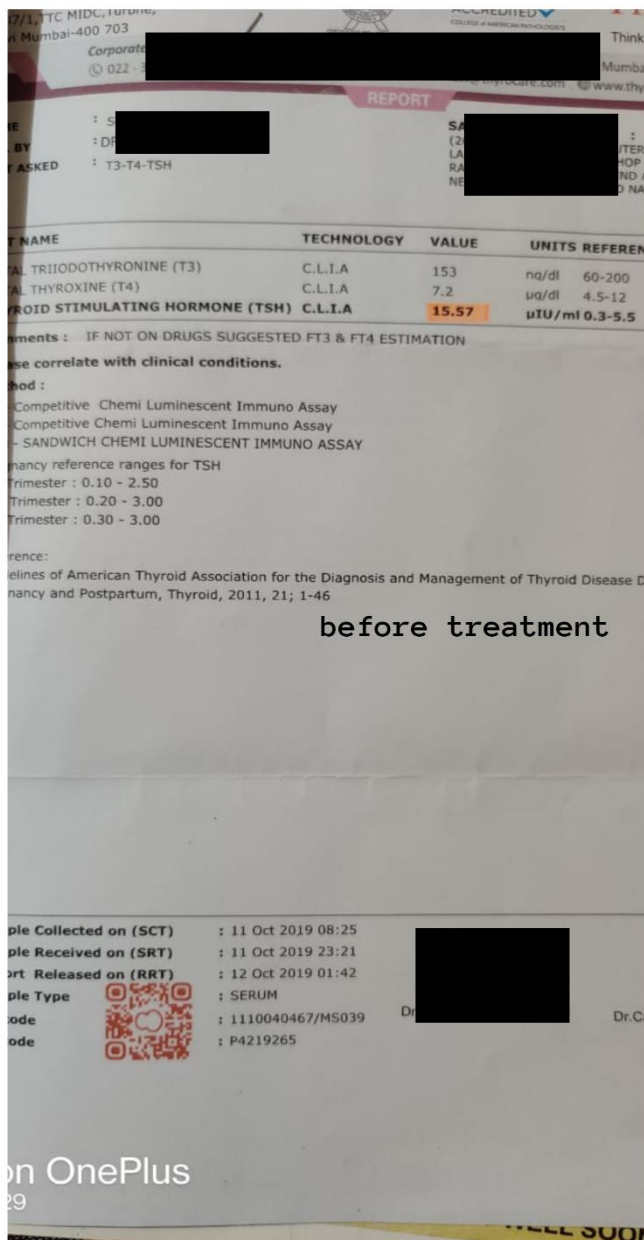


Figure 2: Thyroid profile - Before treatment

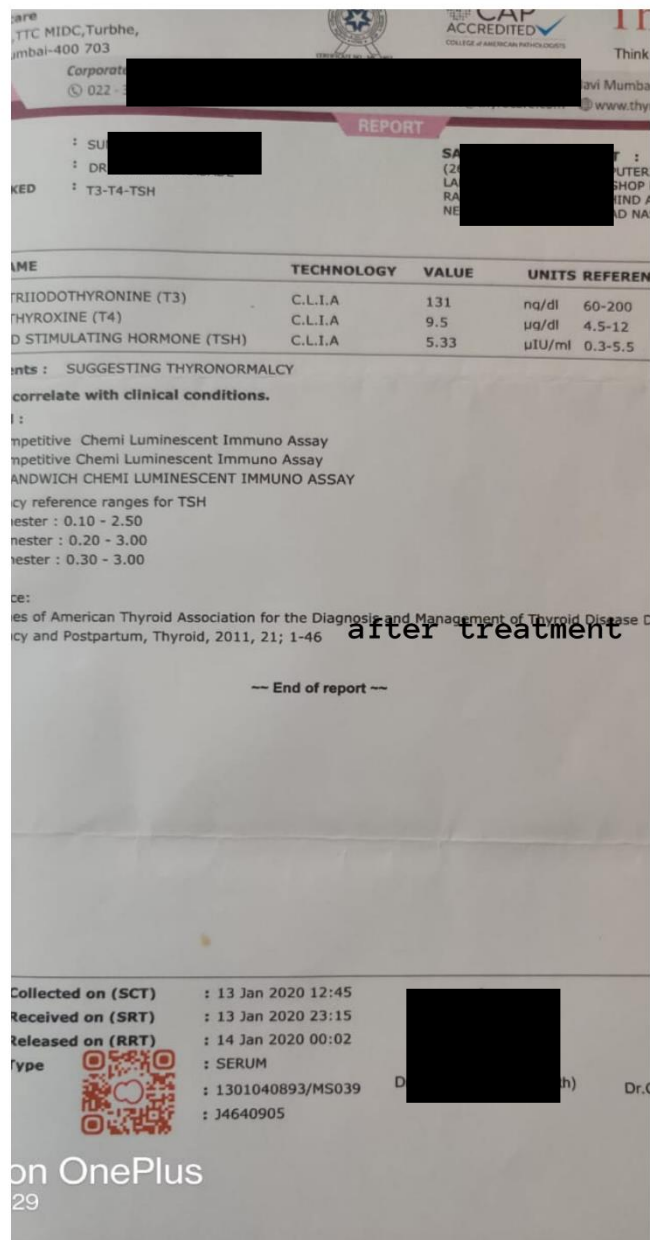


Figure 3: Thyroid profile - After treatment

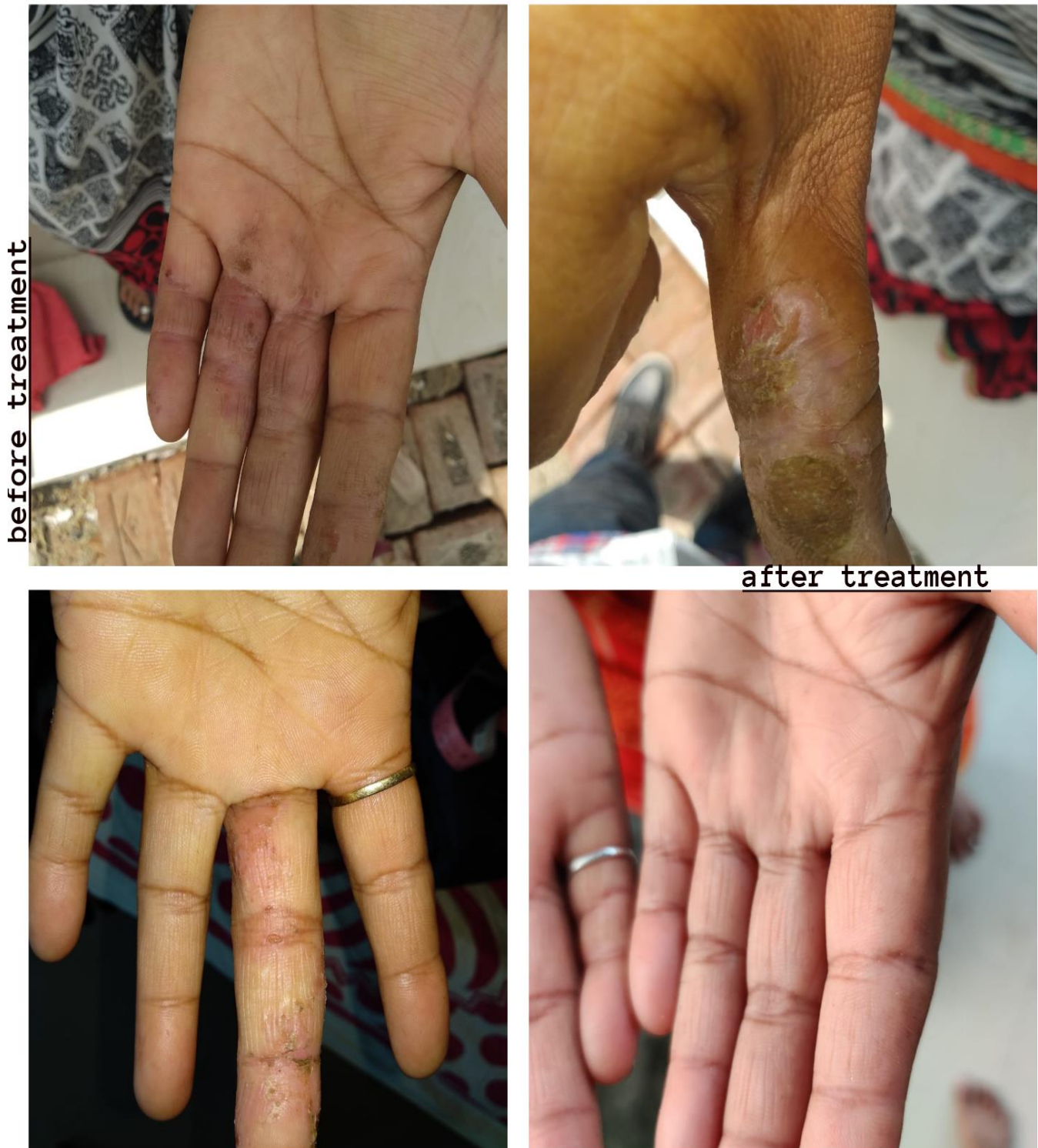

Figure 4: Before & After treatment photographs

REFERENCES

1. Dr. Siddharth N. Shah, API Textbook of Medicine. 9th edition. Mumbai; 2012 p.425
2. Homeopathic software: Zomeo (Kent Repertory)
3. Boericke W. New Manual of Homeopathic Materia Medica & Repertory. New Delhi, India: B. Jain; 2007.p.568-569
4. Kent J. Lecture on Homoeopathic Materia Medica. Reprint. New Delhi: Mayur Jain, Indian books and Periodical syndicate; 2015.p.863-873
5. Moorthi S, Manoharan R, Kumaravel . HOMOEOPATHIC TREATMENT OF HYPOTHYROIDISM: A CASE REPORT. WORLD JOURNAL OF PHARMACEUTICAL AND MEDICAL RESEARCH Available from https://www.researchgate.net/publication/343207142_HOMOEOPATHIC_TREATMENT_OF_HYPOTHYROIDISM_A_CASE_REPORT [Last accessed on 2023 Dec 20].