

KNOW Homoeopathy Journal

Bi-Annual, Indexed, Double-Blind, Peer-Reviewed, Research Scholarly, Online Journal in Field of Homoeopathy

KNOW Homoeopathy Journal Vol-4 & Issue-1, 15 March 2024, Published at <https://www.knowhomoeopathyjournal.com/2024/03/volume-4-issue-1.html>, Pages: 66-72, Title: A case report: Endometrial polyp treated by homoeopathy, Authored By: Dr Ajay Vishwakarma (BHMS, MD (Hom), PhD (Hom), Principal I/C, (Professor/HOD, Department of Anatomy, Chandola Homoeopathic Medical College and Hospital, Rudrapur , U S Nagar, Uttarakhand) Dean (Homoeopathy) Uttarakhand Ayurved University Dehradun, Uttarakhand.) & Co-Authored By: Dr. Nitin Kumar (BHMS, M.Sc (Entomology), Professor/HOD, Department of Materia Medica, Chandola Homoeopathic Medical College and Hospital, Rudrapur, U S Nagar, Uttarakhand.), Dr Pallavi Bhaskar (BHMS, MD (Hom.), Assistant Professor, Department of Anatomy, Chandola Homoeopathic Medical College and Hospital, Rudrapur , U S Nagar, Uttarakhand) & Dr. Ambica Tomar (Chandola Homoeopathic Medical College and Hospital, Rudrapur, U S Nagar, Uttarakhand.)



VOLUME-4 ISSUE-1
MARCH 2024

CASE-REPORT

Title: A case report: Endometrial polyp treated by homoeopathy

Authored By: Dr. Ajay Vishwakarma^[1] & Co-Authored By: Dr. Nitin Kumar^[2], Dr. Pallavi Bhaskar^[3], Dr. Ambica Tomar^[4]

^[1] BHMS, MD (Hom), PhD (Hom), Principal I/C, (Professor/HOD, Department of Anatomy, Chandola Homoeopathic Medical College and Hospital, Rudrapur , U S Nagar, Uttarakhand)

Dean (Homoeopathy) Uttarakhand Ayurved University Dehradun, Uttarakhand.

^[2] BHMS, M.Sc (Entomology), Professor/HOD, Department of Materia Medica, Chandola Homoeopathic Medical College and Hospital, Rudrapur, U S Nagar, Uttarakhand.

^[3] BHMS, MD (Hom.), Assistant Professor, Department of Anatomy, Chandola Homoeopathic Medical College and Hospital, Rudrapur , U S Nagar, Uttarakhand).

^[4] Chandola Homoeopathic Medical College and Hospital, Rudrapur, U S Nagar, Uttarakhand.

ABSTRACT

The case of 32 years old female having endometrial polyp treated with individualised homoeopathic medicine. When the patient came for the consultation, she was presented with profuse menstruation with associated white discharge per vagina after menstruation and having haemorrhoids. The case was repertorised after case taking and making the totality of symptoms from the characteristic symptoms of the patient using synthesis repertory to select the simillimum of the case, in which we got few homoeopathic remedies including Thuja, Belladonna, Mercurius, Phosphorus, Sepia and others.

Keywords: *Endometrial Polyp, Homoeopathy, Thuja*

How to cite this case report:

Vishwakarma A, Kumar N, Bhaskar P, Tomar A. A case report: Endometrial polyp treated by homoeopathy, KNOW Homoeopathy Journal, 2024; 4(1):66-72, available at <https://www.knowhomoeopathyjournal.com/2024/03/Case-report-of-endometrial-polyp-treated-by-homoeopathy.html>

© 2024 KNOW Homoeopathy Journal

[Know more about Journal's Copyright Policy](https://www.knowhomoeopathyjournal.com/p/copyright-policy.html)

<https://www.knowhomoeopathyjournal.com/p/copyright-policy.html>



Scan-Quick Response Code

INTRODUCTION

Overgrowths of endometrial glands and stroma inside the uterus are called endometrial polyps. The diameter of endometrial polyps ranges from a few millimetres to several centimetres. Polyps might be one lesion or many lesions that cover the whole uterine cavity. Although endometrial polyps can be identified at any age, between the ages of 40 and 49 is when they are most common. There is a little chance that these polyps might turn cancerous, even though they are thought to be benign.^[1]

CASE STUDY

A 32 year old female having profuse menstruation with early menstrual cycle associated with white discharge per vagina after menses which has greenish colour. She also has haemorrhoids which aggravates on sitting. Mentally she was very irritated and quarrelsome.

PRESENT COMPLAINTS

- Profuse bleeding per vagina since 3-4 days
- Character of bleeding is bright red
- Aggravation all the time and motion
- Amelioration by medication
- White discharge per vagina since 3-4 months
- Character of discharge is greenish Offensive
- Haemorrhoids since 4-5 years
- Character: Swollen
- Aggravation while sitting

PHYSICAL GENERALS

• Appetite of the patient is adequate with desire of cold things and aversion to potatoes. Stools are unsatisfactory with irregular bowel movements. Perspiration is more on the uncovered parts which stains the closed yellow.

MENTAL GENERALS

- Irritability³⁺
- Music cause weeping³⁺
- Dreams of falling³⁺
- Quarrelsome²⁺
- Anger suppressive²⁺

MENSTRUAL HISTORY

- **Menarche:** 14 yrs. of age
- **L.M.P.:** 8/12/2021
- **Cycle:** 20 days
- **Duration:** 4-5 days
- **Character:** Bright red colour, slight clots present
- **Flow:** Profuse
- **Associated complains:**
White discharge – Yellow in colour with offensiveness

OBSTETRICS HISTORY

- G3 P2 A1 L2
- Has two children boy of 11yrs old and girl of 6yrs old
- Aborted one child of 6 weeks

Table 1: Analysis and Evaluation of Symptoms

Symptoms	Physical Generals	Mental Generals	Particulars
1	Desire for cold things ²⁺	Irritability ³⁺	Profuse menses ²⁺
2	Aversion to potatoes ²⁺	Quarrelsome ²⁺	Menses too early ²⁺
3	Perspiration on uncovered parts ³⁺	Music causes weeping ³⁺	Haemorrhoids: swollen Agg on sitting ³⁺
4	Perspiration stains yellow ³⁺	Dreams of falling ³⁺	Leucorrhoea: greenish, offensive ³⁺
5			Uterine Polyp ³⁺

[Note: +1, +2 are +3 are intensity of the symptoms]

TOTALITY OF SYMPTOMS

- Profuse menstruation of bright red colour
- Menstrual cycle too early
- White discharge per vagina of greenish colour
- Haemorrhoids of swollen character agg. by sitting
- Uterine polyp
- Desire for cold things
- Aversion to potatoes
- Perspiration on uncovered parts
- Perspiration stains the cloths yellow
- Dreams of falling
- Music causes weeping
- Irritability
- Quarrelsome

PROVISIONAL DIAGNOSIS

Endometrial Polyp²

RUBRIC SELECTED³

- Dreams-Falling

- Mind-Irritability
- Mind-Weeping-music, from
- Rectum-Haemorrhoids-sitting-agg.
- Perspiration-Uncovered parts, on
- Perspiration-Staining the linen yellow
- Female Genitalia/Sex-Menses-copious
- Female Genitalia/Sex-Menses-frequent;too
- Female Genitalia/Sex-Menses -Polyps-uterus
- Female Genitalia/Sex-Menses-Leukorrhea-greenish

ANALYSIS OF THE CASE

After the case taking and evaluation of the case characteristic symptoms used in constructing the totality of the symptoms “Dreams of falling, irritability, music cause weeping” were important mental symptoms in the case. “Perspiration over uncovered parts and perspiration stains the linen yellow” were important physical generals. “Haemorrhoids swollen, aggravation on sitting, menses copious and too early,

leukorrhoeal discharge of greenish colour and uterine polyp” were important particulars symptoms in the case.

The remedy selection was done based on repertorisation by Radar Software version 10.0 using Synthesis treasure edition ,2009 by Frederick Schroyens.^[3] The repertorization chart is shown in the figure. Where the top five remedies were Thuja (21/10), Belladonna (17/7), Mercurius (15/7), Phosphorus (15/7), Pulsatilla (13/7).

On the basis of repertorial analysis and with consultation of Boericke’s Materia Medica^[4], Thuja was selected as first prescription as it

scored highest in the repertorial result as perspiration staining yellow, dreams of falling, haemorrhoids of swollen character and aggravation on sitting was marked in the patient and according to appearance she was also having warty growth on her body and there is tendency of overgrowth in general. So, Thuja was selected in comparison to Belladonna and Mercurius.

After prescribing two dose per day for three days of Thuja 200, the profuse menses were reduced to normal flow, slight relief in leucorrhoea, relief in haemorrhoids and drastic relief in endometrial polyp.

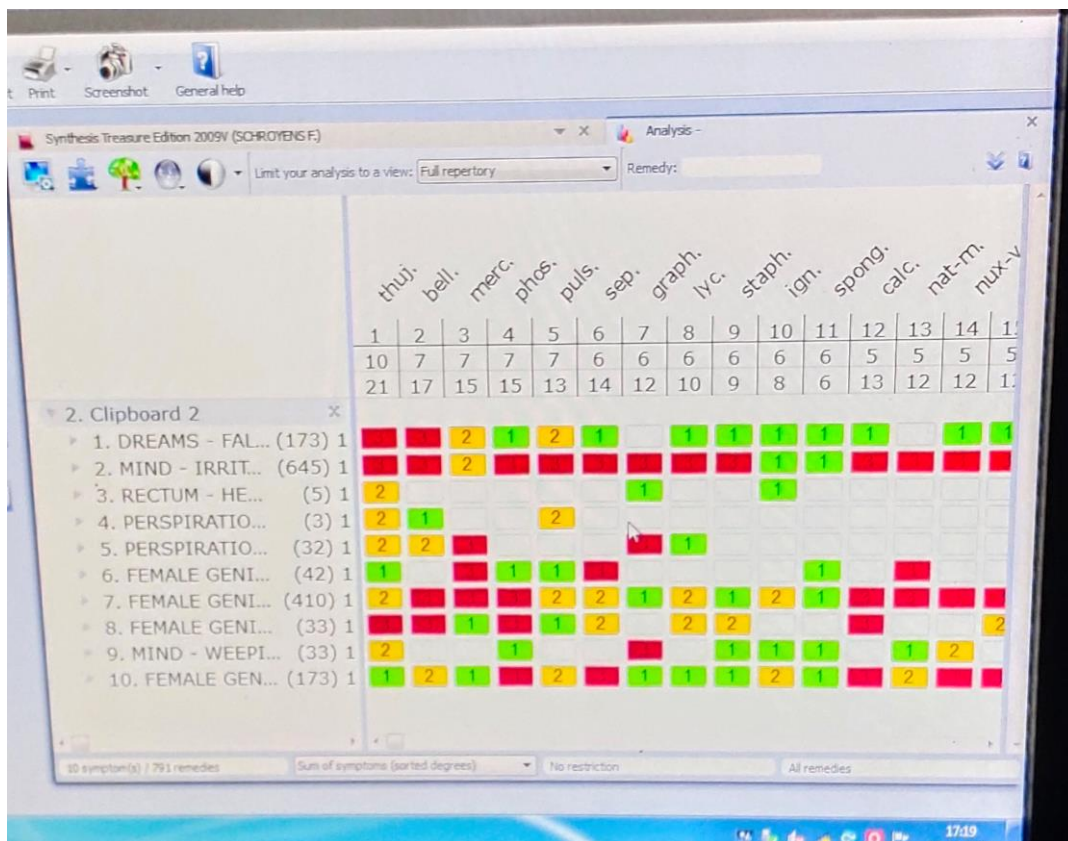

Fig 1. Repertorial Analysis³

PRESCRIPTION

*Thuja*⁴ 200/6 doses

INVESTIGATIONS

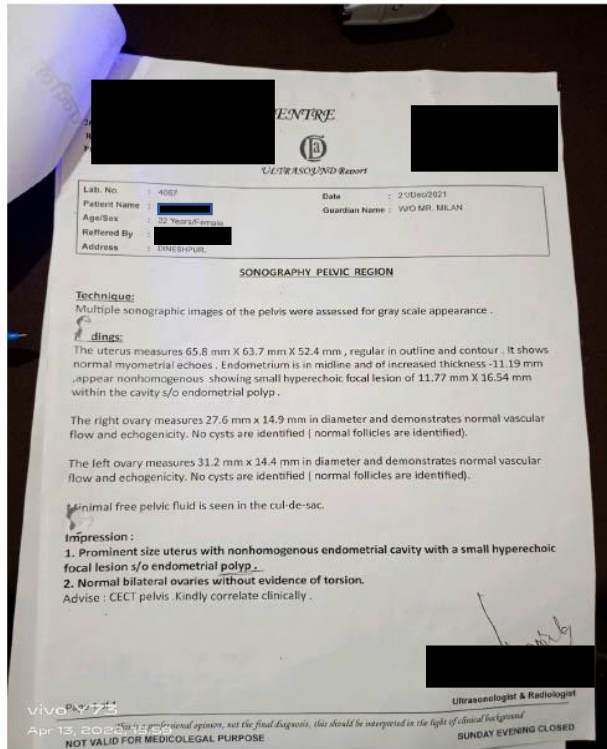


Figure 2: USG Report before treatment

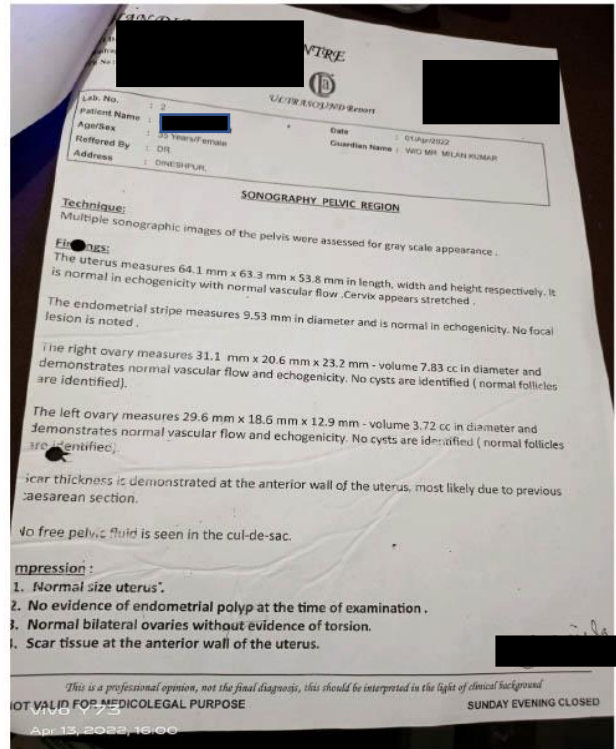


Figure 3: USG Report after treatment

Table 2: Follow up Date wise description of medicine

DATE	SYMPTOMS	MEDICINE PRESCRIBED
22/12/2021	1 st visit of the patient	Thuja 200/6 dose (“The dose of medicine (of the first prescription) that acts without producing new troublesome symptoms in to be continued while gradually ascending, so long as the patient with general improvement, begins to feel in the mild degree the return to of one or several old original complaints”). (Aph 248,280) ⁵
31/12/2021	Slight relief in bleeding	Phytum 200/7 days
15/01/2022	Slight relief in white discharge	Phytum 200/7 days

31/01/2022	Slight relief in haemorrhoids	Phytum 200/7 days
16/02/2022	Profuse menses relieved	Thuja 200/ 6 dose (According to Kent's 11 th observation reappearance of older symptoms and the improvement is standstill then the repetition of the remedy should be prescribed) ⁶
05/03/2022	White discharge relieved	Phytum 30/7 days
01/04/2022	Haemorrhoids relieved with no new complain	Placebo 30/15 days

DISCUSSION AND CONCLUSION

Homeopathic treatment chosen according to homeopathic principles proved highly effective in addressing this instance of Endometrial Polyp, yielding remarkable outcomes during the course of treatment. Thuja was specifically chosen based on physical and mental characteristics, as well as individual particulars, in alignment with the principles of homeopathic philosophy and materia medica. The treatment spanned a period of 5 months, with minimal doses of medicine administered, demonstrating notable efficacy in managing the condition.

In a research investigation, a 27-year-old female experienced intense menstrual and intermenstrual bleeding, coupled with severe abdominal pain during her menstruation period. Upon thorough examination, the diagnosis revealed a significant endometrial polyp. Responding to the symptoms presented, the patient underwent a series of homeopathic treatments. Over time, a notable outcome was observed as the polyp completely vanished following a substantial duration of treatment. The objective of this case report is to highlight the improved prognosis of uterine polyps through homeopathic intervention.^[7]

USG reports of the case presented with non-homogeneous endometrial cavity having small lesion in the endometrium previously before the treatment started which has been disappeared in the course time due to effect of homeopathic intervention given after

thorough case taking and repertorization. Thuja is the remedy selected as the simillimum. The treatment was continued for 5 months with thuja⁴ repeated only twice in the whole treatment.

REFERENCES

1. Mansour T, Chowdhury YS. Endometrial Polyp. [Updated 2023 Apr 25]. In: StatPearls [Internet]. Treasure Island (FL): StatPearls Publishing; 2023 Jan-. [Accessed on 22 June 2023] Available from: <https://www.ncbi.nlm.nih.gov/books/NBK557824/>
2. World Health Organisation (WHO), icd10data.com, 2022 ICD-10 -CM Diagnosis code [Internet], Geneva, Switzerland, World Health Organisation 1993; <https://www.icd10data.com/ICD10CM/Codes/N00-N99/N80-N98/N84-N84.0> [Accessed on 24 June 2023].
3. Schroyens F. Synthesis 9.1: English. 1st ed. Cambridge, UK: RSC Publishing; 2023.
4. Boericke W. Pocket Manual of Homoeopathic Materia Medica. 9th ed. New Delhi: IBPP; 2007 .p. 643-645.
5. Hahnemann S. Organon of Medicine. 6th ed. New Delhi: B Jain Publishers; 2002. p. 227-8

6. Kent J T. Lectures on Homoeopathic Philosophy. Archive.org [Internet]. [Cited on 22 April 2023] Chicago. Ehrhart & Karl, 1919 available from <https://archive.org/details/lecturesonhomoe00kentgoog>

7. Dutta A, Singh S. Homoeopathic treatment of large endometrial polyp: A case report. Homoeopath Links [Internet]. 2019 [Cited 2023 April 22]; 32(01):023–6. Available from: <http://dx.doi.org/10.1055/s-0039-1687896>