

# KNOW Homoeopathy Journal

Bi-Annual, Indexed, Double-Blind, Peer-Reviewed, Research Scholarly, Online Journal in Field of Homoeopathy

KNOW Homoeopathy Journal Vol-3 & Issue-2, 18 October 2023, Published at <https://www.knowhomoeopathyjournal.com/2023/10/volume-3-issue-2.html>, Pages: 54-60, Title: Treatment of genital warts (Condyloma acuminatum) with homoeopathy – Evidence based case report, Authored By: Dr. Ajay Kumar (M.D (Hom.), Assistant Professor Department of Pathology & Microbiology, Swasthya Kalyan Homoeopathic Medical College & Research Centre, Jaipur, Rajasthan, India.) & Co-Authored By: Dr. Ravindra Kumar Kumawat (M.D (Hom.), Associate professor (Department of Repertory), Dr. M.P.K. Homoeopathic Medical college, Hospital & Research Centre, Jaipur, Rajasthan, India. (A constituent college of Homoeopathy University, Jaipur.)



VOLUME-3 ISSUE-2  
OCTOBER 2023

## CASE-REPORT

### Title: Treatment of genital warts (Condyloma acuminatum) with homoeopathy – Evidence based case report

Authored By: Dr. Ajay Kumar <sup>[1]</sup> & Co-Authored By: Dr. Ravindra Kumar Kumawat <sup>[2]</sup>

<sup>[1]</sup> M.D (Hom.), Assistant Professor Department of Pathology & Microbiology-Swasthya Kalyan Homoeopathic Medical College & Research Centre, Jaipur, Rajasthan, India.

<sup>[2]</sup> M.D (Hom.), Associate professor (Department of Repertory), Dr. M.P.K. Homoeopathic Medical college, Hospital & Research Centre, Jaipur, Rajasthan, India. (A constituent college of Homoeopathy University, Jaipur.)

## ABSTRACT

Condyloma Acuminatum also known as genital warts is the most common sexually transmitted disease which constitutes a considerable burden to the health care system and individual patients worldwide. The aim of this case study is to again prove a fact that homoeopathy does miracles in incurable pathology. Homoeopathy treats the person as a whole so well selected medicine based on the totality of symptoms including the patient as a person and, the physical general, and mental make-up of the patient, can cure any kind of genital warts.

**Keywords:** *Condyloma Acuminatum, Genital warts, Homoeopathy, Sexually transmitted disease, Totality of symptoms*

Received: 08/07/2023

Accepted: 07/10/2023

Published: 18/10/2023

**How to cite this article:**

Kumar A, Kumawat R. Treatment of genital warts (Condyloma acuminatum) with homoeopathy – Evidence based case report, KNOW Homoeopathy Journal, 2023; 3(2):54-60, available at <https://www.knowhomoeopathyjournal.com/2023/10/treatment-of-genital-warts-with-homoeopathy.html>

© 2023 KNOW Homoeopathy Journal

[Know more about Journal's Copyright Policy](https://www.knowhomoeopathyjournal.com/p/copyright-policy.html)<https://www.knowhomoeopathyjournal.com/p/copyright-policy.html>**INTRODUCTION**

Condyloma Acuminatum is fleshy papillomatous growth mostly present on the glans and shaft of the penis. Genital warts may be found single and multiple presents as soft, fleshy, sessile or pedunculated, initially small they may enlarge to form cauliflower-like tumors. Mostly lesion lined by hyperplastic squamous epithelium that shows koilocytosis. The causative organism of Condyloma Acuminatum is the Human papillomavirus (HPV). The most common strains of HPV are 6 and 11. Genital warts are symptoms of HPV infection. HPV is a common sexually transmitted infection worldwide with 9 to 13 % of the global population infected.<sup>[1]</sup> Overall prevalence in India was estimated at 1.07% and was higher for men than women.<sup>[2]</sup>

The previous study 'Evidence Based Homoeopathy In Treating Condyloma Acuminatum – A Prospective And Interventional Study' concludes "Homoeopathic medicinal treatment searches the fundamental causes of the disease process and selects a single similimum after proper case study, tracing the totality of symptoms and individualizing the case as well as the patient. By the alternative method of treatment, condyloma acuminatum may disappear permanently".<sup>[3]</sup>

**CASE REPORT****NAME:** XXXX**AGE:** 30 years**SEX:** Male**DATE:** 21/05/2022**PRESENT COMPLAINTS**

The patient having warty growth on the foreskin (prepuce) of the penis since 4 years. Large, cauliflower-like warts. Violent itching on the penile area at night. Foreskin dry, cracked but no pain. Painful coitus.

**PAST HISTORY:** NAD**FAMILY HISTORY:** NAD**PHYSICAL GENERALS:****Appetite:** Good appetite; 3 times in a day**Desires:** Spicy food, raw onion but it causes stomach pain and acidity.**Aversions:** Not specific**Thermal:** Towards chilly**Thirst:** Thirsty ++**Stool:** Stool twice in a day. The stool is normal in color and consistency.**Urine:** NAD**Sweat:** Not specific**Sleep/Dreams:** Sound sleep at night.**Body Make-up:** Lean, thin, tall, dark-skinned.

**MENTAL GENERALS:** Weak memory, forgetful nature, wants words while talking, weak-willed, sad all the time, depressed about life. Rigid in nature, fixed ideas. Brooding tendency, thoughts continue to run in mind.

**DIAGNOSIS:** Genital warts

Violent itching on penile area < night.  
Foreskin dry, cracked  
Painful coitus

**ANALYSIS OF CASE**

**Mental Generals:**

Sadness+++  
Rigid nature++  
Forgetful & weak memory

**REPORTORIAL TOTALITY WITH REPERTORIZATION**

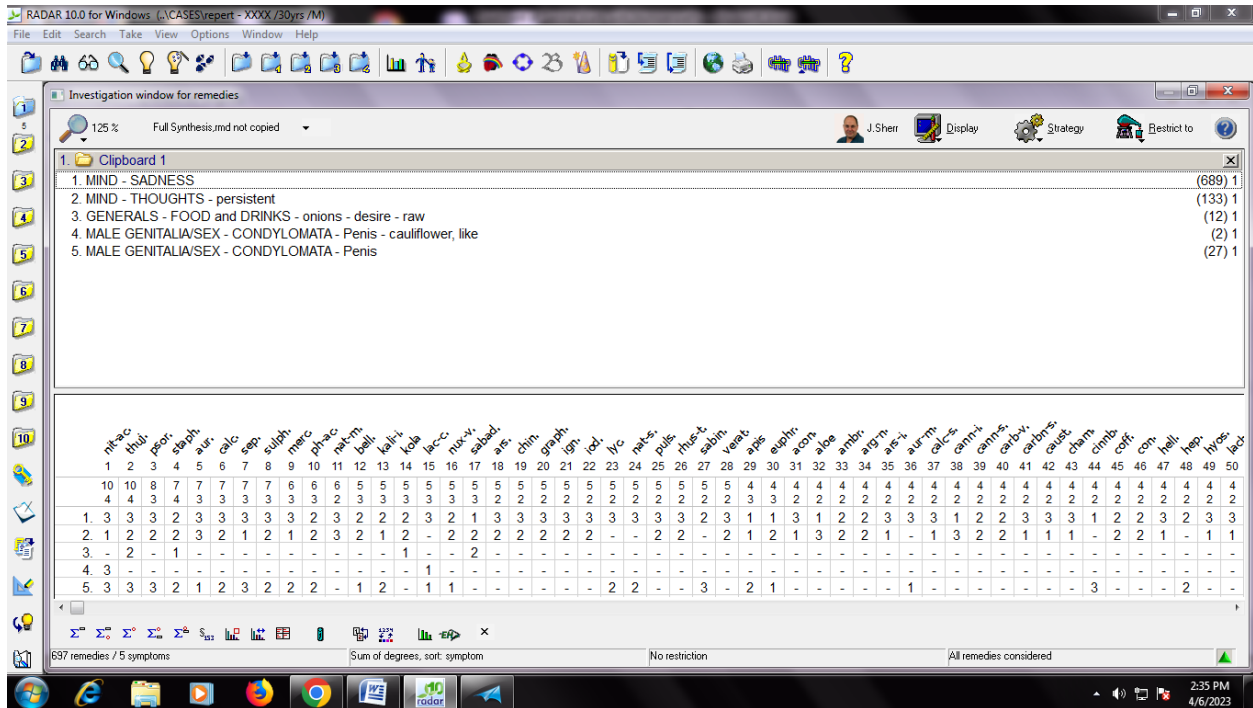
Mind – Sadness  
Mind – Thoughts – Persistent  
Generals – Food & Drinks – Onion – Desire - Raw  
Male Genitalia/sex – Condylomata – penis – cauliflower-like  
Male Genitalia/sex – Condylomata – penis

**Physical Generals:**

Desire for raw onions +++  
Chilly ++  
Thirsty ++

**Characteristic Particulars:**

Warts on penis  
Cauliflower like warts



Repertorization- Figure 1

**PRESCRIPTION: 15/04/2022**

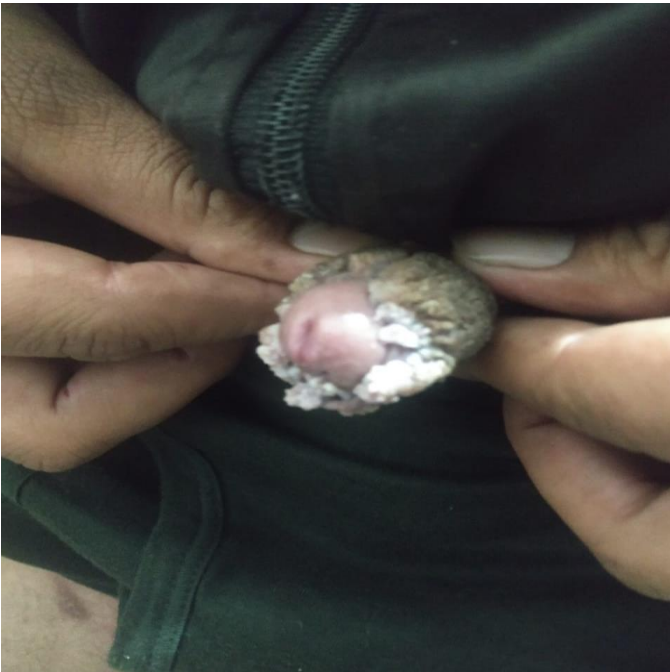Acid Nitricum 30/ 3 doses/ OD/ Empty Stomach/ for 3 days  
Rubrum 30 / BD for 7 days

DATE	SYMPTOMS	PRESCRIPTION
30/05/22	Warts as such, Pain > , itching >, cracks >	Rubrum 30 / BD for 14 days
15/06/22	Warty growth >, No pain, no itching, cracks absent.	Rubrum 30 / BD for 14 days
29/06/22	Warty growth >, No pain, no itching, cracks absent.	Rubrum 30 / BD for 14 days
10/07/22	Warts as such, itching and cracks since 7 days, foul smell from discharge. Itching <<	Thuja 200/ 3 doses/OD/ES/ for 3 days
14/07/22	Warts >>, No pain, no itching, cracks absent.	Rubrum 30 / BD for 14 days
29/07/22	Warts >>, No pain, no itching, no cracks	Rubrum 30 / BD for 14 days
15/08/22	Warts >>, No pain, no itching, no cracks	Rubrum 30 / BD for 14 days
30/08/22	Warts >>>, No pain, no itching, no cracks, no pain during sex	Rubrum 30 / BD for 14 days
20/09/22	No warts, No pain, no itching, no cracks	Rubrum 30 / OD for 30 days
22/10/22	The patient is all alright.	Rubrum 30 / OD for 30 days

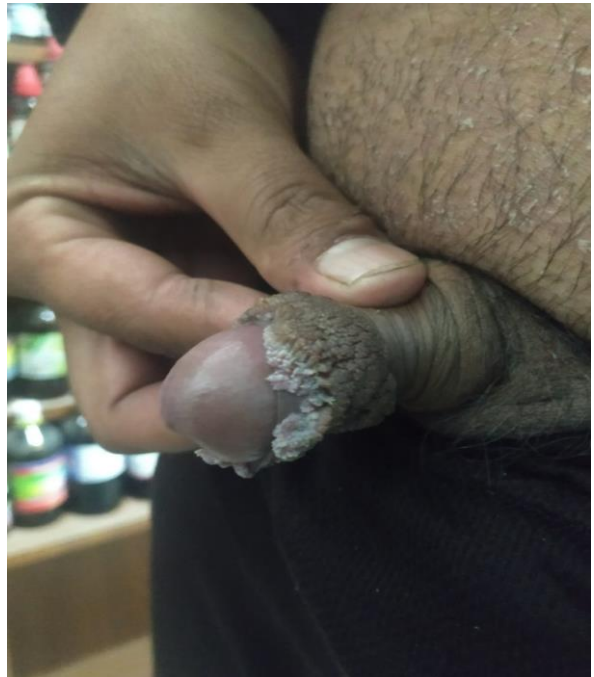
*Table-1 Follow-ups***Abbreviations: <, >, OD, BD, ES**

ABBREVIATIONS	DEFINITIONS
<	Aggravation
>	Amelioration
OD	Once in a day
BD	Twice in a day
ES	Empty Stomach

**BEFORE TREATMENT**

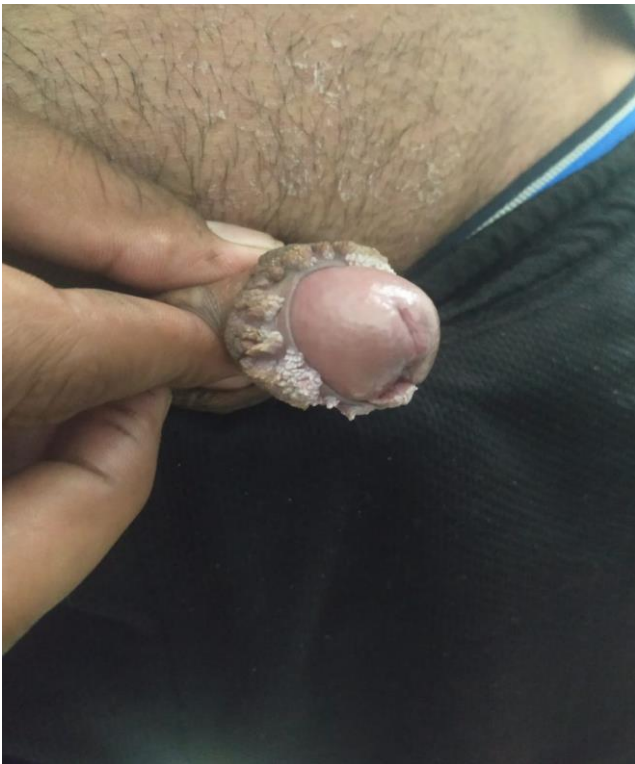

**Figure 2 (A)**

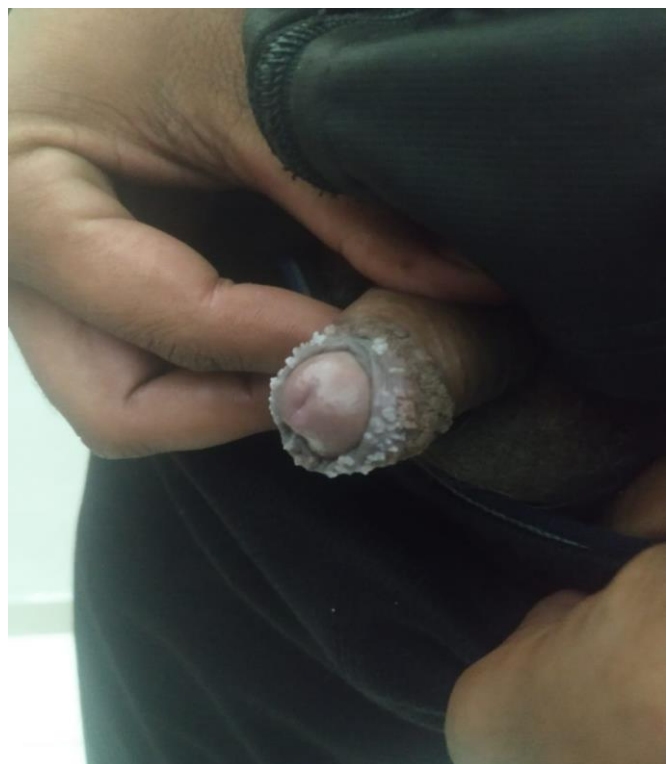

**Figure 2 (B)**

**DURING TREATMENT**



**Figure 3 (A)**



**Figure 3 (B)**



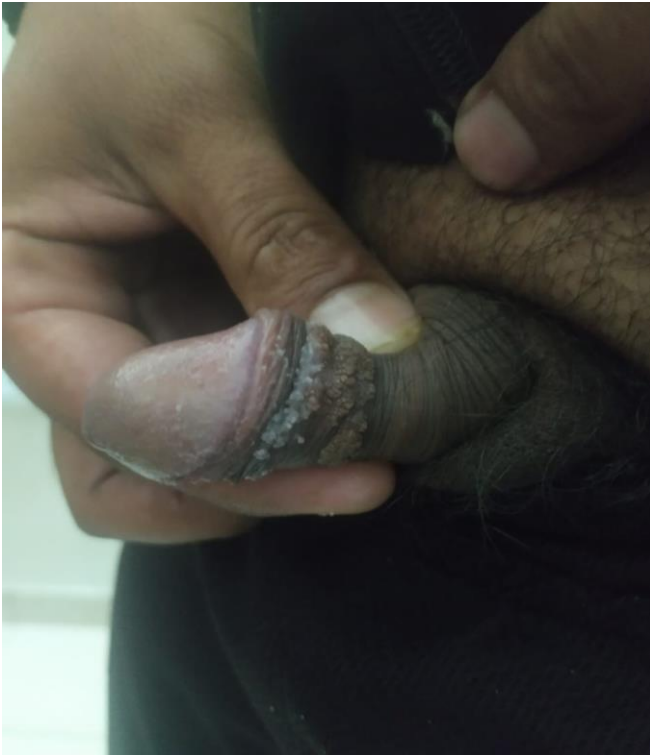

Figure 3 (C)

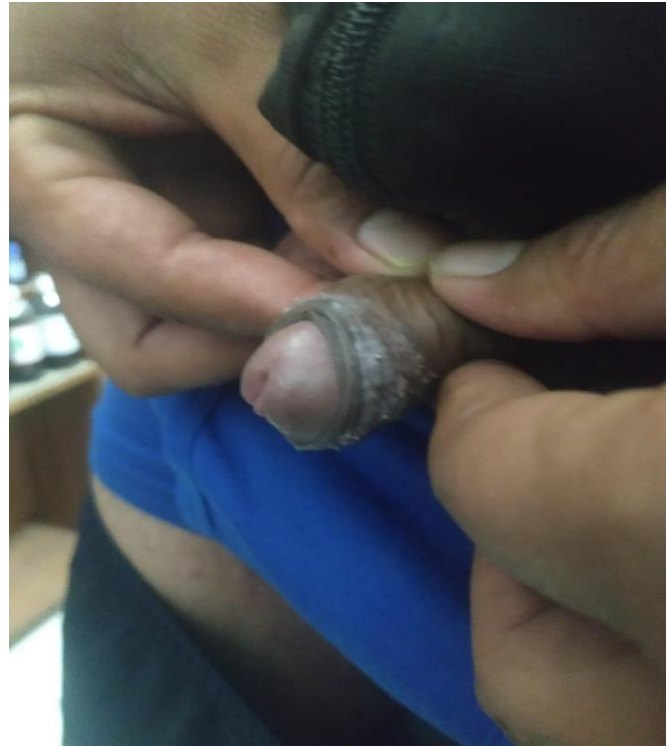

Figure 3 (D)

**AFTER TREATMENT**

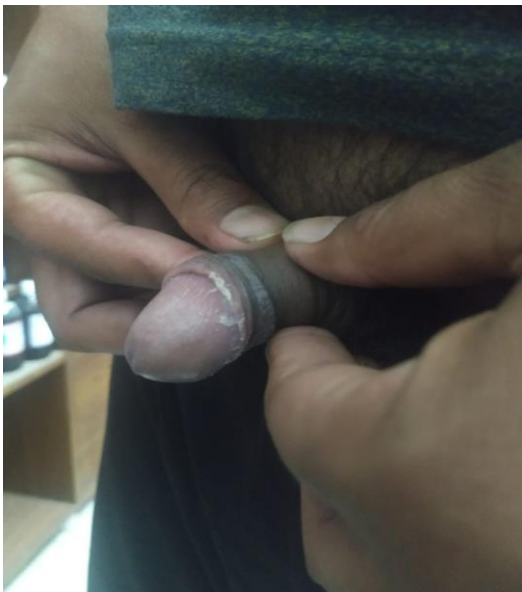

Figure 4 (A)

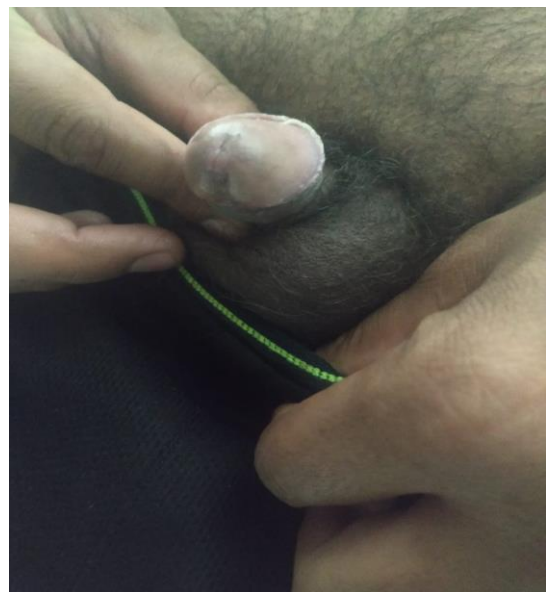
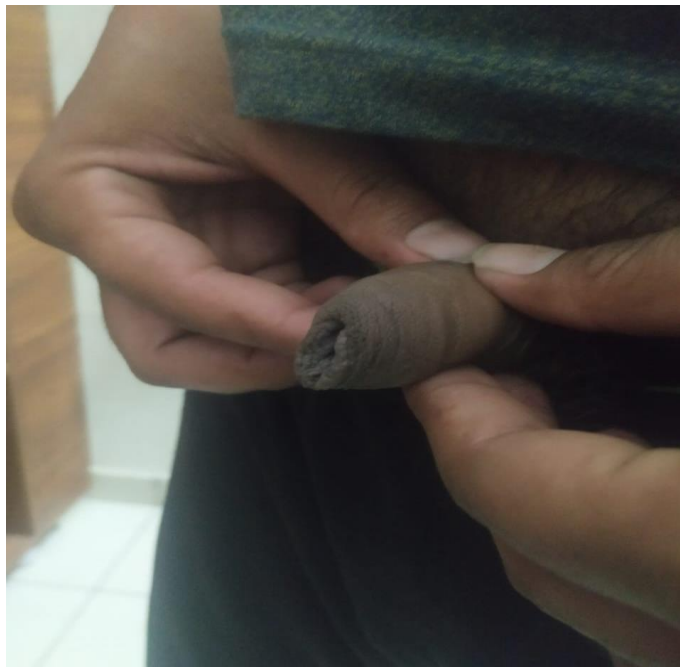

Figure 4 (B)



**Figure 4 (C)**

## DISCUSSION

Condyloma Acuminatum is a non-neoplastic tumor-like lesion. Lesions may occur singly or there may be conglomerated papillomas. In this case, reported patient is cured by some dose of Acid Nitricum and Thuja as intercurrent medicine. This case was very challenging because the patient was very hopeless with his disease. Homoeopathy can cure any kind of genital warts with the help of well-selected medicine based on the totality of symptoms.

## CONCLUSION

The above case report suggests the successful treatment of genital warts as well as other symptoms of the patient with the help of constitutional homoeopathic medicine.

## ACKNOWLEDGEMENTS

Nil

## PATIENT CONSENT

Patient consent was taken for publishing photos and case report.

**SPONSORSHIP**- Nil

## CONFLICT OF INTEREST

None declared

## REFERENCES

- 1) Pennycook KB, McCready TA. Condyloma Acuminata [Internet]. StatPearls Publishing LLC; 2023 Jun 21[cited 2023 Jun 20]. Available from: <https://www.ncbi.nlm.nih.gov/books/NBK547667/#:~:text=Condyloma%20acuminata%20refers%20to%20anogenital,primarily%20spread%20through%20sexual%20contact.>
- 2) Khopkar US, Rajagopalan M, Chauhan AR, Talwar SK, Singhal PK, Yee k et al. Prevalence and burden related to genital warts in India [Internet]. Mary Ann Liebert Inc. Publishers; 2018 Jun 1 [cited 2023 Jun 20]. Available from: <https://www.liebertpub.com/doi/full/10.1089/vim.2017.0157>
- 3) Chandra N D. Evidence based homoeopathy in treating Condyloma Acuminatum – a prospective and interventional study [Internet]. Indore: Innovare Academic Sciences Pvt. Ltd; 2013 Jan [cited 2023 Jun 20]. Available from: <https://innovareacademics.in/journal/ajpcr/Vol6Suppl1/1549.pdf>.