

KNOW Homoeopathy Journal

Bi-Annual, Indexed, Double-Blind, Peer-Reviewed, Research Scholarly, Online Journal in Field of Homoeopathy

KNOW Homoeopathy Journal Vol-3 & Issue-1, 15 March 2023, Published at

<https://www.knowhomoeopathyjournal.com/2023/03/volume-3-issue-1.html>, Pages: 56 to 61 , Title: A Case study on alopecia areata treated with individualised homoeopathic remedy, Authored By: Dr. Devika Chaturvedi & Co-Authored By: Dr. Ram Prasad Yadav, Dr. Zubair Ali khan (PGT, State National Homoeopathic Medical College and Hospital, Lucknow, Uttar Pradesh, India.)



VOLUME-3 ISSUE-1
MARCH 2023

CASE REPORT

Title- A case study on alopecia areata treated with individualised homoeopathic remedy

Authored By: Dr. Devika Chaturvedi^[1] & Co-Authored By: Dr. Ram Prasad Yadav^[2], Dr. Zubair Ali khan^[3]
^{[1][2][3]}PGT, State National Homoeopathic Medical College and Hospital, Lucknow, Uttar Pradesh, India.

ABSTRACT-

This is a case report of a male patient with Alopecia areata. The patient presented in the OPD of State National Homoeopathic Medical College and Hospital, Lucknow. When patient came for consultation he was having single coin shaped bald spot on the scalp. After thorough case taking totality of symptoms were erected and the case was repertorized using synthesis repertory. Prescription was made finally on the basis of physical and mental generals keeping in the mind materia medica and homoeopathic principles. The case showed improvement within 3 months of treatment.

Keywords: *Alopecia areata, Alopecia totalis, Alopecia universalis, Anagen, Baldness, Homoeopathy, Synthesis repertory, Telogen*

Received: 19/10/2022

Accepted: 09/12/2022

Published: 15/03/2023

How to cite this case report:

Chaturvedi D, Yadav R, Khan Z. A case study on alopecia areata treated with individualized homoeopathic remedy, KNOW Homoeopathy Journal, 2023; 3(1):56-61, available at <https://www.knowhomoeopathyjournal.com/2023/03/Case-study-on-alopecia-areata-treated-with-individualised-homoeopathic-remedy.html>

© 2023 KNOW Homoeopathy Journal

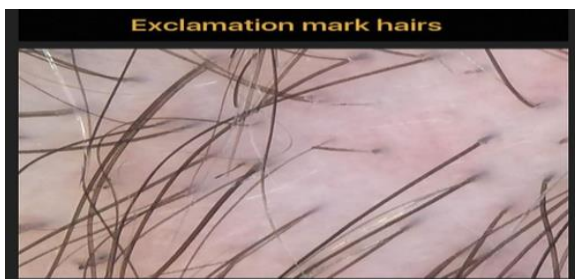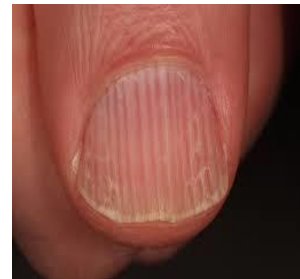[Know more about Journal's Copyright Policy](#)<https://www.knowhomoeopathyjournal.com/p/copyright-policy.html>**INTRODUCTION-**

Alopecia areata (AA) is an inflammatory condition of the scalp characterized by non-scarring type of coin shaped bald spots on the head. Clinically, it can present with small circumscribed patches of baldness to a complete absence of hairs of body or scalp.^[1] Following are the causes:

1. Autoimmune involvement^[2]
2. Environmental factors like Injury sites and viral infections of the scalp.
3. Genetic predisposition.
4. Stress
5. Nutritional deficiency- iron and zinc deficiency can trigger the disease.^[3]

The key clinical features are-

1. "Exclamation point hairs"- Hairs are narrow at the base, looking like an "exclamation point" mark.
2. Coin shaped bald spot- Round patches of hair loss, smooth in appearance and sharply demarcated.
3. Nail abnormalities found in 7% to 66% of patients.^[4]

Figure 1 - Exclamation Mark Hairs^[5]Figure 2 - Nail Appearance in Alopecia Areata^[6]**The diagnosis is typically clinical-**

1. Trichoscopy or positive hair pull test - Yellow dots, black dots are seen.
2. Vellus hair in lesions indicates inactive disease.
3. Biopsy - rarely needed for diagnosis.^[7]

Among treatment options, in modern medicine injection of corticosteroids are administered at the bald area.

The case mentioned below showed improvement within 3 months of homoeopathic treatment. There are previous studies also in which homoeopathy showed marvellous results in alopecia patients; one with Lycopodium^[8] and one with Mercurius.^[9]

CASE REPORT**PRESENT COMPLAINT**

Male patient of 24 yrs presented with the complaint of alopecia areata since 3 months; a single bald patch on scalp. There were no other major complaints but the patient being a youngster was very much stressed about the prognosis of this condition.

PAST HISTORY

9-10 months earlier he had some mental trouble (symptoms were insomnia and indifference to his work) for which he took allopathy treatment for 1 month.

FAMILY HISTORY

Father- Diabetes mellitus
 Grand mother- Osteoarthritis
 Mother – nothing specific
 Sister - nothing specific
 Brother - nothing specific

PHYSICAL GENERAL SYMPTOMS

Appetite – reduced
 Thirst – approx 3 liters per day
 Desire – salty food+
 Aversion – nothing specific
 Stool – normal, early in the morning
 Urine – normal, 4-5 times/day
 Perspiration – face, palms and soles
 Thermal - Hot
 Tongue - clean
 Sleep – normal, position on back
 Dreams – nothing specific

MENTAL GENERAL SYMPTOMS

1. Strong Company desire
2. Consolation amelioration
3. Sympathetic towards suffering of others.

4. History of fright one year ago in the dream (saw someone killed him).
5. After this fright in the dream, mental disturbance started.
6. Fear of dark.

ANALYSIS OF SYMPTOMS**Common symptoms-**

1. Falling of hairs of scalp.
2. Stressed about personal appearance.

Uncommon symptoms-

1. Ailments from fright.
2. Desire for company.
3. Sympathetic.
4. Fear of dark.
5. Consolation amelioration.
6. Desire for salty food.

TOTALITY OF SYMPTOMS

1. Ailments from fright.
2. Desire for company.
3. Sympathetic.
4. Fear of dark.
5. Consolation amelioration.
6. Desire for salty food.
7. Falling of hairs of scalp.

TABLE-1 MIASMATIC ANALYSIS

SYMPTOMS	PSORA	SYPHILIS	SYCOSIS
Ailments from fright	+		
Desire for company	+		
Sympathetic	+		
Fear of dark	+	+	
Consolation amelioration	+		
Desire for salty food	++	+	
Falling of hairs of scalp resulting in baldness	++	+	

RUBRICS TAKEN [8]

1. Mind - ailments from - fright
2. Mind - company- desire for
3. Mind - sympathetic
4. Mind – consolation – amel.
5. Mind – fear - dark;of
6. Generals - food and drink - salt desire
7. Head – hair - baldness

REPERTORIAL ANALYSIS

Synthesis repertory was used to repertorize the

case [10] “Repertorium Homoeopathicum Syntheticum” and RADAR software was used.

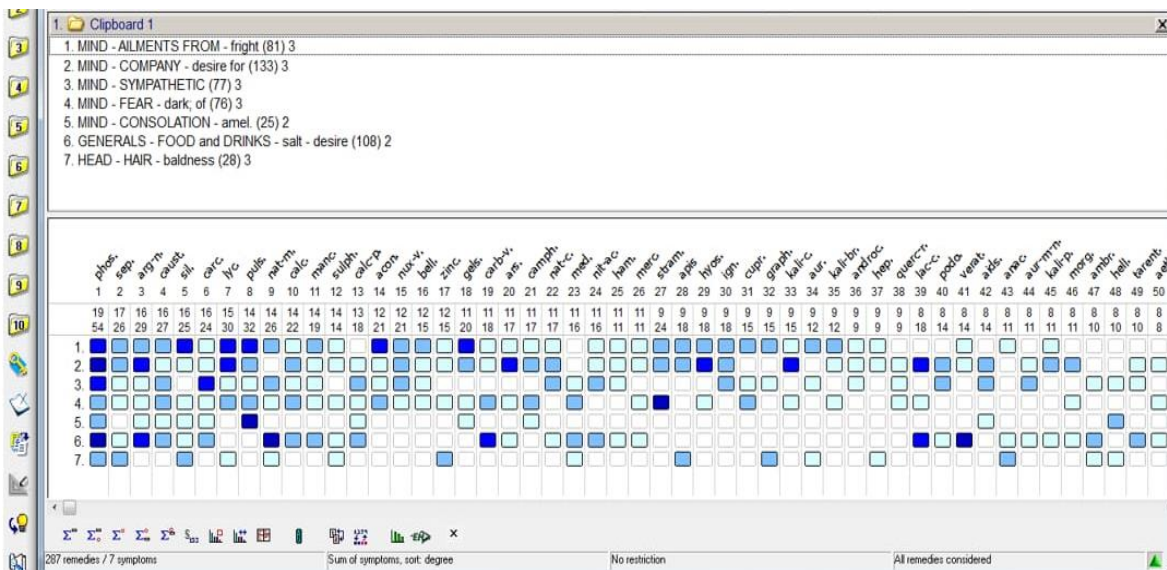


Figure 3-Repertorization

PRESCRIPTION

1. Phosphorous 200/ 3 DOSES; OD for 3 days
2. Sac Lac 30 TDS for 15 days

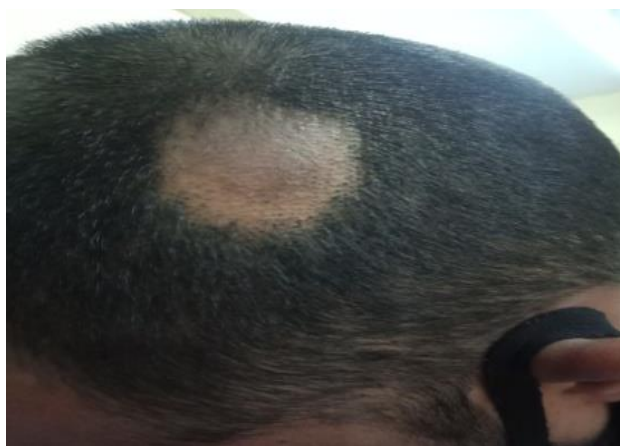

Figure 4-First Visit (21/02/2022)

FOLLOW-UP

S.NO.	DATE	SYMPTOM	PRESCRIPTION
1.	21/02/2022	<ul style="list-style-type: none"> • Coin shaped baldness at a single spot • Patient was stressed about personal look 	Phosphorous 200/3doses

2.	07/03/2022	<ul style="list-style-type: none"> Slight growth of hairs at bald spot 	Sac lac 30/tds
3.	22/03/2022	<ul style="list-style-type: none"> Size of the patch reduced Hairfall reduced Hair growth started at bald spot 	Sac lac 30/tds
4.	13/04/2022	<ul style="list-style-type: none"> Size of the patch reduced Hairfall reduced 	Sac lac 30/tds
5.	09/05/2022	<ul style="list-style-type: none"> No complaint Patient came to take medicine to prevent reoccurrence of disease. 	Phosphorous 200/1 dose
6.	30/05/2022	<ul style="list-style-type: none"> No complaint 	Sac lac 30/tds

Table-2 Followups

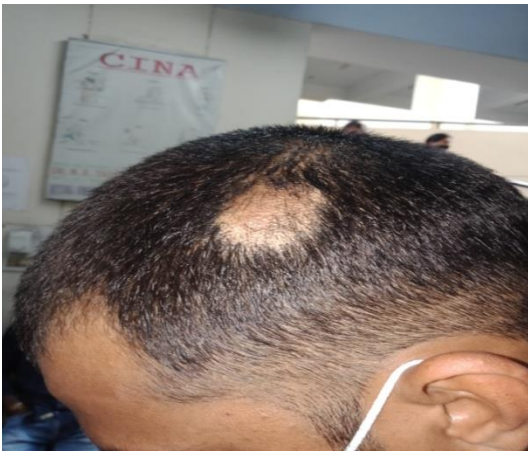

Figure-5-Third follow up

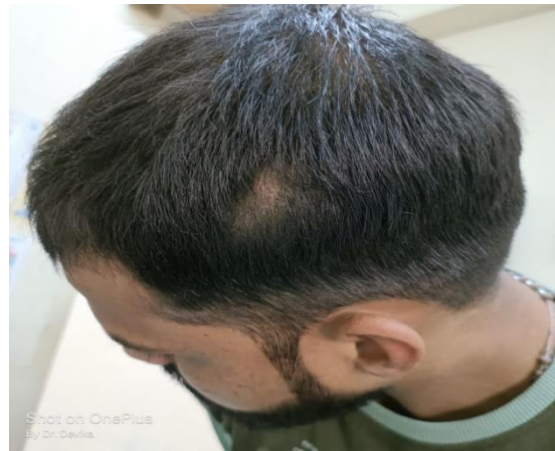

Figure-6-Fourth follow up



Figure-7-Fifth follow up



Figure-8-Sixth follow up

DISCUSSION

Holistic approach is the key to cure any mental or physical ailment in homoeopathy. The patient had no family history of AA, a detailed case taking helped us to find out the individualized homoeopathic medicine which resulted in marked improvement. This case shows effectiveness of homoeopathy in treating auto-immune conditions; which find no effective treatment in conventional medicines. Thus, a homoeopathic remedy selected after proper case taking on the basis of totality will always prove fruitful whatever be the pathology.

CONCLUSION

Homoeopathy is effective in management of Alopecia areata as this case has shown marvellous improvement under individualized homoeopathic remedy selected on the basis of totality, without any recurrence. However, this is a single case study and further case reports and scientific researches should be done in future for validation of results.

ACKNOWLEDGEMENTS

The authors are thankful to the whole fraternity of State National Homoeopathic Medical College and Hospital, Lucknow for their proper guidance and a special thanks to the patient for giving his consent to publish this study.

SPONSORSHIP- Nil

CONFLICT OF INTEREST- None declared

REFERENCES

1. Strazzulla LC, Wang EHC, Avila L, Lo Sicco K, Brinster N, Christiano AM, Shapiro J. Alopecia areata: Disease characteristics, clinical evaluation, and new perspectives on pathogenesis. *J Am Acad Dermatol*. 2018 Jan;78(1):1-12. doi: 10.1016/j.jaad.2017.04.1141. PMID: 29241771.
2. Islam N, Leung PS, Huntley AC, Gershwin ME. The autoimmune basis of alopecia areata: a comprehensive review. *Autoimmun Rev*. 2015 Feb;14(2):81-9. doi:10.1016/j.autrev.2014.10.014. Epub 2014 Oct 12. PMID: 25315746.
3. Seetharam KA. Alopecia areata: An update. *Indian J Dermatol Venerol Leprol* 2013;79:563-575
4. Darwin E, Hirt PA, Fertig R, Doliner B, Delcanto G, Jimenez JJ. Alopecia areata: Review of epidemiology, clinical features, pathogenesis, and new treatment options. *Int J Trichol* 2018;10:51-60
5. Exclamation mark hairs are short hairs that are commonly seen in early alopecia areata. They can also be seen in trichotillomania as shown here. #trichotillomania #hairloss #hair [Internet]. Flickr. Available from: <https://www.flickr.com/photos/130953263@N02/30270073794>
6. Altmeyer DMP. Brachyonychia - Altmeyers Encyclopedia - Department Dermatology [Internet]. Altmeyers.org. Altmeyers Encyclopedia; 2020. Available from: <https://www.altmeyers.org/en/dermatology/brachyonychia-118840.amp>
7. Mubki T, Rudnicka L, Olszewska M, Shapiro J. Evaluation and diagnosis of the hair loss patient: Part II. Trichoscopic and laboratory evaluations. *J Am Acad Dermatol* 2014;71:431.e1-431.e11.
8. Shivadikar AP. Evidence- based homoeopathy: Case report of alopecia areata in an 11 year old boy. *Indian J Res Homoeopathy* 2019;13:251-5
9. Itamura R. Effect of homeopathic treatment of 60 Japanese patients with chronic skin disease. *Complement Ther Med* 2007;15:115-20.
10. Schroyens F. Synthesis Repertorium Homoeopathicum Syntheticum 9.1ed. B. Jain Publishers Ltd. 2008