

KNOW Homoeopathy Journal

Bi-Annual, Indexed, Double Blind, Peer-Reviewed, Research Scholarly Online Journal in Field of Homoeopathy

KNOW Homoeopathy Journal Vol-2 & Issue-2, 18 October 2022, Published at <https://www.knowhomoeopathyjournal.com/2022/10/volume-2-issue-2.html>, Pages: 150 to 158, Title: Infinity role of homoeopathy in surgical diseases – A case report on treatment of subungual corn with homoeopathy, Authored By: Dr. Ajay Kumar (M.D (Hom), Assistant Professor Department of Pathology & Microbiology – Swasthya Kalyan Homoeopathic Medical College and Research Centre, Jaipur, Rajasthan, India)

Title: Infinity role of homoeopathy in surgical diseases –A case report on treatment of subungual corn with homoeopathy

Authored By:- Dr. Ajay Kumar

M.D (Hom.), Assistant Professor Department of Pathology & Microbiology - Swasthya Kalyan Homoeopathic Medical College & Research Centre, Jaipur, Rajasthan, India



ABSTRACT

“A corn is a tough thickening of the outermost layer of the skin that is frequently subjected to friction. Corns are found as common foot problems in 14–48 % of people. Corn may be present in single or multiple. Sometime corn develop under nail is very much painful condition. It can affect daily quality of life (QoL). This case study gives an idea about infinity possibilities of homoeopathy medicine in various types of surgical diseases especially subungual corns.”

Keywords: Corns, QoL, Homoeopathy

INTRODUCTION

A **corn** is a cone-shaped and sometimes painful, inwardly directed callus of dead skin.^[1] Corns may be found as hard corns (heloma durum), heloma molle (soft corn), heloma unguium (callused nail groove), and the heloma hallux (pinch callus).

Received: 31/08/2022

Accepted: 11/10/2022

Published: 18/10/2022

How to cite this case report:

Kumar A. Infinity role of homoeopathy in surgical diseases –A case report on treatment of subungual corn with homoeopathy. KNOW Homoeopathy Journal, 2022; 2(2):150-158, available at <https://www.knowhomoeopathyjournal.com/2022/10/case-report-subungual-corn-with-homoeopathy.html>

© 2022 KNOW Homoeopathy Journal

Know more about Journal's Copyright Policy <https://www.knowhomoeopathyjournal.com/p/copyright-policy.html>

KNOW Homoeopathy Journal

Bi-Annual, Indexed, Double Blind, Peer-Reviewed, Research Scholarly Online Journal in Field of Homoeopathy

Subungual corn (heloma) appears as a circumscribed, sharply demarcated area of hyperkeratosis with a translucent core. Mostly located around distal nail bed of the big toenail.^[2]

CASE REPORT

Name – xxxx

Age – 28 years

PRESENT COMPLAINTS

Multiple corns on finger and sole of right foot since 4 months. Corns are painful while walking.

Pain pulsating < touch, walking, cold application, pain > with hot application.

A single corn is present under nail of middle finger of right foot, which uplift nail.

Offensive pustular discharge from nails because of secondary infection.

PAST HISTORY – NAD

FAMILY HISTORY – Mother – Hyperthyroidism

Father – NAD

PHYSICAL GENERALS

Appetite – Normal

Desires – Not specific

Aversions – Not specific

Thermal – Chilly +++

KNOW Homoeopathy Journal

Bi-Annual, Indexed, Double Blind, Peer-Reviewed, Research Scholarly Online Journal in Field of Homoeopathy

Thirst – Thirsty +

Stool – Once in a day, stool normal in colour and consistency.

Urine – 5-6 time in 24 hours without any problem.

Sweat – Profuse sweat, Not offensive, No stain

Sleep/dreams – Not Specific

Appearance – Lean, thin, tall body.

MENTAL GENERALS

Anxious++

Yielding nature ++

Irritable on slight trifles +++

ANALYSIS OF CASE

MIND - Anxious

Yielding nature

Irritable on slight trifles

PHYSICAL GENERAL - Profuse Perspiration

Chilly patient

CHARACTERISTIC PARTICULAR - Multiple corns in foot

Painful corn

Inflamed corn

REPERTORIAL TOTALITY WITH REPERTORIZATION

KNOW Homoeopathy Journal

Bi-Annual, Indexed, Double Blind, Peer-Reviewed, Research Scholarly Online Journal in Field of Homoeopathy

- (1) Mind – Anxiety
- (2) Mind – Yielding Disposition
- (3) Mind – Irritability
- (4) Perspiration – Profuse
- (5) Extremities – Corn – Painful
- (6) Extremities – Corn – Inflamed
- (7) Extremities – Corn - Sore

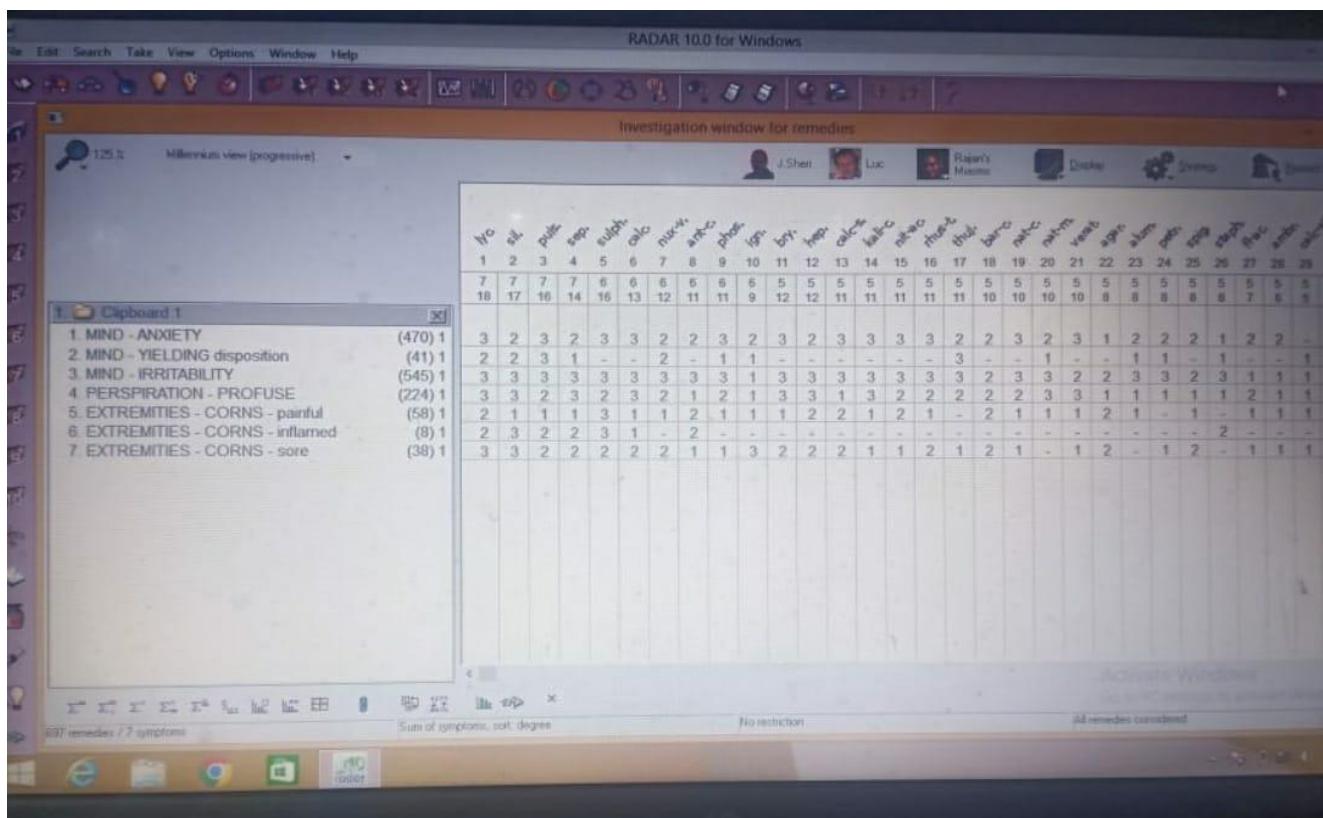


Figure 1-Repertorization Chart

PRESCRIPTION - 12/03/22

Silicea 200 / 3 doses / OD / Empty Stomach for 3 days

Rubrum 30 / 3 for 7 Days.

KNOW Homoeopathy Journal

Bi-Annual, Indexed, Double Blind, Peer-Reviewed, Research Scholarly Online Journal in Field of Homoeopathy

Table 1: Follow up sheet

DATE	SYMPTOMS	PRESCRIBE MEDICINE
25/03/22	Pain mild improve, No Discharge	Rubrum 30 /3 For 7 days
2/04/22	Pain continuous improve in all corns, No Discharge from finger	Rubrum 30 /3 For 7 days
6/04/22	Pain only hard pressure, No Discharge	Rubrum 30/3 For 7 days
15/04/22	No pain from all corn, gradually decrease in size	Rubrum 30/3 for 14 days
10/05/22	All corn clear	Rubrum 30/3 for 1 Month
16/07/22	Patient is alright	Rubrum 30/3 for 7 days

Table-1 Follow Ups

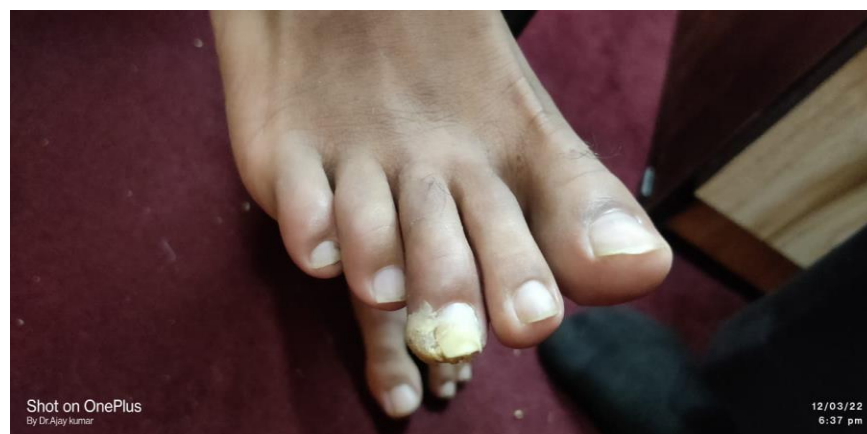

Figure 2

KNOW Homoeopathy Journal

Bi-Annual, Indexed, Double Blind, Peer-Reviewed, Research Scholarly Online Journal in Field of Homoeopathy

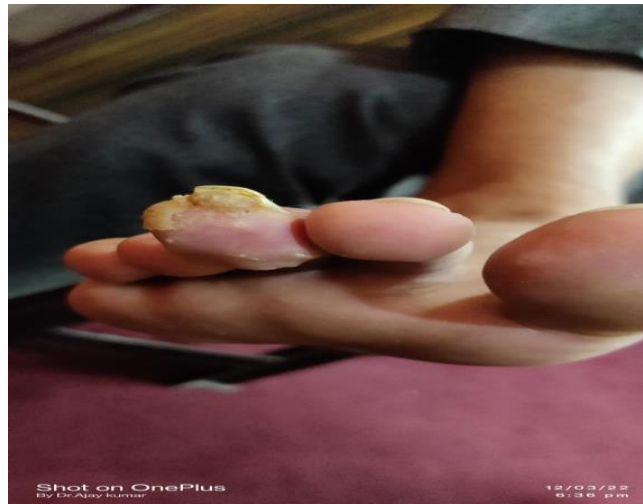

Figure 3

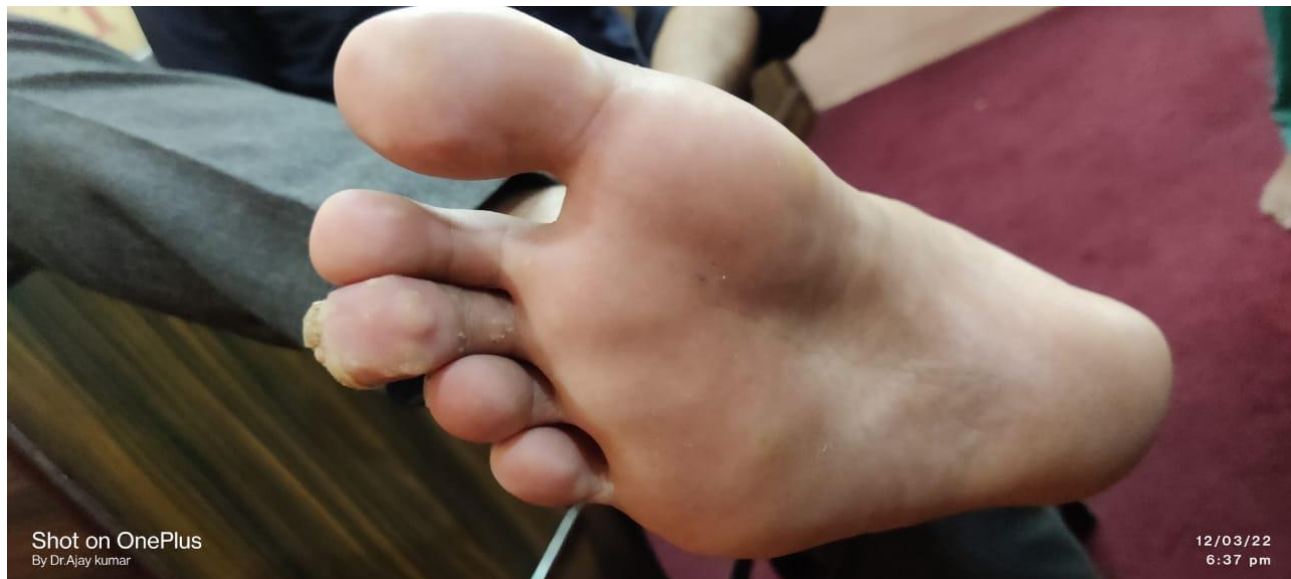

Figure 4

Figure-2-4-(FIRST VISIT-12/03/22)

KNOW Homoeopathy Journal

Bi-Annual, Indexed, Double Blind, Peer-Reviewed, Research Scholarly Online Journal in Field of Homoeopathy

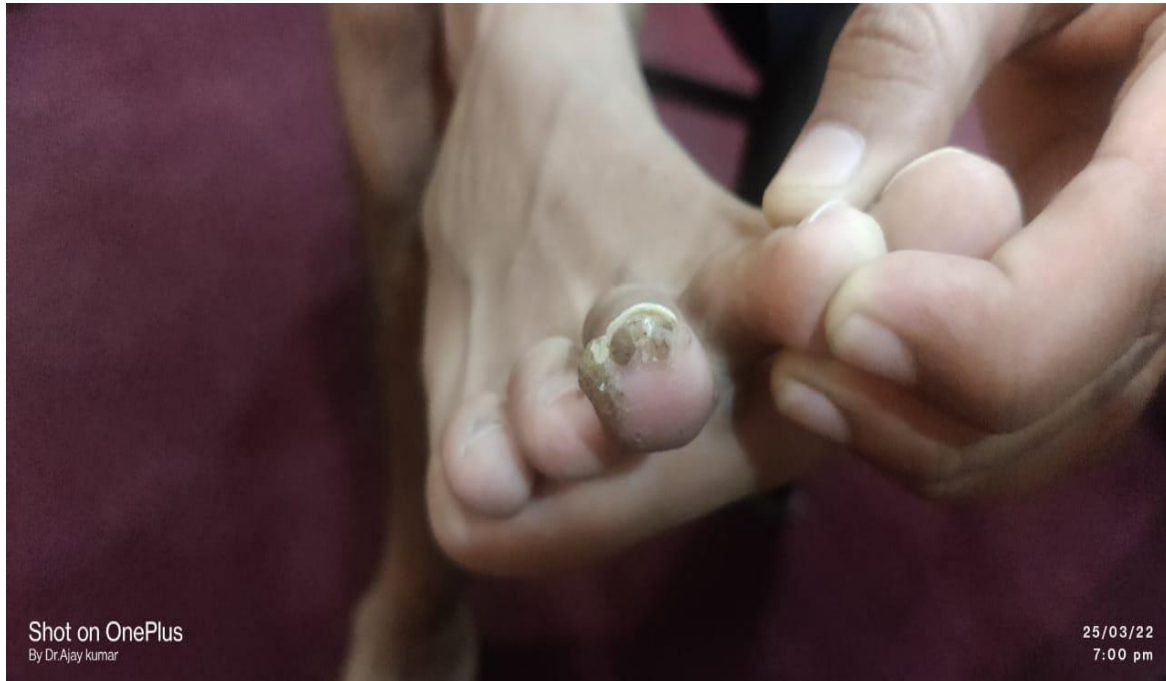

Figure 5

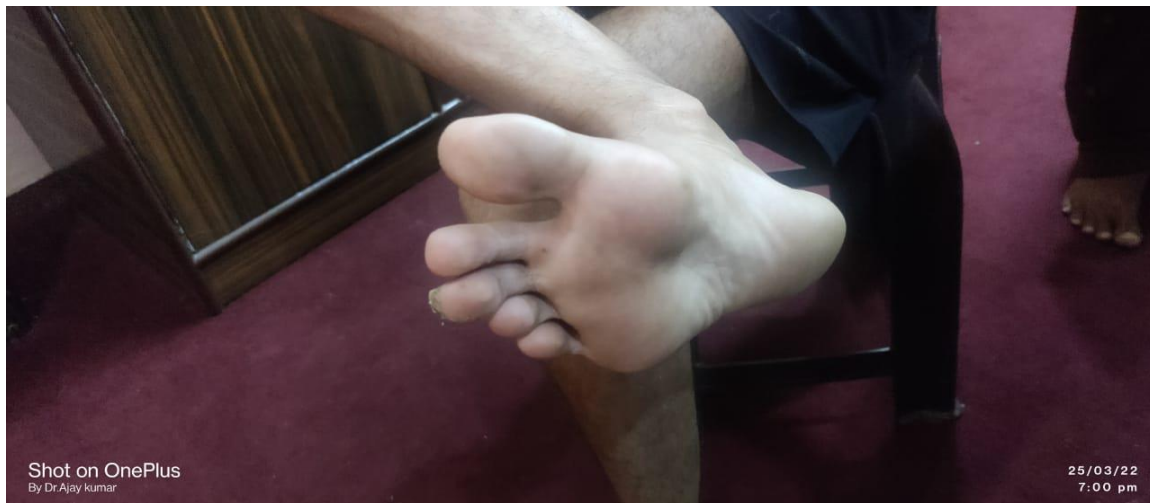

Figure 6

Figure-5-6-(SECOND VISIT-25/03/22)

KNOW Homoeopathy Journal

Bi-Annual, Indexed, Double Blind, Peer-Reviewed, Research Scholarly Online Journal in Field of Homoeopathy

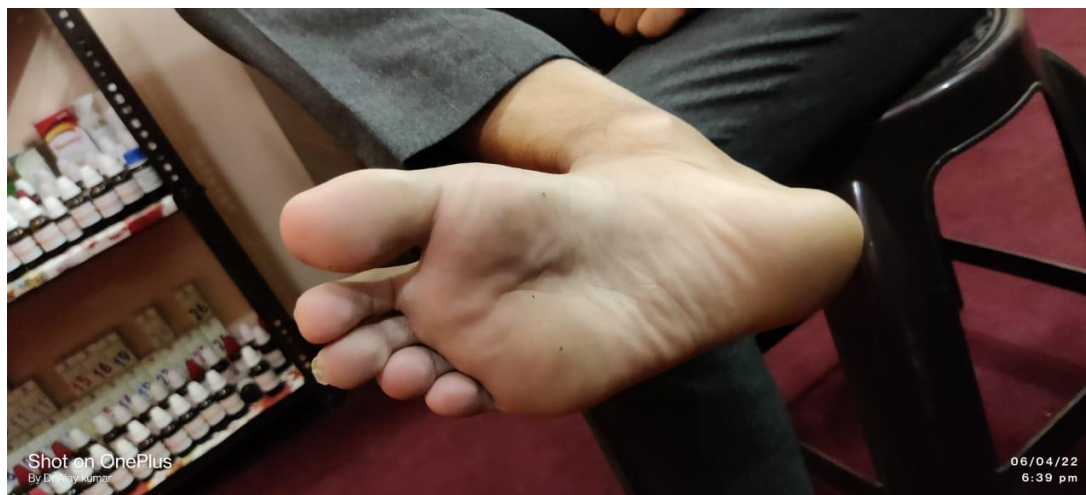

Figure 7

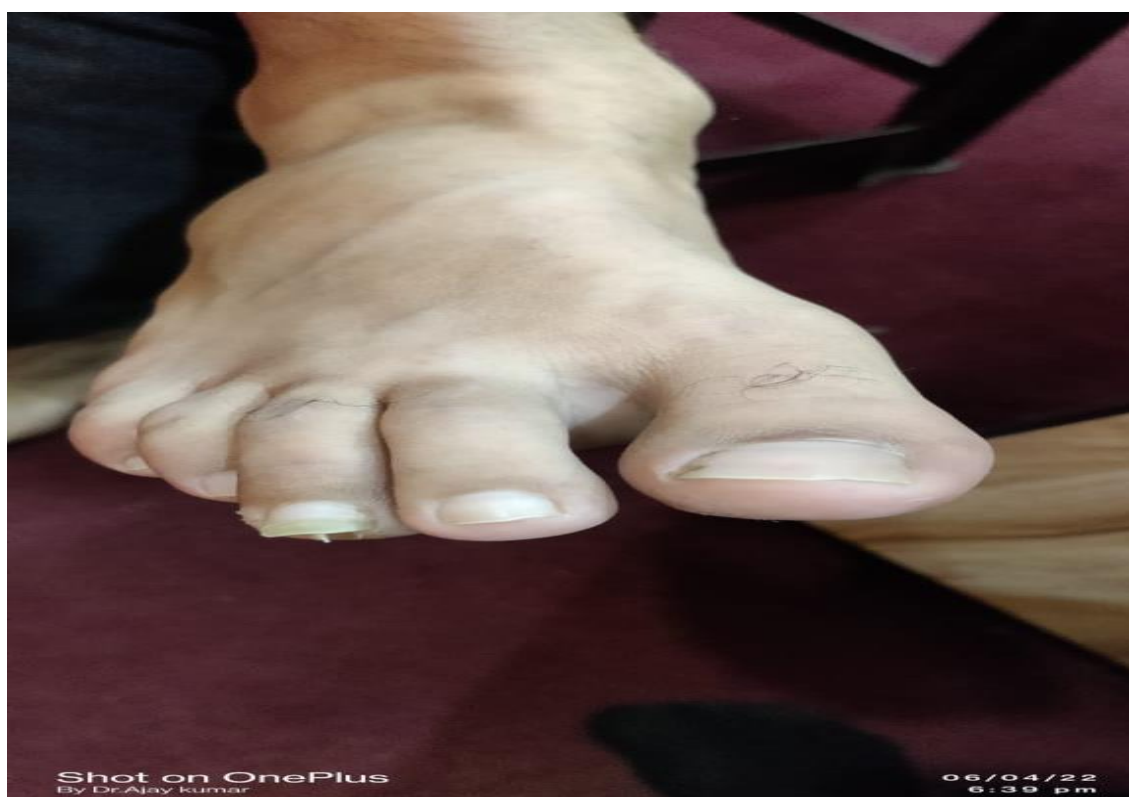

Figure 8

Figure-6-7-(FOURTH VISIT-06/04/22)

KNOW Homoeopathy Journal

Bi-Annual, Indexed, Double Blind, Peer-Reviewed, Research Scholarly Online Journal in Field of Homoeopathy

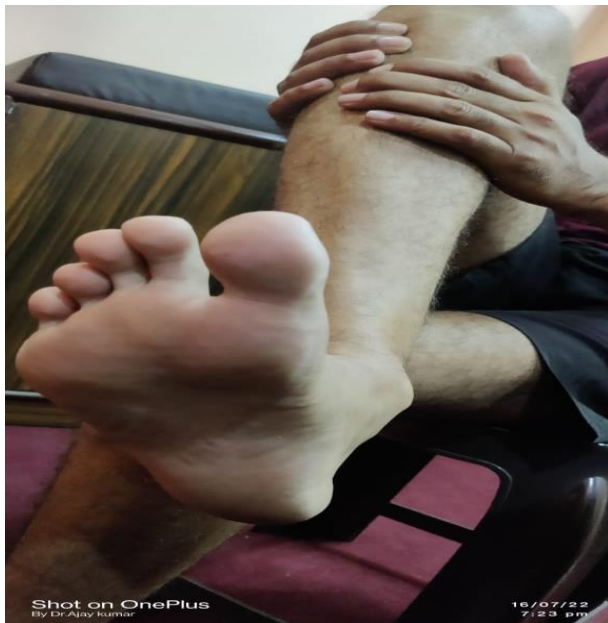

Figure 9

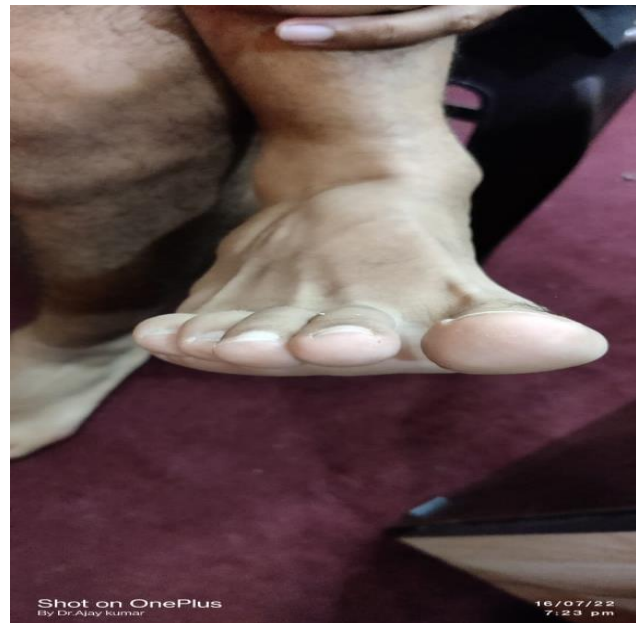

Figure 10

Figure-9-10-(LAST VISIT-16/07/22)

REFERENCES

1. Corn (pathology) – Wikipedia [Internet] Available From [https://en.wikipedia.org/wiki/Corn_\(pathology\)](https://en.wikipedia.org/wiki/Corn_(pathology))
2. Callosity [Internet] Available From <https://www.sciencedirect.com/topics/medicine-and-dentistry/callosity>