

# KNOW Homoeopathy Journal

Bi-Annual, Indexed, Double Blind, Per-Reviewed, Research Scholarly Online Journal in Field of Homoeopathy

KNOW Homoeopathy Journal Vol-2 & Issue-2, 18 October 2022, Published at <https://www.knowhomoeopathyjournal.com/2022/10/volume-2-issue-2.html>, Pages: 100 to 110, Title: A case report of genital warts treated with homoeopathy, Authored By: Dr. Mansi Srivastava ( PhD Scholar, Assistant Professor, Department of Forensic Medicine and Toxicology, Chandola Homoeopathic Medical College & Hospital, Uttrakhand, India)

**Title: A case report of genital warts treated with homoeopathy**

**Authored By:- Dr. Mansi Srivastava**

PhD Scholar, Assistant Professor, Department of Forensic Medicine and Toxicology, Chandola Homoeopathic Medical College & Hospital, Uttrakhand, India.

## ABSTRACT

*“This is a case report of a male patient with Genital warts. When patient came for consultation he was having multiple bleeding warts in and around his genitals, thighs, and buttocks. After thorough case taking totality of symptoms were erected and the case was repertorized using synthesis repertory in which we got few homoeopathic medicines including Nitric Acid, Lycopodium, sepia, calcarea carb, Causticum, and phosphoric acid. Prescription was made finally on the basis of physical and mental generals keeping in the mind materia medica and homoeopathic principles.”*

**Keywords:** Genital warts, Nitric acid, Bleeding, Synthesis repertory, Sycosis, Homoeopathy

## INTRODUCTION

Warts are small or large size non-cancerous growth on top layer of skin. As per allopathic school of medicine if one gets an infection from a virus, then they may have such appearance of skin growths. These growths are called **warts**<sup>[1]</sup>. Anyone can have warts. One may get from another person, or spread it yourself through touch or nail biting. HPV can also enter the body through damaged or cut skin. It can also be spread from

Received: 03/08/2022

Accepted: 13/08/2022

Published: 18/10/2022

### How to cite this case report:

Srivastava M. A Case report of genital warts treated with homoeopathy. KNOW Homoeopathy Journal, 2022; 2(2):100-110, available at

<https://www.knowhomoeopathyjournal.com/2022/10/case-report-genital-warts-.html>

© 2022 KNOW Homoeopathy Journal

Know more about Journal's Copyright Policy <https://www.knowhomoeopathyjournal.com/p/copyright-policy.html>

# KNOW Homoeopathy Journal

Bi-Annual, Indexed, Double Blind, Peer-Reviewed, Research Scholarly Online Journal in Field of Homoeopathy

mother to offspring. It can happen to person of any age group apparently healthy with no other symptoms or complaints.

As per Samuel Hahnemann “Father of Homoeopathy” any growth, accumulation or excessive secretion are due to sycosis miasm. So as per homoeopathic school of medicine warts occur due to underlying sycosis miasm in an individual.

## SYMPTOMS

Few symptoms of warts are as mentioned below:

- Warts may be Large or small, fleshy growths present on face, neck, fingers, hands, arms, legs, genitals or anywhere on body.
- Warts can be flat, smooth or rough.
- These can be painful to touch or non non-tender.
- Some warts causes itching and some have no sensation.

## TYPES-

**Warts are of various types[2]. Their type is determined by its location and appearance on the skin. Some commonly found types of warts are described below:**

### Common warts

If warts are located on fingers, on dorsum of hands, or neck, face then they are known as common warts. These warts feel like rough bumps.

Common warts are generally flesh-colored<sup>[2]</sup> and are small in size of a pinhead to a pea. These are rough or hard growths.

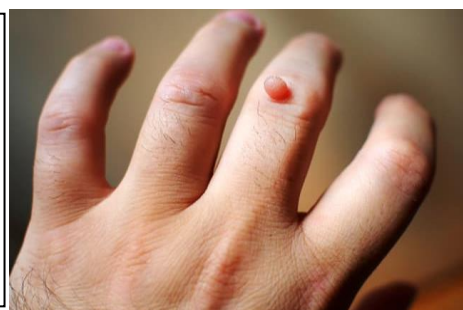

Figure 1-Common warts

# KNOW Homoeopathy Journal

Bi-Annual, Indexed, Double Blind, Peer-Reviewed, Research Scholarly Online Journal in Field of Homoeopathy

## Foot (plantar) warts

When warts are present on soles of the feet than they are known as plantar warts. They mostly grow in clusters and are sometimes painful from pressure exerted on walking and standing and this makes them grow *into* your skin. They may be appearing singly or in cluster. If plantar warts appear in clusters then they are called mosaic warts. As these warts are flat, tough, and thick, it's easy to confuse them with calluses.

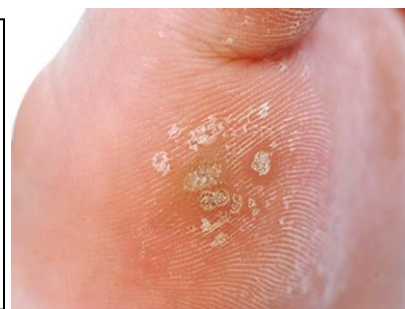

Figure 2-Plantar warts

## Flat warts

Flat warts are located anywhere on body. They are smaller than common warts and they grow in multiple in numbers.

Flat warts are smaller & smoother than other types. Flat warts mostly appear on face of children, legs or neck of women and beard area (face) of male.

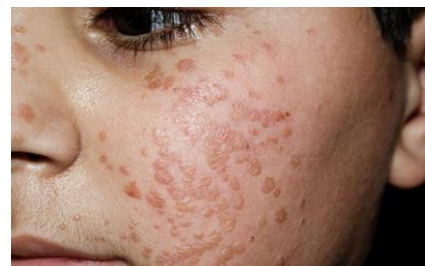

Figure 3-Flat warts

## Filiform warts

Filiform warts are mostly located on the fingers and they look like having long threads. Filiform warts tend to grow very quickly.

Filiform warts are fast-growing warts. They appear as thread-like and spiky, sometimes like tiny brushes. Because they tend to grow on the face, around mouth, eyes, and nose.

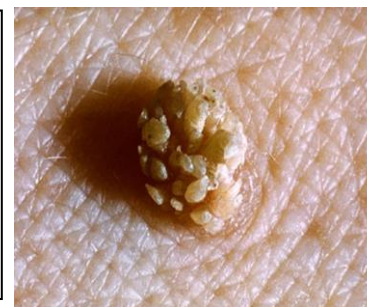

Figure 4-Filiform warts

# KNOW Homoeopathy Journal

Bi-Annual, Indexed, Double Blind, Peer-Reviewed, Research Scholarly Online Journal in Field of Homoeopathy

## Genital warts

These warts are located mostly in genital areas of male and female patients. They are usually caused due to infection caused by Human papillomavirus and are contracted by unprotected sexual activity or from mother to their feeding offspring. These are present in and around male & female genital, anus, mouth and throat. They may look like small, scattered, skin-colored growth or like a cluster of growths similar to a little bit of cauliflower on your genital. Genital warts differ in appearance from person to person.

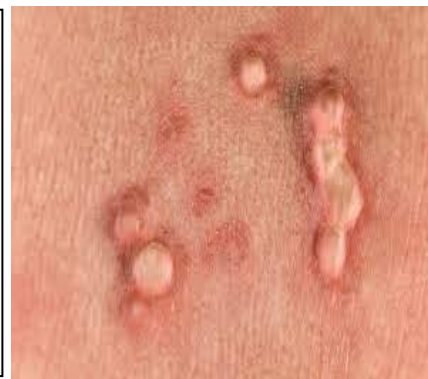

Figure 5-Genital warts

## DIAGNOSIS

Most of the warts are easily diagnosed by simple visual examination. Other tests which used to exclude malignancy are as follows:

- Biopsy: A small section of wart is removed and sent to a laboratory for studying the type of cells.
- Scraping off the top layer of wart to check for clotted blood vessels, it is common with warts

## TREATMENT

### ALLOPATHIC APPROACH

The allopathic healthcare provider may recommend the following treatments for removal of warts:

- **Salicylic acid.**
- **Freezing** (cryotherapy). During cryotherapy liquid nitrogen is applied on wart.
- **Acid treatments.** Few physicians use stronger acids than salicylic acid to remove the warts.
- **Laser treatment.** In this a small laser is used to burn tiny blood vessels surrounding wart. The infected tissue eventually dies and wart will fall off.

# KNOW Homoeopathy Journal

Bi-Annual, Indexed, Double Blind, Peer-Reviewed, Research Scholarly Online Journal in Field of Homoeopathy

## HOMOEOPATHIC APPROACH

As per **classical homeopathy**, as practiced by Dr. J.T. Kent, Dr. C.M. Boger, Dr. Von Boenninghausen and many other stalwarts, warts are treated by selecting similar medicine following law of similia i.e. “*Similia Similibus Curantur*”. A thorough and complete case taking of patient is done and a medicine similar to portrait of disease is selected and given to patient in similar, single, and simple medicine is given in suitable potency and dosage.

As per **clinical homeopathy**, as practiced by Dr. Oscar Boericke, Dr. Clarke, Dr. Robin Murphy and many other stalwarts warts are treated by therapeutic indications, few as mentioned below:

**Anacardium Orientalis:** If warts are located on palms of hand Anacardium can be given in repeated doses.

**Antimonium Crud**<sup>[3]</sup>: If warts are smooth and soft, located on soles, palm, and neck.

**Calcarea-carb [Calc]:** Warts on face, neck and hands, a critical excretion on cutis on scrofulous, chlorotic, hydrogenoid patients, especially youthful ones.

**Causticum [Caust]:** Warts which causes burning and bleeds easily. Old warts on nose and eyebrows, on face, nails and fleshy tips of fingers.

**Dulcamara [Dulc]:** Warts on face, lower eyelid and palm, large, smooth, sometimes nearly transparent coming in a crop.

**Ficus carica:** When fresh milky juice discharges breaking the stalk of warts.

**Lycopodium**<sup>[4]</sup> [Lyc]: Split and furrowed arts, surrounded by a herpetic areola, with barnlike desquamation.

**Natrum-mur [Nat-m]:** Old warts with cutting pains; numerous wart on hands and fingers in anaemic. chlorotic girls with pale, scanty, irregular menstruation, gastralgia, constipation, or for the anaemic nervous palpitations of overgrown boys with numerous warts on hands.

**Natrum-sulph [Nat-s]:** Knotty, waterlike eruption on anus, between abdomen and thighs; red, warty lumps all over body.

**Nitric-acid [Nit-ac]:** Moist warts, like cauliflower, hard, rhagadic or in thin pellicles, often emitting a foetid humor and bleeding when touched. Genital warts having itching and bleeds easily on touching.

**Rhus-tox [Rhus-t]:** Warts on fingers and hands with a broad, flushy face, upper part horny, rough, knotty, with a thickened epidermis, not sensitive, forming a gray or black crust and finally shrinking to a brown, hard crust, which falls off and healthy skin is underneath.

# KNOW Homoeopathy Journal

Bi-Annual, Indexed, Double Blind, Peer-Reviewed, Research Scholarly Online Journal in Field of Homoeopathy

**Sepia [Sep]:** Horny excrescences in centre; small flat; hard and itching warts situated on whole body.

**Thuja [Thuj]:** Broad, conical warts, easily splitting from their age on their surface; condylomata, sycosis. Warts present in crops sometimes oozing moisture or blood.

## **CASE REPORT**

### **PERSONAL DATA**

Name of patient: Master Altmas

Age: 2.5 years                      Sex: Male

### **PRESENTING COMPLAINS**

Patient came with multiple warty growths in and around genitals, medial side of both thighs, and in buttocks since 3-4 months.

Warts are multiple in numbers with large size with severe itching and bleeding many times on touching.

Patient is took allopathic treatment for this complaint in past.

### **HISTORY OF PRESENTING COMPLAINTS**

Patient has few soft and few hard warts in and around genitals, both thigh, and buttocks of large size since 3-4 months.

Child has severe itching of warts more in night and on contact with cloth (Aggravation).

**On examination** most of these warts are soft, tender and they bleed on touching or scratching. Warts are reddish in color. Swelling in scrotum.

Mother also had history of genital warts at time of this pregnancy with urinary tract infection

### **PAST FAMILY HISTORY**

Mouth Aphthae

# KNOW Homoeopathy Journal

Bi-Annual, Indexed, Double Blind, Peer-Reviewed, Research Scholarly Online Journal in Field of Homoeopathy

## **FAMILY HISTORY**

Father-Diabetes mellitus

Mother- Genital warts.

## **PHYSICAL GENERALS**

Thermal – Chilly

Thirst – Thirsty

Appetite-Poor

Desire –Sweets things

Aversion –Nothing specific

Intolerance- Peanuts, pomegranate

Stool –Satisfactory and regular (D<sub>2-3</sub> N<sub>0</sub>)

Urine- Itching during urination and very offensive urine.

Perspiration –profuse and offensive on forehead

Sleep –Disturbed Sleep due to itching of warts

Tongue- cleat and moist

## **MENTAL GENERALS**

Anger<sup>++</sup> patient shouts, cries and strike others when angry if anyone scold him.

Obstinate- cries until he got what he wants.

Irritability- very irritable child

Dullness of mind.

# KNOW Homoeopathy Journal

Bi-Annual, Indexed, Double Blind, Peer-Reviewed, Research Scholarly Online Journal in Field of Homoeopathy

## PROVISIONAL DIAGNOSIS

Genital warts

## TOTALITY OF SYMPTOMS

- Condylomata (wart) on genitals
- Swelling of scrotum
- Bleeding from warts
- Shouts and shrieks in anger
- Patient got angry easily
- Offensive urine

## RUBRICS TAKEN

- Male genitalia/sex- Condylomata
- Male genitalia/sex-swelling- Scrotum
- Skin-Warts-bleeding
- Mind-Shrieking
- Mind-Angry
- Urine-Odor-offensive

## REPERTORIAL ANALYSIS

Case was repertorized with synthesis repertory<sup>[5]</sup> ‘Repertorium Homoeopathicum Syntheticum’ written by Dr. Frederik Schroyens using RADAR software.



# KNOW Homoeopathy Journal

Bi-Annual, Indexed, Double Blind, Peer-Reviewed, Research Scholarly Online Journal in Field of Homoeopathy

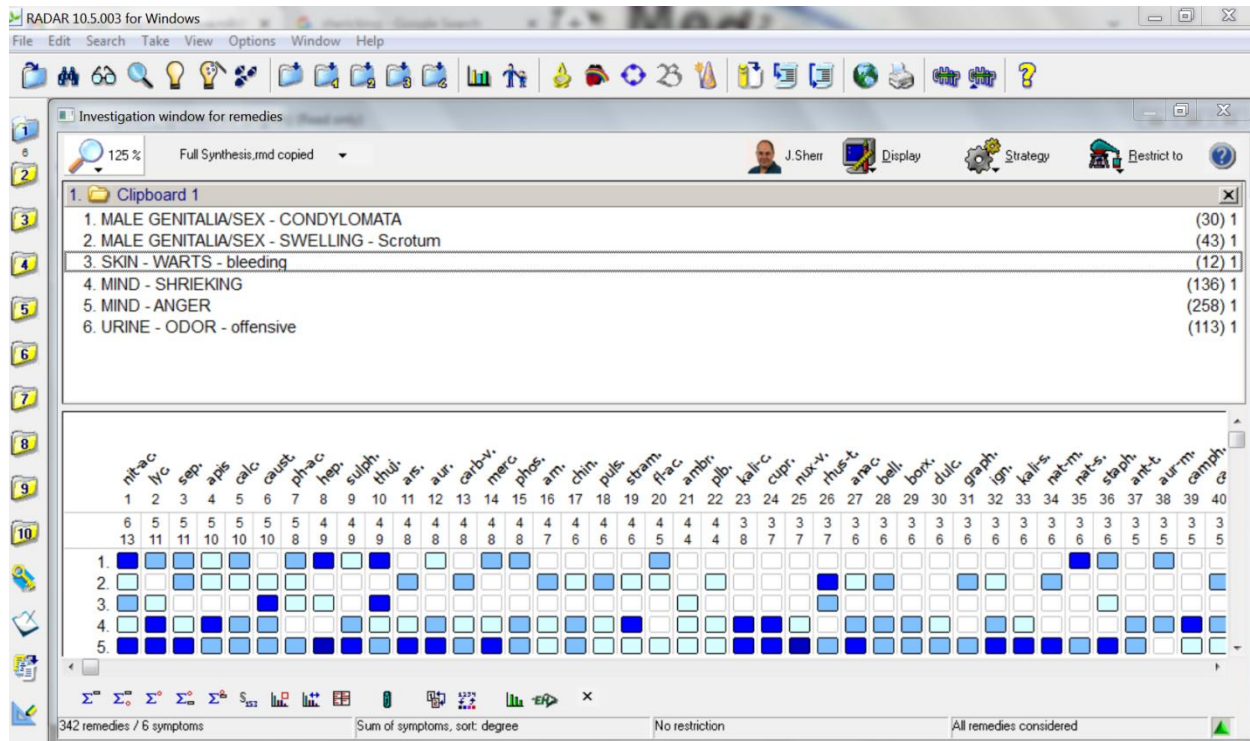


Figure 6-Repertorization chart

## PRESCRIPTION

Nitricum Acidum 30 BD x 5 days

## FOLLOW UP

DATE	SYMPTOMS	MEDICINES
23/02/2022	Patient 1 <sup>st</sup> visit for consultation	Nitric Acid 30 BD/7 days PL 30/BD/1 Month
15/03/2022	<ul style="list-style-type: none"> <li>Warts on genital region and thighs-reduced in number</li> <li>Itching reduced</li> <li>Swelling of scrotum reduced</li> </ul>	Nitric Acid 30 BD/7 days

# KNOW Homoeopathy Journal

Bi-Annual, Indexed, Double Blind, Peer-Reviewed, Research Scholarly Online Journal in Field of Homoeopathy

<p><b>09/04/2022</b></p>	<ul style="list-style-type: none"> <li>• Warts on genital region and thighs-only one in left</li> <li>• Itching absent</li> <li>• Swelling of scrotum reappears</li> </ul>	<p>Nitric Acid 30 BD/7 days</p>
<p><b>25/04/2022</b></p>	<ul style="list-style-type: none"> <li>• Warts on genital region and thighs-not present</li> <li>• Itching not present</li> <li>• Swelling of scrotum resolved</li> </ul>	<p>Sac Lac 30 BD/7 days</p>

*Table-1 Followup*

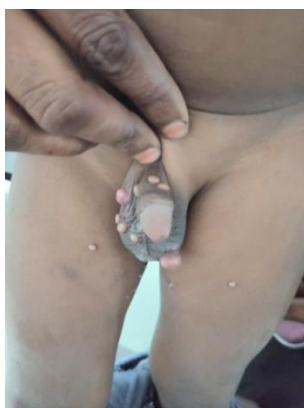

Figure-7  
23/02/2022



Figure-8  
15/03/2022



Figure-9  
09/04/2022



Figure-10  
25/04/2022

## CONCLUSION

Homoeopathic medicine selected on the basis of symptom similarity proved to be very effective in case of Genital warts and showed good improvement.

# KNOW Homoeopathy Journal

Bi-Annual, Indexed, Double Blind, Peer-Reviewed, Research Scholarly Online Journal in Field of Homoeopathy

## REFERENCES

- 1- <https://intermountainhealthcare.org/services/dermatology/conditions/warts/>
- 2- <https://www.webmd.com/skin-problems-and-treatments/ss/slideshow-warts>
- 3- Khaneja H.S., Illustrated guide to the homoeopathic treatment, B. Jain Publisher (P) Ltd., Third Edition, 729-730
- 4- <https://homeopathybooks.in/homeopathic-therapeutics-by-lilienthal-s/verrucae/>
- 5- Schroyens, Frederik: Repertorium Homoeopathicum Syntheticum.