

## **Title: Mastoiditis: An Evidence-based case report treated with homoeopathy**

**Authored By:- Dr. Mohammed Saif Ali Khan<sup>1</sup> & Co-Authored By: Dr. Rohan Badgujar<sup>2</sup>**

1. Homoeopathic Physician
2. Homoeopathic Physician

### **ABSTRACT**

Mastoiditis is a typical side effect of acute otitis media. Mastoiditis is a condition in which the mastoid air cells in the temporal bone become inflamed. The mastoid air cells, which connect the middle ear chamber to the outside world, are epithelium-lined bone septations. Children are more susceptible to middle ear infections than adults, therefore they have a larger risk of developing acute mastoiditis.<sup>[1]</sup>

**KEYWORDS:** Acute Mastoiditis, Mastoid air cells, Middle Ear Cavity, Acute Otitis Media, Lateral Sinus.

### **INTRODUCTION**<sup>[2]</sup>

Acute mastoiditis was rather prevalent among children. Because the air cells in the mastoid are related to the middle ear, the fluid collection and infection processes in the mastoid and middle ear are typically the same. The frequency of acute mastoiditis has decreased to only 1.2-2.0 instances per 100,000 person-years in countries with high prescription rates, because to early and frequent treatment of acute otitis media.

### **PATHOPHYSIOLOGY**<sup>[2]</sup>

In typical acute mastoiditis, purulent exudates collect in mastoid air cells, producing pressure that may lead to bone erosion and the formation of abscess-like cavities, which can be seen on CT scans.

### **CLINICAL FEATURES**<sup>[2]</sup>

Pain, erythema, and edoema of the mastoid process, as well as pinna displacement, are characteristic signs and symptoms of an acute middle ear infection in this patient.

The patient may suffer catastrophic repercussions if the infection penetrates through the periosteum of the temporal bone, generating a subperiosteal abscess, or erodes through the mastoid tip, causing septic thrombosis of the lateral sinus.

# KNOW Homoeopathy Journal

## CASE RECORD

A boy of 10yr old suffering from mastoiditis since 15 days & congenital hearing loss with swelling on back of left ear came to us on 12/12/2020.

## PRESENT HISTORY

Pulsating Pain with redness since 4 Days and swelling behind left ear since 15 days. Frontal headache with pulsating type of pain is present along with it.

## PHYSICAL GENERALS

**Desire :** Egg, Cold water, namkeen

**Tongue :**white coated

**Mind:-** Fear of animals,Fear of darkness, Religious mania, fear of height, During anger stammering

**Thermal Reaction:-** Chilly

**Perspiration:-** increase specially on chest

## ANALYSIS OF CASE

Mental Generals: Fear of Animals,Fear of Darkness,Fear of Height

Physical Generals: Chilly Patient, Desires for Egg, Cold water

Particulars: Swelling on back of left ear with pulsating pain with redness and pulsating pain in forehead.

Evaluation of Symptoms

Fear of Animals

Fear of Darkness

Desire egg, cold water

Behind left ear swelling with redness with pulsating pain

Pulsating pain in forehead.

Synthesis Repertory is selected due to presence of prominent mental symptoms and marked particulars.

## REPERTORIAL TOTALITY WITH REPERTORIZATION

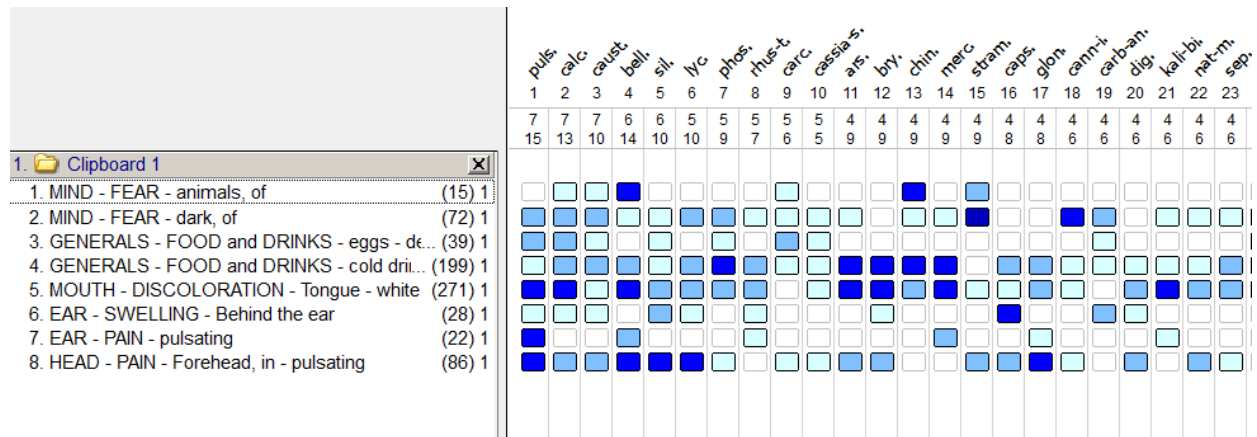


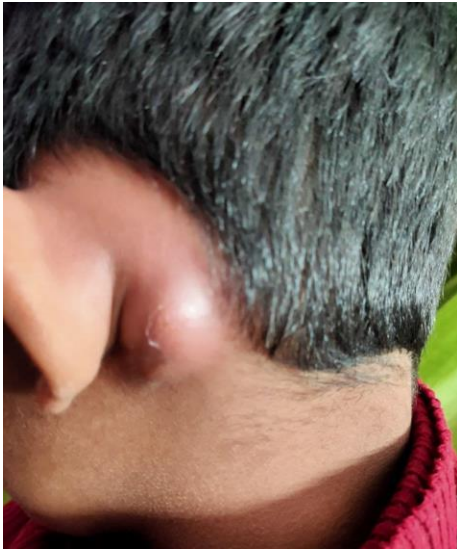Figure-1

## REPERTORIAL ANALYSIS

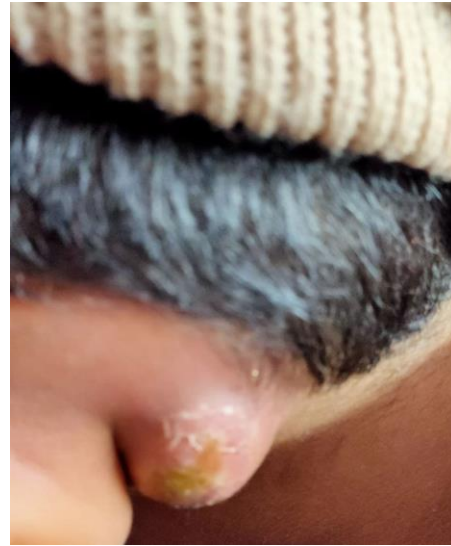On first visit Belladonna has been given to the patient in 30 CH potency by considering Redness,swelling and pain of left ear and forehead.

**Table 1: Follow up sheet**

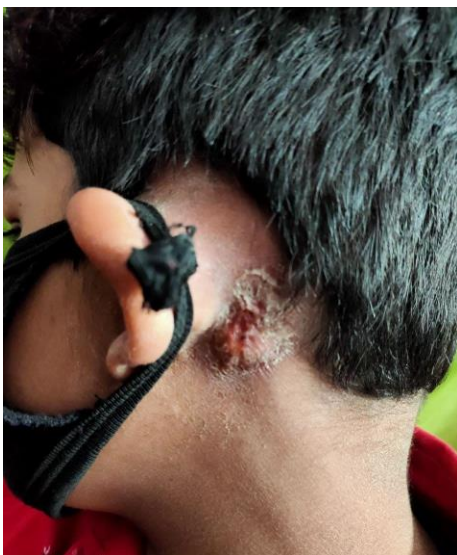| Date       | Symptoms   | Prescribed Medicine   |
|------------|--|---|
| 12/12/2020 | Pulsating pain in left ear with redness & swelling.<br><br>Pulsating pain in forehead. | Rx Belladonna 30 2/dose<br><br>Phytum 30 TDS X 5 Days           |
| 17/12/2020 | Head pain slightly decreases but Ear pain is constant                                  | Rx Phytum 30 TDS X 5 Days                                       |
| 23/12/2020 | S.Q.   | Rx Belladonna 200 /1 Dose<br>Stat<br><br>Phytum 30 TDS X 5 Days |
| 29/12/2020 | Head Pain is Relieved with pus formation & Ear pain is same as before.                 | Rx Phytum 30 TDS X 5 Days                                       |
| 03/01/2021 | S.Q.   | Rx Calc Carb 200/ 1Dose Stat<br><br>Phytum 30 TDS X 5 Days      |
| 09/01/2021 | Relief in Ear pain with discharge of pus   | Rx Sac Lac 200/ 1Dose Stat<br>Phytum 30 TDS X 5 Days            |
| 15/01/2021 | Major improvement in all symptoms with no discharge.                                   | Rx Phytum 30 TDS X 5 Days                                       |



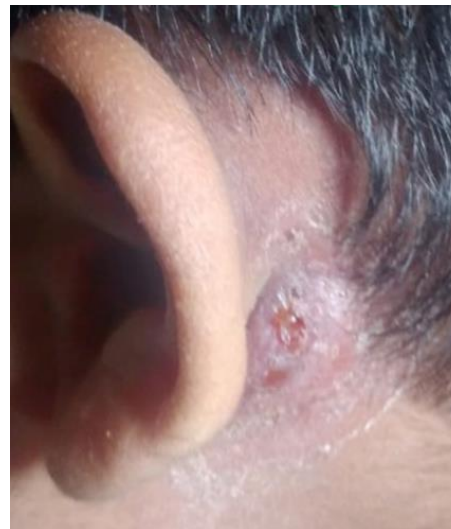First Visit



Fourth Visit



Sixth Visit



Last Visit

## References

1. <https://www.ncbi.nlm.nih.gov/books/NBK560877/>
2. Harrison's Principles of Internal Medicine 19/E (Vol.1 & Vol.2) pg 230-231