

See discussions, stats, and author profiles for this publication at: <https://www.researchgate.net/publication/310900273>

HBO Therapy in Global Cerebral Ischemia/Anoxia and Coma

Chapter · November 2017

DOI: 10.1007/978-3-319-47140-2_20

CITATIONS

14

READS

35

1 author:



Paul G Harch

Louisiana State University Health Sciences Center New Orleans

36 PUBLICATIONS 441 CITATIONS

SEE PROFILE

Paul G. Harch

Abstract

Hyperbaric oxygen (HBO) therapy has been used in a number of conditions characterized by global ischemia (as opposed to focal ischemia of stroke), and anoxia, and leading to impairment of consciousness. Conditions such as coma due to brain injury and anoxia associated with drowning and hanging are discussed under the following headings: (1) pathophysiology, (2) rational basis of HBO therapy, (3) review of animal experimental studies, and (4) review of human clinical studies. Finally case studies are given.

Keywords

Brain injury • Cerebral anoxia • Cerebral hypoxia • Cerebral ischemia • Coma • Global ischemia/anoxia • Hyperbaric oxygen (HBO) • Impairment of consciousness

Introduction

For a discussion of the effectiveness of hyperbaric oxygen (HBO) therapy in global cerebral ischemia/anoxia and coma, we define HBO as a medical treatment that uses increased atmospheric pressure and increased oxygen as drugs by fully enclosing a person or animal in a pressure vessel and then adjusting the dose of the drugs to treat pathophysiologic processes of the diseases. Like all drugs, the dose of HBO is crucial and should be customized to each patient's response. It is dictated by the pathological target and is determined by the amount of increase in pressure and pressure of oxygen above ambient pressure and oxygen pressure (Harch 2013), duration of exposure, frequency, total number of treatments, and timing of the dose in the course of the disease. As diseases and their pathologies evolve, different doses of HBO are required at different times. In addition, patients have

individual susceptibilities to drugs and manifest side effects and toxicity. Unfortunately, due to the lack of dosing tools, the ideal dose of HBO for an individual patient in acute or chronic global ischemia/anoxia and coma is unknown. The studies reviewed later suggest higher pressures (2 ATA or higher) and lesser numbers of treatments very early in the disease process whereas lower pressures (2 ATA or lower) and a greater number of treatments have been used as the brain injury matures. While this general trend seems justified, the absolute or effective pressures delivered to the patients in these reports may be slightly less than what is stated since many studies do not specify the HBO delivery system that was employed. For example, an oxygen pressurized chamber has an effective HBO pressure equal to the plateau pressure administered during the treatment, whereas an air pressurized chamber in which oxygen is administered by aviators mask can achieve a far lower effective HBO pressure, depending on the fit of the mask and the amount of its air/oxygen leak. In the later cases, the dose of oxygen is less. This concept is particularly important when analyzing the studies in this chapter performed prior to the late 1980s when the aviator mask dominated delivery systems in multiplace chambers.

In reviewing the data in this chapter, it is surprising that HBO has not enjoyed widespread use for neurological diseases

P.G. Harch, MD (✉)
Department of Medicine, Section of Emergency and Hyperbaric
Medicine, University Medical Center, Louisiana Children's
Medical Center, 2000 Canal Boulevard, New Orleans,
LA 70112, USA

Louisiana State University School of Medicine,
New Orleans, LA, USA
e-mail: paulharchmd@gmail.com

in the United States. This has been partly due to institutional reservations and overt therapeutic nihilism for neurological injuries, both of which are presently waning. To assume that HBO could have efficacy and benefit when liberally applied to various “accepted” indications which are more appropriately defined as “typically reimbursed,” yet have none in the great majority of neurological conditions, is perplexing. After all, the brain is enclosed within the same body in the same pressure vessel and is exposed to the same elevated oxygen and atmospheric pressure. To justify this distinction, one would have to postulate an entire set of pathophysiological HBO-insensitive brain processes that are distinctly different from those in the rest of the body’s HBO-sensitive organ systems to which we routinely apply HBO. This is illogical and unlikely. Such reasoning is indefensible when one considers the “typically reimbursed” neurological indications include carbon monoxide poisoning, brain decompression sickness, cerebral air embolism, brain abscess, and cyanide poisoning. We conclude that HBO should benefit other hypoxic/ischemic conditions of the brain, provided the dose is correct, i.e., target specific.

Other reasons for nonrecognition of HBO in neurological conditions concern methodologies. The standard for proof in scientific medicine has been the randomized prospective controlled double-blinded clinical trial. While some of the studies in this chapter meet this rigor (except for double blinding), many do not. Some are randomized, prospective, and controlled and thus exceed the quality of studies used to sanction reimbursement for most HBO indications in the United States. Other studies are uncontrolled series, case-controlled, or individual cases. Case-controlled series with chronic neurological maladies make powerful statements of efficacy from the statistical (Glantz 1992) and logical perspectives where the counterargument of placebo effect is minimized (Kienle and Kiene 1996). Furthermore, reviews of treatment effects in randomized controlled trials vs. observational studies with control groups have shown no quantitative or qualitative difference (Benson and Hartz 2000; Concato et al. 2000). All of this clinical data, in conjunction with the animal data, makes a strong case for at least attempting HBO in what are otherwise untreatable conditions with debilitating, tragic, and expensive outcomes, especially when the visual medium is used to prove single-case causality (Kiene and von Schön-Angerer 1998; Harch et al. 1996a). If these considerations are kept in mind when analyzing this chapter, it appears that the bulk of data is solidly in favor of a beneficial effect of HBO in global ischemia/anoxia and coma.

Pathophysiology

The effect of global ischemia/hypoxia on the brain has been discussed in Chap. 5. Oxidation of glucose is the primary energy source for the brain. Deprivation of oxygen causes deep psychological unresponsiveness in patients while glu-

cose and energy stores take a few minutes to exhaust (Plum and Pulsinelli 1986). Global deprivation of oxygen delivery can be achieved by reduction in blood flow (ischemia), oxygen (hypoxia/anoxia), or both (hypoxic or anoxic ischemia). Hypoxia to even an extreme degree can be tolerated for some time (mountain climbers), but ischemia cannot (Schmidt-Kastner 2015). It appears that the combination of reduction in both oxygen and blood metabolic substrates is critically injurious. Since the insult, oxygen deprivation is similar whether by lowered blood flow or oxygen content the two are often considered as a single type of insult and this concept will be followed in this chapter.

Complete global brain ischemia/anoxia is a severe transient insult to the brain best exemplified by cardiac arrest. It causes a stereotypic pathophysiology characterized by reperfusion hyperemia followed by progressive ischemia which is often heterogeneous (Safar 1986; Dirnagl 1993). The extent and pattern of injury is governed by a complex interplay of systemic and local respiratory, electrical, biochemical, and circulatory factors and selective vulnerability of cells (Myers 1979). Selective vulnerability of the CA1 hippocampal cells is a primary finding in complete global ischemia and is felt to be due to both intrinsic neuronal factors and hippocampal vascular features (Schmidt-Kastner 2015).

Most animal models of global brain ischemia/anoxia are not complete. Five models of global ischemia are commonly used in experimental work: (1) four vessel occlusion in rats, (2) two vessel occlusion with severe hypotension in rats, (3) two vessel occlusion in the gerbil, (4) two vessel occlusion combined with other insults in mice, and (5) and cardiac arrest in mice or rats (Schmidt-Kastner 2015). Two additional models are included in this chapter, a model commonly used for cerebral palsy (Rice et al. 1981), unilateral common carotid artery occlusion followed by 8% systemic hypoxia, and a birth asphyxia model whereby a pregnant uterus is harvested from a rat (Bjelke et al. 1991). Only the first and seventh models are complete; the others result in about 5% residual blood flow to the forebrain. The brainstem is usually not affected. Because of the differences in the various models findings in each study are difficult to generalize to other models and clinical syndromes.

The different models of global ischemia, especially the five incomplete models, result in differing severities of ischemia/hypoxia for differing periods of time that are differentially distributed to various regions of the brain. The primary insult of severe reduction in blood flow causes the depletion of ATP, failure of membrane ion pumps, cell swelling, and finally necrosis (Borgens and Liu-Snyder 2012). This is typified by the core or umbra in the focal ischemia model of stroke. Secondary injury then ensues with an early electrical repolarization injury (Borgens and Snyder 2012) followed by the inflammatory process, a component of which is reperfusion injury (Pundik et al.

2012). Lesser degrees of ischemia/hypoxia and ATP depletion appear to primarily affect the mitochondria, especially during the reperfusion period, where mitochondrial membrane hyperpolarization causes a burst of reactive oxygen species that launches apoptotic cascades through intracellular signaling mechanisms (Sanderson et al. 2013). This is typified by the penumbra in an ischemic stroke (Sanderson et al. 2013). Still lesser degrees of ischemia/hypoxia stimulate gene responses that are neuroprotective (preconditioning) for subsequent more severe ischemic/hypoxic insults (Bai and Lyden 2015). Due to the heterogeneity and distribution of the ischemic/hypoxic insult all of these processes are involved simultaneously with evidence of crosstalk between the processes leading to cell death along a spectrum between necrosis and apoptosis (Sanderson et al. 2013). Idiosyncratic features of a given patient's brain insult (near drowning without arrest, with arrest, vs. no arrest and prolonged low hypotension and hypoxia vs., etc.) combine with idiosyncratic vascular anatomical features, genetic factors, and the above degrees of ischemia and hypoxia to manifest heterogeneous brain injuries.

Superimposed upon this complexity is inflammation (Kunz et al. 2010; Iadecola and Anrather 2011) and variable activation of the microcirculation, common components of reperfusion injury and the secondary injury process. During ischemia there is injury to the vascular endothelium and blood-brain barrier which exposes the subendothelial extracellular matrix (Bai and Lyden 2015). Platelets, leukocytes, complement, pericytes, astrocytes, and microglia are all activated leading to postischemic hypoperfusion (Bai and Lyden 2015). The inflammatory process changes over months to years with infiltration of different cell types that elaborate different bioactive proteins. These proteins mediate multiple degradatory and repair processes. Accordingly, therapies must be highly specific in time and space (Borgens and Snyder 2012), thus explaining the failure of nearly all clinical therapeutic trials. The only therapy with broad effects on the immune system (Rossignol 2007) and widespread genomic activation of anti-inflammatory genes and suppression of pro-inflammatory genes is hyperbaric oxygen therapy (Godman et al. 2009).

Coma, on the other hand, is a neurological state resulting from a wide variety of cerebral insults that is caused by diffuse disruption (functional or anatomical) of the bilateral cerebral cortices, proximal brainstem (reticular activating system), or both (Rossor 1993). Coma is characterized by an alteration in the level of awakesness, ranges from mild somnolence to deep coma, and is graded on a number of scales, the best known of which is the Glasgow Coma Scale (Teasdale and Jennett 1974). In the studies reviewed later, coma usually refers to the more severe end of the continuum: unresponsiveness, posturing, and neurovegetative signs, however, a number of studies are unclear about the exact level of coma.

Rational Basis of HBO Therapy

HBO in acute global ischemia/anoxia is complicated by a lack of knowledge of the exact pathological targets and their oxygen sensitivity. It has been postulated that postischemic hypoperfusion may be a neurogenic reflex (Dirnagl 1993) and/or characterized by a block in the transduction of physiologic stimuli and hence protein synthesis (Siesjö et al. 1995). Assuming short-lived (minutes) global ischemia/anoxia and cell death independent of the microcirculation (Dirnagl 1993), positive effects of HBO acutely are shown later in multiple studies to be due to reversal of hypoxia and effects on cellular energy metabolism, mitochondria, ion homeostasis, membrane integrity, gene induction, and a plethora of as yet unidentified targets. The dramatic effect of even one HBO exposure on recovery of brain function, as indicated in many of the studies later, implies a powerful on/off drug effect that simultaneously quenches a degradative process and energizes the cell. It is easy to envision HBO acting at some or multiple points of blockade in the above-mentioned reflex or at a physiologic impasse.

One of the primary sites of action of HBO appears to be pressure and oxygen-sensitive genes and gene products (Harch 2015). In the chronic state, a single HBO may be responsible for the awakening of idling neurons (Neubauer et al. 1990), and when delivered both singly and repetitively considered a signal transducer (Siddiqui et al. 1995). The signal transduction mechanism is inferred in multiple noncerebral HBO wound models where trophic tissue changes result from repetitive HBO (Hyperbaric Oxygen Therapy Indications 2014), measured molecularly in two studies (Wu and Mustoe 1995; Buras et al. 2000), suggested in a replicated chronic traumatic brain injury rat model (Harch and Kriedt 2007), reaffirmed in a controlled human trial of HBO in chronic traumatic brain injury directed by Harch in Texas (Barrett et al. 1998), and powerfully demonstrated over the past 70 years in innumerable studies on the biological effects of increased pressure (Macdonald and Fraser 1999). In the past 15 years HBO has demonstrated up- and down-regulation of individual and mass numbers of genes with separate and overlapping clusters of gene activation determined by the different degrees of increase in both pressure and oxygen (Harch 2015; Oh et al. 2008; Chen et al. 2009a). A single exposure to human endothelial cells at 2.4 ATA effects expression and suppression of 8,101 genes (Godman et al. 2009). In the rat model of HBOT and chronic traumatic brain injury repetitive 1.5 ATA/90 min HBOT induced increased blood vessel density and cognitive function in injured hippocampus. While not measured, this trophism strongly implies gene activation effects of HBOT. Moreover, these findings likely underpin much of the trophic effect of HBOT in chronic brain injury and represent the first ever

improvement of chronic brain injury in animals. Future studies should be focused on elucidating the molecular effects of HBO in this model and in global cerebral ischemia/anoxia.

With prolongation of global ischemia/anoxia, and especially incomplete global ischemia, or the recovery phase of reperfusion pretherapeutic intervention the microcirculation is disturbed (Dirnagl 1993; Kunz et al. 2010) and the pathophysiology begins to resemble that in acute traumatic brain injury (Cormio et al. 1997; Kunz et al. 2010): lipid peroxidation, edema, arterial spasm, cellular reperfusion injury, and anaerobic metabolism in the setting of penumbral lesions (Cormio et al. 1997). HBO has been shown to have positive effects on all of these: ischemic penumbra (Neubauer et al. 1990; Neubauer and James 1998; Barrett et al. 1998), cerebral edema (Sukoff and Ragatz 1982), arterial spasm (Kohshi et al. 1993; Kawamura et al. 1988), anaerobic metabolism (Holbach et al. 1977a), and peroxidation/cellular reperfusion injury (Thom 1993a). This last HBO sensitive pathophysiological target is most exciting since it seems to be a generic ischemic model-, species-, and organ-independent HBO effect (Harch 2000; Buras and Reenstra 2007). In a carbon monoxide rat model Thom (1993b) showed a powerful inhibitory action of HBO on white blood cell mediated brain lipid peroxidation when delivered 24 h before the poisoning or 45 min after removal from carbon monoxide. Zamboni et al. (1993) demonstrated a similar finding in a four hour global ischemic rat gracilis muscle model, using intravital microscopy. Follow-up work by (Khiabani et al. 2008) identified a plasma mediator(s) of this phenomenon.

HBO inhibition of WBCs is also inferred in brain decompression sickness and cerebral air embolism (Harch 1996) when one combines the Dutka et al. (1989), Helps and Gorman (1991) and Martin and Thom (2002) data, which implicates WBCs in the pathogenesis of these disorders, with the Thalmann (1990) review, which shows a 90% single treatment cure rate in decompression sickness when hyperbaric recompression is delivered within the first 1–2 h of injury. Similarly, the data of Bulkley and Hutchins (1977) and Engler et al. (1986a, b) that document a WBC-mediated pathogenesis in cardiac reperfusion injury, in conjunction with the Thomas et al. (1990) tissue plasminogen activator/HBO/acute myocardial infarction dog model and the congruent human study of Shandling et al. (1997) strongly suggest an HBO-directed action on cellular reperfusion injury, among other effects. Lastly, Rosenthal et al. (2003) demonstrated a positive effect on the microcirculation similar to the findings of Zamboni et al. (1993). The beneficial effect of HBOT in most, if not all, of these studies is thought to be due to HBOT effects on endothelial-neutrophil interactions (Buras and Reenstra 2007). All of the earlier actions of HBO on the pathophysiology in acute traumatic brain injury should sum to provide a beneficial effect. In fact, such is the case as a review of the studies in

Table 20.2 shows a convincing argument for the use of HBO in acute severe traumatic brain injury. Similarly, if global ischemia/anoxia is prolonged or incomplete, e.g., unsuccessful hanging, microcirculatory disturbances are incomplete. Under these circumstances, HBO-induced inhibition of cellular reperfusion injury may partly explain the very positive results of the studies listed in Tables 20.1 and 20.2.

For HBO to be effective in coma it must be directed at diffuse targets in the bilateral hemispheric gray and white matter, the brainstem, or both. Acutely, regardless of the nature of the targets, e.g., microcirculatory, nonvascular, cellular, or other, HBO can conceivably act equally effectively on the hemispheres, brainstem, or both, and likely does. As the pathology matures, a significant HBO effect on hemispheric coma is very unlikely because of the large tissue volumes and low ratios of umbra to penumbra. Smaller tissue volumes are favored such that brainstem coma would be expected to have better results. This is suggested by the positive HBO data in the large traumatic mid-brain report of Holbach et al. (1974), the brainstem contusion subgroup of Artru et al. (1976a), the GCS 4–6 group of Rockswold et al. (1992, 2013), and the coma patients of Heyman et al. (1966) and Neubauer (1985). In all of these clinical trials, a recovery of just a few millimeters of reticular activating system can translate into far-reaching effects in the hemispheres, e.g., awakening. Additional work will be necessary to confirm this hypothesis.

In chronic global ischemia/anoxia and coma the pathological targets become more speculative. The ischemic penumbra (Astrup et al. 1981) argument of (Neubauer et al. 1990) and sympathetic hibernating myocardium concept of (Swift et al. 1992) remain, but given the numbers of treatments reported later the element of time enters the equation and implies a trophic effect. This effect, which could include stimulation of axon sprouting, or possibly an alteration or redirection of blood flow as suggested earlier (Harch et al. 2007), or both, may be indiscriminately effective on the final common pathway of a variety of brain injuries similar to HBOT's generic effect on reperfusion injury (Harch 2000). Given the diversity of reports (Neubauer 1985; Neubauer et al. 1990, 1992, Neubauer 1995, Neubauer et al. 1998, Neubauer et al. 2004, Neubauer and James 1998; Harch et al. 1994a, b; Harch 1996; Harch and Neubauer 1999, 2004) and the multitude of studies listed later this maybe so. Regardless of the nature of this generic effect, in the past 29 years (PGH) and 38 years (RAN) these authors have noted an upward sawtooth response (Chap. 19, Stroke, Figs. 19.7 and 19.9) during HBOT in subacute and chronic brain injury with a partial regression once each round of HBOT ends. This implies permanent and transient components to the treatment (see Chap. 44, Neuroimaging). While the net HBO result appears uniform, the biochemical, molecular, cellular, and anatomic complexities of the transient, permanent, and final effects will need to be developed in the future.

Table 20.1 Hyperbaric oxygen therapy in global ischemia, anoxia, and coma — animal studies

Authors and year	Model	Animal species	Length of ischemia/anoxia	Initiation of HBO	HBO protocol	Results and conclusions
Moody et al. (1970)	Temporary complete global ischemia/anoxia using bilateral extradural balloons	50 dogs (20 controls)	Flattening of EEG for 3 min plus spontaneously rising intracranial pressure to equal systolic blood pressure. Evaluation after 10 days	Immediately after balloon deflation	Group 1: Controls 1 ATA air, spontaneous respiration Group 2: 1 ATA O ₂ /4 h on a ventilator Group 3: 1 ATA O ₂ /4 h, spontaneous respiration, no ventilator Group 4: 2 ATA O ₂ /4 h, spontaneous respiration, no vent	Group 1: 95% mortality within 30 h after ischemia Group 2: 30% mortality Group 3: 70% mortality within 72–96 h after ischemia Group 4: 50% mortality within 72–96 h after ischemia Quality of survivors was poor in Group 2 and good in Groups 3 and 4
Kapp et al. (1982)	Temporary complete global ischemia/anoxia. Total circulatory arrest with occlusion of aorta, superior vena cava, and inferior vena cava	10 cats	5 min	3–5 min after ischemia release	Group 1: 5 controls, 1 ATA O ₂ /2.5 h Group 2: 5 HBO, 1.5 ATA O ₂ /2.5 h	Beneficial effect of HBOT with significant reduction in EEG recovery time
Ruiz et al. (1986)	Temporary complete global ischemia/anoxia. Ventricular fibrillation and no ventilation for 12 min then cardiac resuscitation. Evaluate survival times, cardiac function, and neurological scoring 7 days postarrest	16 dogs	12 min	Approximately 13 min after end of arrest (resuscitation within 6 min + 7 min of hemodilution)	Group 1: Controls No treatment Group 2: Normovolemic hemodilution with hetastarch/MgSO ₄ to hematocrit of 20–30% Group 3: Group 2: plus 2 ATA O ₂ /1 h	No significant difference in survival, cardiac function, or neurological scoring between control and HBO. Decreased hematocrit due to hemodilution felt to possibly be detrimental
Shiokawa et al. (1986)	Permanent incomplete global ischemia/anoxia. Bilateral carotid artery ligation. Measure survival times and lactate/ATP	60 spontaneously hypertensive rats	1.5 or 3.5 h for survival experiment, 2.5 or 4.5 h for metabolic studies	At 1 h or 3 h postligation	Group 1: (Survival) (a) 1 ATA air/1.5 h (b) 1 ATA air/3.5 h (c) 2 ATA O ₂ /30 min at 1 h postligation (d) 2 ATA O ₂ /30 min at 3 h postligation Group 2: (Metabolic) Same as for survival experiment but assays at 2.5 (a and c) and 4.5 h (b and d) of ligation	All HBOT animals survived at least 1.5 or 3.5 h. Control animals that died in less than these times were excluded from analysis Animals with HBOT at 3 h survived significantly longer than controls with significantly less lactate accumulation. Trend toward more ATP accumulation in HBO Group D

(continued)

Table 20.1 (continued)

Authors and year	Model	Animal species	Length of ischemia/anoxia	Initiation of HBO	HBO protocol	Results and conclusions
Weinstein et al. (1986)	Temporary incomplete global ischemia/anoxia. Permanent unilateral carotid occlusion Temporary opposite carotid artery occlusion for 2, 5, 10, 20, or 60 min. Autopsy studies. Separate DMSO experiment	30 gerbils	2, 5, 10, 20, or 60 min	After 20 min of temporary occlusion	Group 1: Controls at 2, 5, 10, 20, or 60 min with bilateral carotid artery occlusion Group 2: HBO 1.5 ATA/15 min after 20 min of occlusion Group 3: Intraperitoneal DMSO at 5 or 10 min of bilateral occlusion Group 4: Controls-surgery without carotid occlusion	Mortality: Group 1: 2 min 0%, 5 min 33%, 10 min 33%, 20 min 100%, 60 min 100% Group 2: HBO 16% (p < .001) Extent of damage much less in HBO survivors Group 3: DMSO 86% mortality each
Van Meter et al. (1988)	Temporary complete global ischemia/cardiac arrest. Measured return of cardiac function by EKG and thermodilution cardiac output	Guinea pig	15 min	Immediately after 15-min arrest period	Group 1: Control. 1, 2.8 or 6 ATA air/maximum 30 min Group 2: HBOT at 1, 2.8, or 6 ATA oxygen/30 min maximum	Maximum initial postresuscitation survival at 2.8 ATA O ₂ >6 ATA air or 6 ATA O ₂ , maximum mean postresuscitation survival time with 6 ATA O ₂ >2.8 ATA O ₂ >1 ATA O ₂ >6 ATA air
Mickel et al. (1990)	Temporary incomplete global ischemia. Bilateral carotid artery occlusion. Histological evaluation at death or up to 28-day limit	60 gerbils	15 min	None	Group 1: 1 ATA O ₂ /first 3 h of reperfusion Group 2: 1 ATA air for 3 h of reperfusion	In the oxygen group: (1) Increased myelin damage, but better preservation of axons (2) Better preservation of neurons in the deeper laminae of the cerebral cortex (3) Increased mortality
Yatsuzuka (1991)	Temporary complete global ischemia. Cross clamp of ascending aorta. Measure intracranial pressure, cerebral blood flow, EEG, and oxidative stress (metabolites) before, during, and after HBO 34 dogs	34 dogs	18 min	60 min postischemic release	Group 1: Ischemic controls Group 2: HBOT without global ischemia Group 3: HBO 2 ATA/170 min	Significant decrease in intracranial pressure and oxidative stress metabolites in HBOT
Grigor'eva et al. (1992)	Permanent incomplete global ischemia. Bilateral carotid artery occlusion. Survival and histology measurements of cortical neurons	Approximately 60 rats	24 h	2 h after occlusion	Group 1: HBOT 2 ATA/1 h Group 2: Air 2 ATA/1 h Group 3: HBOT 1.2 ATA/30 min Group 4: Controls, sham, operation, sacrifice at 2.5 h Group 5: Controls, operation, air treatment, sacrifice at 2.5 h	At 24 h: Group 1: 30% survival with 25–30% sparing of neurons Group 2: 50% spared neurons (did not mark mortality) Group 3: 50% survival with 50–60% sparing of neurons Group 4: Used for baseline histologic studies Group 5: 100% mortality, when allowed to proceed to 24 h Pronounced protective effect in HBO groups with preservation of transcription and increased survival; 1.2 ATA was superior to 2 ATA

Takahashi et al. (1992)	Temporary complete global ischemia/anoxia. Occlusion of the ascending aorta and caval veins. EEG and neurological recovery scores measured over a period of 14 days postischemia	19 dogs	15 min	3, 24, and 29 h after release of ischemia	Group 1: 3 ATA O ₂ /1 h at 3, 24, and 29 h Group 2: Controls air 1 ATA	Survival: 30 % in control group 78 % in hyperbaric group with significantly greater EEG and neurological recovery scores
Iwatsuki et al. (1994)	Temporary complete global ischemia. Same model as Takahashi's study	19 dogs	15 min	3, 24, and 29 h after release of ischemia	Group 1: nicardipine bolus immediately at the end of ischemia then nicardipine drip × 3 days plus HBOT—3 ATA/1 h at 3, 24, and 29 h after ischemia Group 2: no nicardipine or HBOT	Survival rate and time, neurological recovery, and EEG scores all significantly better in HBOT/nicardipine group
Mink and Dutka (1995a)	Temporary complete global ischemia. CSF infusions to increase intracranial pressure to mean arterial pressure Measure cortical somatosensory-evoked potentials and oxyradical brain damage	18 rabbits	10 min	Immediately on reperfusion	Group 1: 1 ATA air for 75 min Group 2: 2.8 ATA O ₂ /75 min with air breaks	HBOT significantly increased evoked potentials and free radical generation but lipid peroxidation was unchanged
Mink and Dutka (1995b)	Same model as above 10 min 30 min after the end of ischemia	22 rabbits	10 min	30 min after the end of ischemia. On room air during the 30 min	Group 1: 2.8 ATA O ₂ /125 min with air breaks then 1 ATA O ₂ /90 min Group 2: Control 1 ATA O ₂ /215 min	HBO significantly reduced brain vascular permeability and blood flow while somatosensory-evoked potentials were unchanged
Yaxi et al. (1995)	Temporary incomplete global ischemia Temporary clamping of bilateral common carotid arteries (CCA) plus (?) internal jugular veins Histochemical analysis of LDH, isocitrate dehydrogenase: (ICD H), cytochrome a ₃ , ATPase, and cAMP. Also pathological study of tissue	52 rabbits	20 min (?)	Immediately after release of clamp	Group 1: Control. Room air × 20, 40, or 120 min Group 2: (HBA-hyperbaric air): 8.4 % O ₂ at 2.5 ATA/20, 40, or 120 min Group 3: HBOT at 2.5 ATA (by "mask")/20, 40, or 120 min. Tissue analysis immediately posthyperbaric treatment	Improvement in LDH, ICDH, cytochrome a ₃ , and ATPase levels in 40 and 120-min HBO groups with concomitant reduced tissue injury on pathological examination

(continued)

Table 20.1 (continued)

Authors and year	Model	Animal species	Length of ischemia/anoxia	Initiation of HBO	HBO protocol	Results and conclusions
Yiqun et al. (1995)	Temporary incomplete global cerebral ischemia. Bilateral common carotid artery (CCA) clamping. Measured Na, K-ATPase activity in groups 1, 2, 3, 4, and 5 and histologic and electron microscope analysis in groups 1, 2, and 4	98 gerbils	60 min (?)	Immediately after treatment	Group 1: Control. Skin incision only Group 2: Control CCA clamping plus 80-min. room air exposure Group 3: CCA clamping plus 1 ATA ₂ /80 min Group 4: CCA clamping plus 2.5 ATA O ₂ /80 min Group 5: CCA clamping plus 2.5 ATA air/80 min Group 6: CCA clamping plus immediate sacrifice	Significant decrease ATPase activity in all groups except group 4 HBO. Least pathological changes in same group
Konda et al. (1996)	Temporary incomplete global ischemia/anoxia. Bilateral common carotid artery ligation. Histological exam of hippocampal neurons 3 weeks post-op and histochemical examination of heat shock proteins 36 h post-op	47 gerbils	10 min	2, 6, or 24 h post-op.	Group 1: 6 h posts ischemia: 2 ATA ₂ /60 min t.i.d. × 7 days, then q.d. × 14 Group 2: 24 h posts ischemia: 2 ATA ₂ /60 min 1 × day/14 days Group 3: surgery, no HBO Group 4: 2 ATA O ₂ /60 min 1 × day for 14 days. No surgery Group 5: No HBO, no surgery. Sacrifice at 36 h. Group 6: Surgery, single HBO 2 ATA/60 at 2 h post-op Group 7: Surgery, single HBO at 2 ATA/60 min 24 h post-op Group 8: Surgery, no HBO	Preservation of hippocampal neurons in HBO animals (6 h animals > than 24 h animals) with less heat shock protein induction in HBO animals than controls. Increase in lysosomes and myelinoid structures in hippocampal neurons in HBO group HBO prevented delayed neuronal death without oxygen toxicity
Wada et al. (1996)	Temporary incomplete global ischemia/anoxia, bilateral common carotid artery occlusion Evaluate neuronal density 7 days posts ischemia and heat shock protein production in the hippocampus	49 gerbils	5 min (2 days after last HBOT)	Preischemia	Group 1: 2 ATA O ₂ /1 h × 1 treatment Group 2: 2 ATA O ₂ /1 h every other day × 5 treatments Group 3: Sham operation, no HBO Group 4: Surgery, no HBO Group 5: Groups 1, 2, and 3 without ischemia; measurement of heat shock proteins	Significant preservation of neurons in the 5 HBO pretreatment group with significant increase in heat shock protein production Repetitive HBOT protects against ischemia neuronal damage possibly through heat shock protein induction
Krakovsky et al. (1998)	Temporary complete global ischemia (cauterization of bilateral vertebral arteries then temporary occlusion of the bilateral common carotid arteries). Measure brain blood flow by direct laser/Doppler flowmetry and 14-day survival	18 rats	60 min	"Brief delay to transfer to HBO chamber"	Group 1: Control. Room air Group 2: HBOT: 3 ATA/1 h	Significantly increased survival in HBO (45%) vs. controls (0%). In <14-day survival, significant increase in survival time with HBO (59.8 h) vs. controls (17.9 h)

Van Meter et al. (1999b)	Temporary complete global ischemia/cardiac arrest. Measure initial return of circulation with BP >90/50 and sustained circulation for 2 h	36 swine	25 min	Immediately after the 25-min arrest period	Group 1: Control. 1 ATA O ₂ /maximum 30 min Group 2: 2 ATA O ₂ /maximum 30 min Group 3: 4 ATA O ₂ /maximum 30 min	Initial return of circulation and sustained return of circulation at 2 h only present in group 3; 4 ATA HBOT groups at 80% and 67%, respectively. All animals in all other groups failed to be resuscitated
Hai et al. (2002)	Temporary incomplete global ischemia/hypoxia (?) Right common carotid artery, internal carotid artery, and external carotid artery ligation (?) then 5.5% oxygen environment (same model as Calvert et al. 2002 study). Measure brain fibroblastic growth factor (bFGF) and bFGF mRNA after ten-day treatment period	44 rats (<7 days old)	2 h	7 days	Group 1: Control Room air for 10 days Group 2: HBOT 2.5 ATA/90 min q.d. x 10 Group 3: HBA (hyperbaric air) 2.5 ATA/90 min q.d. x 10 ("concentrations oxygen controlled under 25%") Group 4: "Untreated": "Free growing x 10 days" Group 5: Sham operation	Increased bFGF levels in HBA and HBO groups, especially in precortex and hippocampus. Increased bFGF mRNA only in HBO group
Van Meter et al. (2001a)	Temporary complete global ischemia/cardiac arrest. Measure initial return of circulation with BP >90/50 and sustained circulation for 2 h. Measure malondialdehyde	36 swine	25 min	Immediately after the 25-min arrest period	Group 1: Control. 1 ATA O ₂ /maximum 30 min Group 2: 2 ATA O ₂ /maximum 30 min Group 3: 4 ATA O ₂ /maximum 30 min	Significant reduction in brain lipid peroxidation in 4 ATA HBOT group only
Van Meter et al. (2001b)	Temporary complete global ischemia/cardiac arrest. Measure initial return of circulation with BP >90/50 and sustained circulation for 2 h. Measure myeloperoxidase content	36 swine	25 min	Immediately after the 25-min arrest period	Group 1: Control. 1 ATA O ₂ /maximum 30 min Group 2: 2 ATA O ₂ /maximum 30 min Group 3: 4 ATA O ₂ /maximum 30 min	No effect of any treatment group on myeloperoxidase content Implies the target of ischemia reperfusion injury reduction with HBOT in this model is not leukocytes
Calvert et al. (2002)	Temporary incomplete global ischemia. Right common carotid artery ligation then 8% oxygen exposure. Measure brain weights and examine with light microscopy and electron microscopy at 24, 48, and 72 h., and 1, 2, and 6 weeks, and perform sensory motor functional test 5 weeks posthypoxia	229 rats (7 days old)	2½ h of hypoxia post-2 h carotid ligation	1 h after hypoxia	Group 1: Control Group 2: Ischemia/hypoxia plus room air recovery Group 3: HBOT 3 ATA/60 min	Significant preservation of brain weight in the right hemisphere of HBO rats at 2 and 6 weeks with less atrophy and apoptosis on light and electron microscopy. Sensory motor function also significantly improved at 5 weeks in HBO group

(continued)

Table 20.1 (continued)

Authors and year	Model	Animal species	Length of ischemia/anoxia	Initiation of HBO	HBO protocol	Results and conclusions
Rosenthal et al. (2003)	Temporary complete global ischemia (cardiac arrest/resuscitation). Measure neurological deficit score 23 h after resuscitation, sacrifice at 24 h and measure apoptosis in hippocampus and cerebral neocortex, arterial and sagittal sinus oxygenation and cerebral blood flow (CBF), cerebral oxygen extraction ratio (ERC), oxygen delivery (DO_2c), and metabolic rate for oxygen ($CMRO_2$) at baseline, 2, 30, 60, 120, 180, 240, 300, and 360 min after restoration of spontaneous circulation	20 dogs	1 h	1 h	Group 1: Control Room air resuscitation Group 2: HBO 2.7 ATA/60 min	Improvement in neurological deficit score in HBO group with significantly fewer dying neurons. Magnitude of neuronal injury correlated with the neurodeficit score. HBO decreased the oxygen extraction ratio without a change in oxygen delivery or $CMRO_2$
Zhou et al. (2003)	Temporary complete global ischemia. Bilateral carotid occlusion. Measure Nogo-A, Ng-R, and RhoA proteins at 6, 12, 24, 48, 96 h, and 7 days	78 rats	10 min	1 h after ischemia	3ATA/2 h. Thirteen groups: 1 sham, 6 global ischemia, 6 global ischemia + HBO	HBO significantly reduced neurological injury (neuronal loss) and the levels of Nogo-A, Ng-R, and RhoA in injured cortex
Mrsic-Pelcic et al. (2004a)	Temporary complete global ischemia (vertebral cautery + transient bilateral carotid occlusion). Measure hippocampal SOD or Na, K ATPase	84 rats	20 min	2, 24, 48, or 168 h after ischemia (for SOD), or .5, 1, 2, 6, 24, 48, 72, or 168 h after ischemia (for ATPase)	2 ATA/1 h daily for 7 days	HBO significantly increased hippocampal SOD only when delayed 168 h and prevented ATPase decline only if begun during 1st 24 h of reperfusion
Mrsic-Pelcic et al. (2004b)	Temporary complete global ischemia (vertebral cautery + transient bilateral carotid occlusion). Measure optic nerve SOD or Na, K ATPase	84 rats	20 min	2, 24, 48, or 168 h after ischemia (for SOD), or .5, 1, 2, 6, 24, 48, 72, or 168 h after ischemia (for ATPase)	2 ATA/1 h daily for 7 days	HBO prevented ATPase decline in the optic nerve only if begun during 1st 6 h of reperfusion and no effect on SOD regardless of time of initiation
Gunther et al. (2004)	Complete global ischemia (brain slices postdecapitation). Measure purine nucleotide content and morphological changes	Rat(s)	5 or 30 min	After 5 or 30 min of anoxia	2.5 ATA/1 h, 1ATA/1 h, 2.5 ATA air/1 h, or 1 ATA air/1 h	HBO and NBO equally effective at 5 min. Less so after 30 min hypoxia while only HBO lessened morphological cell injury

Li et al. (2005)	Temporary incomplete global ischemia (bilateral common carotid occlusion + hypotension to 30–35 mmHg). Measure HIF-1 alpha, p53, caspase-9, 3, and 8, bcl-2 and cell death at 6, 12, 24, 48, 96 h, and 7 days	78 rats	10 min	1 h after ischemia	3 ATA/2 h Thirteen groups: 1 sham, 6 global ischemia, 6 global ischemia + HBO	HBO reduced HIF-1 alpha, p53, caspase 9 and 3, and apoptosis, yet increased proapoptotic caspase 8 and decreased antiapoptotic bcl-2
Calvert and Zhang (2005)	Temporary incomplete global ischemia (unilateral carotid ligation + 8% oxygen exposure). Measure ATP, creatine, phosphocreatine, glucose at 4 and 24 h. Brain weight at 2 weeks	7-day-old rat pups	2 h	1 h after ischemia	3 ATA/2 h or 1 ATA/2 h	Significant reduction of brain injury and increase in ATP, cr, Per over controls with HBO and NBO
Yu et al. (2006)	Temporary incomplete global ischemia (unilateral carotid ligation + 8% oxygen exposure). Measure neural stem cells and myelin in hippocampus at 3 weeks	7-day-old rat pups	2 h	1 h after ischemia	2 ATA/? Oxygen or air daily x 7 days	HBO increased hippocampal stem cells and nestin expression. Both HBO and hyperbaric air mitigated myelin damage
Liu et al. (2006b)	"Hypoxic/ischemic brain damage." Article in Chinese, model not described in English abstract. Measure hippocampal and cortical cell density at 48 h and neurobehavioral testing at 5 and 6 weeks	7-day-old rat pups (n = 84)	1 h	1, 3, 6, 12, or 24 h after ischemia	2.5 ATA/1.5 h at 1, 3, 6, 12, or 24 h	Neuronal density, sensorimotor, grip test, and treadmill were significantly increased over controls when HBO was delivered up to 6 h after ischemia
Liu et al. (2006a)	Temporary incomplete global ischemia (unilateral common carotid ligation + hypoxia). Measure spatial learning/memory 37 and 41 days and morphology 42 days after ischemia	7-day-old rat pups (n = 52)	2 h	.5–1 h after ischemia, daily x 2 days	2 ATA/?	HBO significantly improved spatial learning/memory and alleviated morphological and histological damage
Calvert et al. (2006)	Temporary incomplete global ischemia (unilateral carotid ligation + 8% oxygen exposure). Measure HIF-1 alpha, glucose transporter, LDH, aldolase, and p53	7-day-old rat pups	2 h	1 h after ischemia	2.5 ATA or 1 ATA oxygen	HBO >NBO significantly reduced elevated HIF-1 alpha, promoted a transient increase in glucose transporter, LDH, Ald, and decreased HIF-1 alpha-p53 interaction and expression of p53

(continued)

Table 20.1 (continued)

Authors and year	Model	Animal species	Length of ischemia/anoxia	Initiation of HBO	HBO protocol	Results and conclusions
Yang et al. (2008)	Temporary incomplete global ischemia (unilateral carotid ligation + 8% oxygen exposure). Measure hippocampal stem cells at 7 and 14 days and nestin protein and pathological changes at 28 days	7-day-old rat pups	2 h	Within 3 after ischemia	2 ATA/? daily × 7 days	HBO caused proliferation of stem cells which peaked at 7 days and migrated to the cerebral cortex at 14 days. New neurons, oligodendrocytes, and myelin basic protein was seen in the HBO group at 28 days
Wang et al. (2007a)	Temporary incomplete global ischemia: ligation left common carotid plus 8% O ₂ exposure for 2 h. Measure Wnt-3 protein expression and endogenous neural stem cell proliferation @ 6 and 24 h, 3, 7 and 14 days in subventricular zone	7-day-old rats	2 h	3 h posthypoxic insult	Group 1: Control Group 2: Hyp/Isch Group 3: Hyp/Isch + HBO (2 ATA/?; once/day × 7 days (total of 7 HBOTs)	Neural stem cells increased 3 h after HBO, peaked at 7 days and remained higher at 14 days. Wnt-3 increased 3 h post-HBOT, peaked at 3 days, remained higher at 14 days. Neural stem cells and Wnt-3 significantly correlated and increased in both hemispheres Conclusions: HBO promotes proliferation of stem cells and is correlated with Wnt signaling
Wang et al. (2007b)	Temporary incomplete global ischemia as earlier. Measure T-maze, foot-fault test, and radial arm maze test 14 days and myelin basic protein (MBP) in the callositas and corpora striata 28 days after hypoxia/ischemia	7-day-old rats	2 h	3, 6, 12, 24, or 72 h after hypoxia/ischemia and 72 h after Hyp-Isch. 2.0 ATA/?; once/day × 7 days (total of 7 HBOTs)	Group 1: Hyp-Isch Experimental Groups: 3, 6, 12, 24, and 72 h after hypoxia/ischemia 2.0 ATA/?; once/day × 7 days (total of 7 HBOTs)	Significantly better performance on all 3 behavioral tests and elevated MBP for rats with HBOT up to 12 h after Hyp-Isch Conclusion: HBO w/12 h after Hyp-Isch can alleviate white matter damage
Liu et al. (2007)	Temporary incomplete global ischemia: left common carotid ligation, then 2 h 8% O ₂ . Measure step-down inhibitory avoidance at 6 weeks; Morris Water Task and hippocampal cell density at 8 weeks	7-day-old rats (18)	2 h	1 h after hyp-ischemia	Group 1: Sham Group 2: Hyp-ischemia Group 3: HBO 2.5 ATA/1.5 h	In HBO group: significantly longer step-down and shorter latencies to reach platform, less time spent in quadrant, diminished brain injury, and decreased cell loss of hippocampal CA1 region Conclusion: HBO improves long-term learning-memory deficits and attenuates brain injury
Wang et al. (2008)	Temporary incomplete global ischemia. Left common carotid ligation then 2 h 8% O ₂ . Measure stem cells 10 days, T-maze, foot-fault, and radial arm maze tests at 14, 22, 26 days, and morphology 28 days after hypoxia/ischemia	7-day-old rats	2 h	3, 6, 12, 24, or 72 h after hypoxia/ischemia after hyp-ischemia (2.0 ATA/60 min once/day × 7 days)	Group 1: Control Group 2: Hyp-Isch Groups 3-7: HBO 3, 6, 12, 24, and 72 h after hyp-ischemia 3-12 h groups	Significantly increased stem cells in 3-24 h groups, better performance, and less neuron loss in hippocampal CA1 in 3-12 h groups Conclusion: HBO therapeutic window in HIE can be delayed up to 12 h with decreased effect up to 24 h

<p>Wang, et al. (2009)</p>	<p>Temporary incomplete global ischemia. Left common carotid ligation then 2 h 8% O₂. Measure apoptosis and neuronal cell population in cortex and CA1 of hippocampus 31 days after hypoxia/ischemia</p>	<p>7-day-old rats (88)</p>	<p>2 h</p>	<p>2, 48, 96 h after hyp-ischemia</p>	<p>Group 1: Control Group 2: Hyp-Isch Group 3: HBO, 2 h post-H-I Group 4: HBO, 48 h post-H-I Group 5: HBO, 96 h post-H-I HBO: 2 ATA/1 h, 1x/day x 7 days, 3 days res within each HBO group had 3 groups, receiving either 1 Conclusion: 1 course HBO receiving either 1 (7 HBOTs), 2 (14 HBOTs), or 3 courses (21 HBOTs)</p>	<p>Apoptosis inhibition and neuronal protection decreased with increasing delay to single course of HBO, but increased with increasing courses of HBO at 48 and 96 h after hypoxia/ischemia. The number of apoptotic cells and neurons was nearly equal in H-I and control after 1 course HBO Conclusion: 1 course HBO receiving either 1 w/1 2 h H-I can effectively inhibit apoptosis and protect neurons, but less so with delay to HBO. With delay to HBO protection can be increased with increasing number of HBOTs</p>
<p>Chen et al. (2009a)</p>	<p>Complete global isch: delayed Caesarean section model—harvest pregnant uterus from term rats, submerge in water bath for anoxia, deliver pups. Measure brainstem auditory-evoked potentials, pathological change, and number of neurons in hippocampus 4 weeks of age</p>	<p>Term rat pups (male) ? number</p>	<p>15 min</p>	<p>24 h after isch-hypox</p>	<p>Group 1: Isch-Hyp Group 2: H-I plus HBO @ 2 ATA/1 h, 1x/day x 14 days Group 3: Sham operated Group 4: Sham operated + HBO</p>	<p>HBO H-I group: shorter peak latency waves II and IV and interpeak latencies peaks I-IV, less pathological changes and more neurons in hippocampus. HBO control group more neurons than control group Conclusion: HBO improves synaptic transmission efficiency, electrophysiologic conduction velocity, and reduces neuronal death in neonatal rats with H-I injury</p>
<p>Chen et al. (2009b)</p>	<p>Temporary incomplete global ischemia: left common carotid ligation, then 2 h 8% O₂. Measure histopathological damage, Caspase-3, Nogo-A expression, Morris Water Maze in control, ephedrine, HBO, and combined HBO-ephedrine groups</p>	<p>7-day-old rats (80)</p>	<p>2 h</p>	<p>1 h after hyp-ischemia</p>	<p>Group 1: Sham operated Group 2: Hyp-Ischemia Group 3: Ephedrine Group 4: HBO Group 5: ephedrine + HBO HBO @ 2.5 ATA/2 h at depth</p>	<p>Caspase-3 and Nogo-A reduced in treatment groups, greater reduction in combined treatment group. Escape latency shorter and platform location crossings greater in combined group vs. single treatment groups Conclusion: combination treatment enhances neuroprotective effect partially by inhibiting Caspase-3 and Nogo-A pathways</p>
<p>Chen and Chen (2010)</p>	<p>Complete global isch: delayed Caesarean section model—harvest pregnant uterus from term rats, submerge in water bath for anoxia, deliver pups. Measure hippocampal ultrastructure P38 expression, and water maze test at 4 weeks of age</p>	<p>Term rat pups (male, 30)</p>	<p>15 min</p>	<p>24 h after isch-hypox</p>	<p>Group 1: Isch-Hyp Group 2: H-I plus HBO @ 2 ATA/1 h, 1x/day x 14 days Group 3: Sham operated Group 4: Sham operated + HBO</p>	<p>Water maze test, hippocampal ultrastructure, and P38 significantly better than ischemic/hypoxic group for control and HBO groups with no difference between HBO and control Conclusion: HBO induces synaptic plasticity and reduces ultrastructural damage in pernatal hypoxia/ischemia</p>

(continued)

Table 20.1 (continued)

Authors and year	Model	Animal species	Length of ischemia/anoxia	Initiation of HBO	HBO protocol	Results and conclusions
Liu, et al. (2013)	Temporary incomplete global ischemia: Unilateral carotid ligation, 8% O ₂ for 2 h Measure apoptosis, caspase-3, apoptosis inducing factor 60 days post and cognitive and sensorimotor tests 28–60 days postinsult	7-day-old rats (108)	2 h	1 h post-hyp-ischemia	Group 1: Sham operated Group 2: Hyp-ischemia Group 3: HBO, 2.5 ATA/90 min once	Significant cognitive and sensorimotor improvements in HBO correlated with reduction size of hippocampal and cortex lesions. HBO decreased apoptosis, caspase-3, and AIF Conclusion: HBO promoted long-term functional and histological improvement which is associated with suppression of apoptosis by inhibiting caspase-3 and AIF
Malek, et al. (2013)	Temporary Incomplete global ischemia. Bilateral temporary occlusion of both common carotid arteries. Measure hippocampal CA1 neuronal survival, brain temperature, nesting behavior in control, HBO, hyperbaric air, and normobaric oxygen groups	12–13 weeks gerbils	3 min	1,3, or 6 h after isch	Group 1: Sham Group 2: Ischemia Group 3: HBO-2.5 ATA/60 min, 1×/day × 3 Group 4: HBA, 2.5 ATA/60 min, 1×/day × 3 Group 5: 100% O ₂ 1 ATA/60 min, 1×/day × 3	HBO and HBA significantly increased neuronal survival, behavioral performance, and abolished brain temperature increase when treated 1, 3, 6 h after ischemia. HBO only effective 1 h postischemia Conclusion: HBO, HBA prevent neuronal damage primarily by pressure inhibition of brain temperature increase
Yin, et al. (2013)	Temporary incomplete global ischemia: Left common carotid ligation, 8% O ₂ for 2.5 h Measure bone morphogenetic protein-4, nestin, and their mRNA expression, and apoptosis in hippocampus 7 days after HBO	7-day-old rats (30)	2.5 h	6 h post-hyp-ischemia	Group 1: Normal Control Group 2: Hyp-ischemia Group 3: HBO, 2.0 ATA/40 min, 1×/day × seven days	BMP-4, nestin, and their mRNA expression were highest in HBO group. Number of apoptotic cells significantly lower in HBO group vs. hypox-ischemia group and higher than control Conclusion: HBO may promote neurorecovery in HIE due to increased protein and mRNA expression of BMP-4, nestin, and inhibition of apoptosis
Zhu, et al. (2015)	Temporary incomplete global ischemia: Unilateral carotid ligation, 8% O ₂ for 2 h. Measure cell density, apoptosis rate, Fas-L caspase-8, caspase-3 + cells, nitric oxide, malondialdehyde, super-oxide dismutase in hippocampus 14 days post. Morris Water Maze 28 days post-hyp-ischemia	7-day-old rats (126)	2 h	6, 24, 48, 72 h, and 1 week post	Group 1: Sham operated Group 3: 6 h HBO Group 4: 24 h HBO Group 5: 48 h HBO Group 6: 72 h HBO Group 7: 1 week HBO All HBO: 2 ATA/60 min, 1×/day × 7 days	Significant improvements cell density, apoptosis, oxidative stress, Fas-L, caspases, and Water-Maze for HBO w/ 72 h, declining in time-dependent fashion Conclusion: HBO inhibits oxidative stress and apoptosis in HIE; optimal therapeutic window is 72 h

Table 20.2 Hyperbaric oxygen therapy in global ischemia, anoxia, and coma — human studies

Authors and year	Diagnosis	No. of patients	Length of coma/neuroinsult prehyperbaric oxygen therapy (HBOT)	Timing of HBOT	HBOT protocol	Results and conclusions
Category I: Hyperacute Period (0–3 h postcerebral injury)						
Hutchison et al. (1963)	Global ischemia/anoxia. Asphyxiated neonates (apnea). No in chamber ventilator support available	65	3–38 min	3–38 min	2–4 ATA/30 × 1, 14 patients treated more than 1	79% resuscitation rate (25% died later of other causes). Overall, 55% discharged from hospital as well. Most deaths due to Hyaline membrane
Ingvar and Lassen (1965)	Coma: Progressive thrombotic CVA of the brainstem. Patient was preterminal	1	Not mentioned	At signs of failing circulation	2.0–2.5 ATA ... for 1.5–2.5 h	Rapid awakening in chamber with increase in blood pressure and decrease in heart rate. Death shortly after the end of 1 HBOT
Saltzman et al. (1966)	Various forms of cerebral ischemia. Some in coma but only 5 of 25 is level of consciousness specifically identified	25 (2 patients in coma in hyperacute or acute coma, 23 patients a few hours to 30 days after CVA)	1. 5 h 61-year-old patient with stupor and hemiplegia, suspected embolic clot. 2. 2.5 h 58-year-old with deep coma and hemiplegia, suspected air embolism	1. 5 h 2. 2.5 h	1. 2.02 ATA/>1 h, 1 treatment 2. 2.36 ATA/5 h, 1 treatment	First patient dramatic awakening 5 min into HBO with improvement of hemiplegia Discharged from hospital with mild residual deficit. Second patient dramatic awakening 10 min into HBO with improvement of hemiplegia Discharged from hospital with only partial paralysis of the right leg Remainder of patients probably described in Heyman study: 3 patients dramatic temporary improvement, 8 patients less dramatic temporary improvement, 12 patients no change during HBOT. 24 of 25 patients with only 1 treatment One patient with 3 treatments
Viaart et al. (1970)	Hepatic coma infants (2 viral, 1 toxic); HBOT plus exchange transfusions	3	Not mentioned	Not mentioned	Not mentioned, but extreme profile implied	One died of pulmonary oxygen toxicity with 36 h of HBOT, two survived. All three with normalization of consciousness, EEG, and neurological examination. (One transient, two permanent) Cardiac conduction abnormalities during HBO in the two survivors? Difficult to assess the effect of HBO; authors feel high complication rate of HBOT makes exchange transfusion standard of care

(continued)

Table 20.2 (continued)

Authors and year	Diagnosis	No. of patients	Length of coma/neuroinsult prehyperbaric oxygen therapy (HBOT)	Timing of HBOT	HBOT protocol	Results and conclusions
Hayakawa et al. (1971)	Acute coma: 9 TBI, 4 post-op brain tumor 7 patients ventilator dependent Measure CSF pressure pre, during, and post-one HBOT	13	Acute posttrauma and immediately post-op. Exact time not mentioned	Acute posttrauma and immediately post-op. Exact time not mentioned	2 ATA/1 h x 1	Three patterns of response: (1) 9 patients: CSF pressure decreased at beginning of HBOT and rose at end of HBOT (2) 2 patients: CSF pressure decreased with HBO and remained significantly lower at end of HBOT (3) 2 patients: no change in CSF pressure Conclusion: HBOT has two actions, decreases edema in injured brain and produces edema in normal brain. If HBOT produced significant change in CSF pressure, clinical improvement was remarkable and neurological deficit was mild. If no change CSF pressure with HBOT, severe brain damage and little clinical improvement
Voisin et al. (1973)	Global ischemia/anoxia/coma: Near hanging	35 (33 by suicide attempt)	14 controls with normobaric oxygen (NBO) prior to installation of HBO chamber in 1968	(2/3 of cases: <3 h from discovery to hospitalization	Exact timing not stated	(1) HBO 2 ATA/1 h x 1 or more Rxs. Total 51 Rxs in 35 patients (2) Control: NBO
Larcan et al. (1977)	Coma: Thrombotic CVA (HBOT + Urokinase)	77 (36 in varying degrees of coma, 10/36 in severe coma)	Only reported for urokinase/HBO group 16 patients <24 h 20 patients >24 h Only 1 patient treated in less than 3 h	Only reported for urokinase/HBO group 16 patients <24 h 20 patients >24 h	2.0 ATA/60–90 BID: 5 groups: (1) standard medical treatment (2) HBOT (3) HBOT + urokinase + heparin (4) HBOT + urokinase + plasma or heparin (5) HBOT + heparin	1 patient (<2 h) had excellent outcome. All 10 patients with profound coma (Grades III and IV) died. HBO treatment alone ineffective. Very complicated article—difficult to assess group assignment, time to initiation of treatment, etc. Incomplete data Conclusion: Urokinase plus HBO did the best, especially coma Grades I, II, and III, and the best results were in those patients treated in less than 6 h
Baiborodov (1981)	(1) Newborns with birth asphyxia (2) Syndrome of respiratory disturbance (3) Aspiratory syndrome	1555 2165 3110	>15 or >1030 min	1–5 min after artificial pulmonary ventilation (APV) or 1030 min after APV	HBOT 2.3 ATA/1.52 h for 10–15 min and 1.41.5 ATA/1.5–2.5 h	HBOT decreased cerebral circulatory disorders by 4 times and/or mortality by 8 times

Mathieu et al. (1987)	Global ischemia/anoxia: Posthanging suicide attempt 88% in coma or brain dead	170 (136 HBO 34 NBO) HBO only for patients with impaired consciousness NBO patients with minor neurological problems	81% <3 h 19% >3 h	81% <3 h 19% >3 h	81% <3 h 19% >3 h	(1) 2.5 ATA/90 Q6H with NBO intervening until normal (2) Controls NBO	Worse coma requires more HBO. Recovery without neurological sequelae significantly better when HBO initiated <3 h posthanging (85 vs. 56%)
Kohshi et al. (1993)	Subarachnoid hemorrhage, status postaneurysm surgery Grade III and IV coma. Measure infarct incidence and Glasgow Outcome Scale on all, SPECT and EEG on some	43	Soon after onset of symptomatic vasospasm; exact time not mentioned	Soon after onset of symptomatic vasospasm; exact time not mentioned	Soon after onset of symptomatic vasospasm; exact time not mentioned	(1) Control: mild hypertensive hypervolemia (2) HBOT 2.5 ATA/70 QD to BID, 2–21 treatments, avg. 10	
Shn-Rong (1995)	Coma (95 cerebral ischemia/hypoxia; 23 near drownings, 44 near hangings, 2 electrocution, 14 narco-operation accidents, 1 Stokes—Adams, 4 barbital poisoning, 2 asphyxia, 5 Cover-Bedding syndrome; 56 of 95 with cardiac arrest). Moderate acute CO poisoning 156; serious acute CO 70 (up to 3 months coma); 12 hydrogen sulfide (2 h–20 days), 3 TBI (10, 20, and 30 days post)	336	Variable: Implied early treatment— first day	Variable: Implied early treatment—first day	(1) Ischemia/hypoxia: 2–2.5 ATA/120 × 2–3 days BID. Then 2 ATA/ variable time × up to 40 to 60 treatments (average 2–7) (2) Carbon monoxide: 2 ATA/120 BID × 1–2 days then 2 ATA/2 h QD (Avg 1–3 treatments moderate cases, 2–5 serious up to 40 total). One case, 3 months of coma treated 30, 60, and 60 treatments for a total of 150	Ischemia/hypoxia: 75% recovery of consciousness (62.5% of those with cardiac arrest, 92% without cardiac arrest) Carbon monoxide: 100% recovery in moderate poisoning, 93% in serious poisoning. Eleven of 12 recovery. TBI: 3 of 3 recovery	
Sanchez et al. (1999)	Intestinal ischemia, necrotizing enterocolitis, or anoxic encephalopathy	7 neonates (3 with anoxic brain injury) over 34 weeks of age and 1200 g. All ventilator dependent	<6 h to >24 h	<6 h to >24 h	<6 h to >24 h	HBOT 2.0 ATA/45 min b.i.d.	All patients treated within 6 h of delivery resolved with only one treatment. Those treated after 24 h required more than one treatment, two of whom developed pulmonary oxygen toxicity which was easily treated. Sepsis, DIC, and cerebral edema resolved after one treatment. Three-month follow-up was performed

(continued)

Table 20.2 (continued)

Authors and year	Diagnosis	No. of patients	Length of coma/ prehyperbaric oxygen therapy (HBOT)	Timing of HBOT	HBOT protocol	Results and conclusions
Van Meter et al. (1999a)	Cardiac arrest with massive decompression illness and (?) near drowning	1	<22 min	22 min	US Navy Treatment Table 6A with 100% oxygen at 6 ATA. Converted to US Navy Treatment Table 7 air saturation decompression with intermittent 3 ATA oxygen-breathing periods	Returned to functional life. Twenty-year follow-up: patient married with children and works as a custom furniture carpenter
Mathieu et al. (2000)	Near hanging	305 (136 in Mathieu et al. 1987 study)	All patients irrespective of delay to treatment	All patients irrespective of delay	HBOT 2.5 ATA/90 min i.i.d. in the 1st 24 h then b.i.d. to total of 5 treatments	76% total recovery with 16% death rate, persistent neurological sequelae in 8%. Best results of HBO <3 h postrescue
Liu et al. (2006c)	Neonatal Hyp-Ischemic Encephalopathy; randomized and quasi-randomized controlled trials	Review-20 trials	- Birth-24 days	As soon as possible to 24 days of age	1.3-2.0 ATA/60-100 min (mostly 70 min), 1x/day, most commonly for 10 days, (exact protocol not stated or confused by use of term "courses")	Better outcomes than comparator in almost all trials. Odds ratio for mortality .26 and neurological sequelae .41 Conclusion: HBO possibly reduces mortality and neurological sequelae in neonatal HIE, however poor quality trials and reporting
Category II: Acute (>3-48 h postcerebral insult)						
Illingworth (1961)	Coma: Barbiturate overdose	1	13 h	13 h	2 ATA/95 min	Immediate benefit ...later course uncomplicated
Koch and Vermeulen-Cranch (1962)	Global ischemia/anoxia after 3 min cardiac arrest	1	6 h	6 h	3 ATA/103 min (includes 60 min at 3 ATA)	Rapid recovery. Minimal visual field defect at discharge
Sharp and Ledingham (1962)	Pentobarbital overdose	1	>12 h. Patient brought to emergency room in coma; 12 h later, significant deterioration with low blood pressure, cyanosis, and assisted ventilation for 25 min. Resuscitative efforts failing	>12 h	2 ATA/65 min at depth	Rapid improvement within a few min in chamber. Discharged from hospital four days later well

Saltzman et al. (1966)	See earlier hyperacute period									
Heyman et al. (1966)	Coma: Various forms of cerebral ischemia	22 (2 in coma with quadriplegia, 2 stuporous or semicomatose)	(1) 4 h (2) 7 h (3) 7 days (4) 11 days	Questionably in first 48 h	(1) 2.36 ATA/79 x 1 (2) 2.36 ATA/45 x 1 (3) 2.0 2 ATA/26 min (4) 2.02 ATA/32 min	(1) Partial transient improvement during HBO (2) No significant change during HBO (3) No mention of immediate effect of HBOF; patient died 3 months later (4) No mention of immediate effect of HBOF; patient died 2 days later				
Holbach and Caroli (1974)	Coma: Neurosurgical cases (43 traumatic brain injury (TBI), 47 CVA, 7 tumor, 3 infection, 2 ischemia); life-threatening TBI, acute CVA, severe post-op and post-TBI brain edema	102	Questionably in first 48 h	Questionably in first 48 h	(1) 52 patients: 2-3 ATA/not mentioned (2) 50 patients: 1.5 ATA/not mentioned. Overall average 2.6 HBOTs per patient	1.5 ATA group showed a significant 92% increase in number of markedly improved patients over the 2-3 ATA group				
Dordain et al. (1969)	Hepatic coma due to viral hepatitis	1	12 h	12 h	2.4 ATA/not mentioned x 3 in 24 h	Patient became normal				
Mogami et al. (1969)	Coma: Severe acute cerebral damage. Measure EEG in 24 patients, CSF pressure, lactate, and pyruvate in 13	66 (51 severe acute trauma, 10 tumor, 2 CVA, 3 cerebral ischemia) Most in coma, 26 on vent	Acute cases, but length of coma not mentioned.	Acute cases, but time of initiation of HBOT not mentioned.	2 ATA/1 h QD or BID; 6 treatments at 3 ATA/30. Average 2 treatments per patient	Neurological improvement in 50% of cases, EEG in 33%, mostly during HBO with regression posttreatment. Best response in least injured: least response in coma patients. High variation in CSF fluid pressure, but mostly decreased during treatment with rebound posttreatment. Mixed carbon dioxide/oxygen inhalation treatment gas dangerous. Slight decrease in lactate; pyruvate in CSF				
Viard et al. (1970)	See earlier hyperacute period									
Hayakawa et al. (1971)	See earlier hyperacute period. TBI patients most likely in acute period									
Voisin et al. (1973)	See earlier hyperacute period									
Holbach et al. (1974a)	Acute mid-brain syndrome with coma (traumatic brain injury)	99	Between 2nd and 10th day of intensive care	Between 2nd and 10th day of intensive care	(1) Controls-standard intensive care (2) HBOT: 1.5 ATA/45 x 1-7	Survival rate and time increased in HBO group, especially less than or equal to 30 years old. 21% decrease in mortality and apallic state with HBO with 450% increase in complete recovery				(continued)

Table 20.2 (continued)

Authors and year	Diagnosis	No. of patients	Length of coma/neuroinsult prehyperbaric oxygen therapy (HBOT)	Timing of HBOT	HBOT protocol	Results and conclusions
Sheffield and Davis (1976)	Prolonged cerebral hypoxia: Blind, disoriented, combative, severe thrashing disoriented with severe visual impairment at time of HBO	1	6–8 min	6.5 h	2.8 ATA (US Navy TT 6) 6) US Navy TT 6A	Clearing of symptoms at 1.9 ATA, mild cognitive residual at end of 6 h treatment. Patient normal after 1.5 days
Holbach et al. (1977a)	Coma: 7 CVA, 23 TBI, all somnolent to stuporous	30	Few days	Few days postaccident		(1) Room air @ 1 ATA O ₂ @ 1.5 ATA O ₂ × 35–40 min @ 1 ATA O ₂ room air. 10 min each stop (2) Room air @ 1 ATA O ₂ @ 1.5 ATA O ₂ @ 2.0 ATA O ₂ @ 1.5 ATA O ₂ @ 1.0 ATA O ₂ @ room air
Holbach et al. (1977b)	Coma: TBI patients. High severity and acuity implied by ICP monitor and reference to comparable severe TBI patients in Holbach study earlier who were evaluated a few days postaccident. Measure CBF, blood pressure, temperature, EKG, arterial blood gases, pyruvate, and lactate. 5% CO ₂ test used to verify CO ₂ reactivity of cerebral blood vessels	14	Exact time not mentioned	Exact time not mentioned	(1) 6 patients: room air @ 1 ATA O ₂ @ 1.5 ATA O ₂ @ 2 ATA O ₂ /30 min @ 1.5 ATA O ₂ @ 1.0 ATA @ Room air. 15 min stops at each pressure except highest pressure (2) 8 patients: room air @ 1 ATA O ₂ @ 1.5 ATA O ₂ @ 2 ATA O ₂ @ 2.5 ATA O ₂ /30 min @ 2.0 ATA O ₂ @ 1.5 ATA O ₂ @ 1.0 ATA O ₂ @ Room air. 15 min stops at each pressure except highest pressure	Oxygen causes vasoconstriction up to 2 ATA. After about 15 min at 2 ATA and 2.5 ATA vasoconstriction is lost and 11 of 17 show marked increase in CBF with 4 of 11 having persistent increase after HBOT. This effect is nearly reversible on return to room air, but is a function of pressure and duration of oxygen exposure. CO ₂ levels were stable. Simultaneously lactate decreased as proceeded to 2–2.5 ATA, but after 30 min at these pressures, no further change in lactate
Holbach (Companion to above article Holbach et al. (1977b, c)	Same as Holbach (1977b). Measure EEG	14	Same as Holbach (1977a)	Same as Holbach (1977a)	Same as Holbach (1977a)	Correlation between CBF and EEG up to 1.5 ATA with decrease in CBF and improvement in EEG. At 2.0 and 2.5 ATA there is a dissociation of vasoconstriction and EEG with severe alterations in EEG while CBF generally increases, due to oxygen toxicity. Upon return to room air, the changes are mostly reversible
Larcan et al. (1977)	See earlier hyperacute period					

Isakov et al. (1982)	Coma: Acute ischemic stroke (some status postsurgery for subarachnoid hemorrhage). Includes 11 internal carotid artery and 10 vertebral-basilar artery strokes. Thirty patients in coma of varying degree. Authors measured a variety of pulmonary function parameters	53	<6 days poststroke or two days postsurgery	<6 days poststroke or 2 day postsurgery	Based on patients age, severity, and associated diseases. 1.6–2.0 ATA/55–90 min (exact total bottom time unclear by description) × 6–10 treatments Groups and data assignment unclear at times, but improved neurological condition in all groups and normalization of initial abnormal external respiration by eliminating pathological rhythms and decreasing hyperventilation. This effect occurred with a variable number of HBOT sessions. In the vertebral basilar artery group, significant decrease in respiratory volume and minute respiratory volume. (In 50 % stabilization of external respiration by the middle of the HBO course)
Sukoff and Ragatz (1982)	Coma: Acute severe traumatic cerebral edema	50	Approximately 6 h	Less than 6 h after admission	Group 1: 40 patients, 2 ATA/45 Q8 h × 48–96 h Group 2: 10 patients, 2 ATA/45 Q8 h × 48 if ICP >15 after Osmitol Group 1: 22/40 improved. Better and more sustained results in lesser injured patients Group 2: significant reduction in ICP
Smilkstein et al. (1985)	Hydrogen sulfide coma	1	10 h	10 h	Asymptomatic at discharge, but bilateral Babinski and slight difficulty with complex tasks
Hsu et al. (1987)	Hydrogen sulfide coma	1	6 h	6 h	Normal neurologically
Mathieu et al. (1987)	See earlier hyperacute period				
Belokurov et al. (1988)	Coma. Pediatrics (13 TBI, 2 subarachnoid hemorrhage, 7 hypoxia, 1 diabetic coma), measured coma score	23	4 h–17 days, when exclude 3 cases greater than 1 week old each, average =21.6 h	21.6 h	2.5 ATA/45 initially then 2.0/75 × 1, then 2.0/90–120 TID initially to QD. Total 12 treatments 2.5 ATA/80 TID in first 24 h, then QD for a total of 15 treatments 1.7–2.0 ATA/60 × 1/day 1–11 treatments

(continued)

Table 20.2 (continued)

Authors and year	Diagnosis	No. of patients	Length of coma/neuroinsult prehyperbaric oxygen therapy (HBOT)	Timing of HBOT	HBOT protocol	Results and conclusions
Rockswold et al. (1992)	Coma: Acute TBI (Glasgow Coma Scale 9 for 6 h)	168 (Randomized prospective controlled)	Average 26 h postinjury	Average 26 h postinjury	(1) 1.5 ATA/60 Q8 h x 2 weeks until brain dead or awake (avg. 21 treatments) (2) Control group: no HBO	Nearly 60% reduction in mortality in HBO group, especially for those with ICP > 20 or GCS of 4–6
Thomson et al. (1992)	CO poisoning with persistent coma after 1st HBO treatment and normal carboxyhemoglobin	1	5.5 h	5.5 h	3 ATA x 1.2 ATA/90 BID x 3 days, QD x 10 days with 1 day break. Total 17 treatments	Normal at 5 weeks with maintenance of recovery measured by neuropsychometric testing
Dean et al. (1993)	Coma: Carbon monoxide poisoning	1	Day of poisoning	Day of poisoning	2.4 ATA/90 BID x 3 days, total 6 treatments	Awakening after 6 HBO. No evidence of significant neurological sequelae at 1 month
Kohshi et al. (1993)	See earlier hyperacute period					
Shn-Rong (1995)	See earlier hyperacute period					
Snyder et al. (1995)	Hydrogen sulfide poisoning coma, GCS = 3	1	11–12 h postexposure	11–12 h postexposure	3 ATA/60 then 2.5 ATA/90 BID x 1 day, 2.0 ATA/90 BID x 5, 2.0 ATA/90 QD x 10 23 total	Stepwise neurological improvement with HBOT. Significant cognitive residual
Yangsheng et al. (1995)	Respiratory and heart sudden stopping	27 (13 hanging, 7 electric shock, 2 cardiomyopathy, 1 overdose, 1 encephalitis-B, 1 severe CO, 1 acute anoxia, 1 severe crush injury. (Part of group of 324 patients which included CO/H2S/CN and severe TBI)	Cardiac and/or respiratory arrest, 211 min, 7 patients unknown. (?)		HBOT 2.5 ATA/60 min q.d. x10 = 1 course. Repeat course as needed. Average 29 treatments (range, 4–50)	59% cured, 37% died, 4% improved
Liu et al. (2006c)	Hypoxic/ischemic encephalopathy	Review of Chinese literature	Hours to 24 days	Hours to 24 days	1.2–2.0 ATA/60–100 min, daily, 5–50 treatments	Significant reduction in mortality and neurological sequelae
Liu et al.	See earlier Hyperacute Period					

Zhou et al. (2008)	Hypoxic-Isch. Encephalopathy; Measure malondialdehyde (MDA), super-oxide dismutase (SOD), nitric oxide (NO), NO synthase, neonatal behavioral neuro assessment, (NBNA), and eye ground examination pre and post-HBO	60 neonates				Randomly administered 1.4, 1.5, or 1.6 ATA/ unstated period of time, 1x/day x 7 days	SOD higher and MDA, NO, and NOS lower in all 3 groups: all values for 1.6 group signif. better than 1.4 group while SOD and MDA signif. better 1.6 vs. 1.5 group. NBNA signif. incr. in all groups. None showed abnormal eye grounds. Conclusion: HBO with 1.4,1.5, 1.6 ATA safe and effective for neonatal HIE. Antioxidant capacity increases with increasing HBO pressure
Niu et al. (2009)	Heat Stroke/Coma. Measure GCS and laboratory values	1	Not stated	Several hours postconventional treatment in emergency department	1.5 ATA/90 min, twice/day for 3 days (6 treatments)	GCS 5 on Day 1 progressed to GCS 8 on Day 4, extubated with normal core temperature and blood pressure. Discharged from hospital Day 12 with all laboratory normal	
Rockswold et al. (2010)	Acute severe TBI, GCS \leq 8, avg. 5.8 Cerebral Blood flow, Arterial-venous O ₂ diff., cerebral metabolic rate of O ₂ , ICP, CSF lactate, F2-isoprostane, bronchial IL-6 and 8 measured pre, 1 h, and 6 h posttreatment	69	57 of 69 < 24 h, 12 < 48 h	57 of 69 < 24 h, 12 < 48 h	Group 1: Control standard care Group 2: Normobaric 100% O ₂ for 3 h Group 3: HBO @ 1.5 ATA/60 min at depth NBO and HBO delivered 1x/24 h x 3 days (3 total)	HBO and NBO increase PO ₂ , HBO persists for at least 6 h posttreatment HBO increases CBF and CRMO ₂ for 6 h HBO and NBO decrease CSF lactate, HBO for 5 h posttreatment. Lac/pyruv. decreased post-HBO and NBO. All parameters had most improvement when PO ₂ > 200 (HBO). ICP lower after HBO and persists. Oxygen toxicity biomarkers no effect Conclusion: Dose-response oxygen benefit in acute severe TBI: HBO maximal No oxygen toxicity	
Rockswold et al. (2013)	Acute severe TBI, GCS \leq 8, avg. 5.7 Measure markers of cerebral metabolism, oxygen toxicity, ICP before, during, and up to 24 h posttreatment and clinical outcome after 6 months	42	37 of 42 < 24 h, 5 < 48 h	37 of 42 < 24 h, 5 < 48 h	Group 1: Control standard care Group 2: HBO @ 1.5 ATA/60 min at depth + 100% O ₂ 1 ATA/3 h, 1x/24 h x 3 days (3 total)	HBO/NBO: increased PO ₂ , normal and pericontusional brain during and posttreatment; decreased lac/pyruv. in normal brain; decreased ICP until next treatment; improved oxygen toxicity markers; improved mortality and favorable outcome Conclusion: combined HBO/NBO has better effect than either treatment alone	

(continued)

Table 20.2 (continued)

Authors and year	Diagnosis	No. of patients	Length of coma/neuroinsult prehyperbaric oxygen therapy (HBOT)	Timing of HBOT	HBOT protocol	Results and conclusions
Category III: Subacute (49 h–1 month postcerebral insult)						
Heyman et al. (1966)	See earlier acute period and Saltzman study					
Holbach and Caroli (1974)	See earlier acute period					
Holbach et al. (1974)	See earlier acute period					
Artru et al. (1976a)	Coma (TBI). Measure cortical blood flow, cerebral metabolic rate for oxygen, cerebral metabolic rate glucose and lactate, glucose, lactate, and CSF parameters, (PO ₂ , glucose, lactate), pre and 2 1/3 h after HBO ₂ 133Xenon technique	6 (3 post-op, plus 3 brainstem contusion) 12 normals plus controls with multiple sclerosis, and medical literature normal controls, all for cortical blood flow measurement	5–47 days postinjury	5–47 days postinjury	2.5 ATA/90 × 1; 1 patient 2.2 ATA 1 patient 3 studies, 1 patient 2 studies, 4 patients 1 study	Arterial PO ₂ decrease in 8 of 9 patients, cortical blood flow variable due to differential effects on normal and injured brain
Artru et al. (1976b)	Coma (TBI)	60 (57 intubated or with tracheostomy) 9 subgroups	4.5 days	4.5 days	(1) 2.5 ATA/90 min QD × 10, 4 day break, repeat sequence until recovery of consciousness or die (2) No HBO	One subgroup (brainstem contusion) significantly higher rate of recovery of consciousness at 1 month with HBO and lower rate of persistent coma
Holbach et al. (1977b)	See earlier acute period					
Holbach et al. (1977c)	See earlier acute period					
Larcan et al. (1977)	See earlier hyperacute period					
Isakov et al. (1982)	See earlier acute period					
Belokurov et al. (1988)	See earlier acute period					
Kawamura et al. (1988)	Subarachnoid hemorrhage after operative intervention: 81 % with vasospasm on angiography. Measure SSEPs pre, during, and after HBO. The during and postmeasurements were done on different HBOTs	26 patients (some in coma)	2–62 days after the last subarachnoid hemorrhage	2–62 days after last subarachnoid hemorrhage	HBOT 2 ATA/70 min? 1.3 ATA/10 min (loosely fitted mask during HBO treatment)	Significantly improved SSEPs during HBO in 57 % of cases between 2 and 14 days posthemorrhage. Retention of effect highest in those treated within first 5 days of SAH and those with mild neurological deficits or mild brain swelling. Minimal effect in moderate to severe cases

Sato et al. (1989)	Global ischemia/anoxia: postdrowning patient in coma	1	5th hospital day	5th hospital day					Not mentioned in English abstract of Japanese author	Gradual progress	
Shn-Rong (1995)	See earlier hyperacute period										
Neubauer et al. (1998)	Global ischemia/anoxia 1 Status epilepticus/hypoglycemia, 1 patient near drowning, SPECT brain imaging performed	2	Patient 1: over 1 week postinsult ambulatory, poor speech, agitated, combative Patient 2: 1.5 months post-near drowning	Patient 1: over 1 week postinsult ambulatory, poor speech, agitated, combative Patient 2: 1.5 months post-near drowning					(1) 1.5 ATA/60 QD to BID total 88 (2) 154 treatments	Improved SPECT and neurological outcome in both patients	
Rockswold et al. (2001)	Acute severe TBIs. GCS <8. Measure CBF, AVDO ₂ , CMRO ₂ , CSF lactate, ICP pre-, during, and post-HBOT	37	Average 23 h (9–49 h)	Delayed HBOT averaged 23 h (9–49 h)					HBO 1.5 ATA/60 min at depth q 24 h × 7 maximum, average 5/ patient. 2nd Rx began >8 h after 1st treatment	Improved CMRO ₂ and CSF lactate, especially in patients with decreased CBF or ischemia, recoupling of flow and metabolism, persistent effect lasting >6 h, reduction elevated ICP and CBF. Rec: shorter, more frequent sessions	
Ren et al. (2001)	Acute severe TBI. Average GCS = 5.3 (controls), 5.1 (HBOT)	55 (20 control, 35 HBOT), randomized	“On the third day”	“On the third day”					2.5 ATA/40–60 min, ×10/4 days (1 course), × 3–4 courses	Significant improvement of: GCS and BEAM (with successive courses of HBOT), Glasgow Outcome Scale at 6 months, and morbidity and mortality	
Liu et al. (2006c)	Hypoxic/ischemic encephalopathy	Review of Chinese literature	Hours to 24 days	Hours to 24 days					1.2–2.0 ATA/60–100 min, daily, 5–50 treatments	Significant reduction in mortality and neurological sequelae	
Liu et al.	See earlier Hyperacute Period										
Nakamura et al. (2008)	Severe TBI Initial GCS ≤ 8 Only 1 with GCS ≤ 8 at Time of HBOT Measure transcranial Doppler Mean flow velocity, and pulsatility index, arterio-jugular venous O ₂ difference and jugular venous lactate	1 of 7	Subacute, after acute therapy in the ICU”	Subacute, after acute therapy in the ICU”					2.7 ATA/60 min. once/day × 5 days (total 5 treatments)	Sole patient still in coma at time of treatment. This patient and 2/6 had unfavorable outcomes. Data presented as group data so not possible to extract this patient’s data. Significant group reduction in jugular venous lactate (JVL) and correlation of JVL with pulsatility index. No significant change mean flow velocity or AV O ₂ difference	
Zhang et al. (2009)	Coma from central pontine myelinolysis postliver transplant. Moderate coma, GCS-Pittsburgh score of 20	1	9 days	9 days					? ATA/2 h, 1×/day × 14 days	Mild coma, GSC-Pittsburgh score 26 pupillary reaction, increased autonomic activities and muscle tone after HBO. At 6 months, mild coma	(continued)

Table 20.2 (continued)

Authors and year	Diagnosis	No. of patients	Length of coma/neuroinsult prehyperbaric oxygen therapy (HBOT)	Timing of HBOT	HBOT protocol	Results and conclusions
Category IV: Chronic (>1 month postcerebral injury)						
Neubauer (1985)	TBI. Prolonged coma, random selection	17	7.5 months	7.5 months	HBO 1.5 ATA/60 min, x40–120 treatments	Average 88% improvement on Glasgow Coma Scale. Twelve of 17 substantial improvement on GCS, five of 17 qualitatively improved
Kawamura et al. (1988)	See earlier subacute period					
Eltorai and Montroy (1991)	Coma: TBI plus anoxia	1	48 days	48 days	2 ATA/90 daily x 24	Recovery of consciousness; cognitive deficits. Extubated at day treatment center
Neubauer et al. (1989)	Global ischemia/anoxia/carbon monoxide and natural gas	1	2 years postinsult	2 years postinsult	1.5 ATA/60 x 21 treatments	Dramatic cognitive improvement and decrease in spasticity
Neubauer et al. (1992)	Global ischemia/anoxia: 12 years previously	1	12 years	12 years	1.5 ATA/60 QD, 61 treatments in 5 months	Marked neurological and cognitive improvement
Harch et al. (1994a)	Global ischemia/anoxia	4	Average age 3.25 years	Average age 3.25 years	1.5 ATA/90 QD x 80	All patients improved, some substantially. SPECT brain imaging improved
Neubauer (1995)	TBI: Coma, semiapallic	1	12 months	12 months	1.5 ATA/60 x 188	Improved from coma to ambulation and self-sufficiency
Shn-Rong (1995)	See earlier hyperacute period					
Neubauer et al. (1998)	Severe anoxic/ischemic encephalopathy: Abruptio placentae (1), near drowning (4), chokehold (1), natural gas + CO (1), and CO (1). Measured clinical outcomes and performed SPECT brain imaging before and after at least one hyperbaric treatment. SPECT and clinical outcomes measured	8	Unknown	3 months to 12 years postevent	HBOT 1.5 ATA, occasional 1.75 ATA/1 h q.d. to b.i.d. x 1, 27, 122, 181, 27, 200, 19, and >200 treatments	Clinical improvement in all patients and on SPECT
Neubauer and James (1998)	See earlier subacute period					
Montgomery et al. (1999)	Cerebral palsy. Measure gross motor functional measures (GMFM), Jebsen hand test, Ashworth spasticity scale, and video exams pre- and posttreatment	25	Unknown	Average age 5.6 years	Control each patient served as his own control	HBOT: 1.75 ATA 95% oxygen/60 min at depth q.d., 5 days per week x 20 treatments or 1.75 ATA 95% oxygen/60 min at depth b.i.d., 5 days per week x 20 treatments

<p>Collet et al. (2001)</p>	<p>Cerebral palsy measure GMFm, psychometric test, and PEDI questionnaire pre, post, and 3 months after treatment</p>	<p>111</p>	<p>History of perinatal hypoxia</p>	<p>Average age = 7.2 years</p>	<p>Control 1.3 ATA air/60 min at depth q.d., 5 days per week x 40 HBOT 1.75 ATA 100% oxygen/60 min at depth q.d., 5 days per week x40</p>	<p>Improvement in GMFM in both groups which persisted at 3 months. Greatest changes in children with lowest scores which were independent of age. Improvement in language production, attention, memory, and PEDI in both groups. Caregiver scores for PEDI favored the air group. Improvement in oral facial structure and functional speech and language test in the air group</p> <p>Average 50% of patients with noticeable improvements in different tests</p>
<p>2nd International Symposium on Hyperbaric Oxygenation and the Brain Injured Child (authors: Neubauer, Harch, Chavdarov, Lobov, Zerbini 2002)</p>	<p>Chronic brain injury: Great majority of patients were cerebral palsy or global ischemia, anoxia and coma. Variety of tests performed including physical exam, laboratory testing, and functional brain imaging with SPECT</p>	<p>361</p>	<p>(?)</p>	<p>Vast majority <10 years of age</p>	<p>1.5-2 ATA oxygen/60-90 min q.d. to b.i.d., x 1 to >500 treatments (rare case)</p>	<p>Improvement in SPECT from first to last scan for both hemispheres and cortex with the 3rd SPECT showing more improvement than the 2nd SPECT, which was improved over the 1st. Main increase in blood flow didn't occur until after 2nd SPECT scan and a substantial number of treatments (>15). No change in blood flow to the pons and cerebellum</p>
<p>Golden et al. (2002)</p>	<p>Chronic neurological disorders: CP 30%, TBI 26%, anoxic/ischemic encephalopathy 16%, CVA 12%, Lyme disease 6%, other 10%. Measure SPECT pre, after at least 15 HBOTs, and after a course of at least 50 HBOTs</p>	<p>50 (25 under 18 years old and 25 over 18 years old)</p>	<p>Unknown</p>	<p>Average 5-1/3 years postinsult</p>	<p>HBOT 1.25-2.5 ATA/60 min b.i.d. (12 x per week)</p>	<p>Better self-control and significant improvements in auditory attention, and visual working memory both groups. No difference between groups. Sham group significantly improved on 8 dimensions of parent rating scale vs. 1 dimension in HBO. No change in verbal span, visual attention, and processing speed in either group</p>
<p>Hardy et al. (2002)</p>	<p>Cerebral palsy, Psychometric testing pre- and posttreatment</p>	<p>75</p>	<p>(?)</p>	<p>3-12 years of age. No average age given</p>	<p>Control 1.3 ATA air/60 min at depth q.d., 5 days per week x 40. HBOT 1.75 ATA oxygen/60 min at depth q.d., 5 days per week x 40</p>	<p>Improvement in SPECT from first to last scan for both hemispheres and cortex with the 3rd SPECT showing more improvement than the 2nd SPECT, which was improved over the 1st. Main increase in blood flow didn't occur until after 2nd SPECT scan and a substantial number of treatments (>15). No change in blood flow to the pons and cerebellum</p>

(continued)

Table 20.2 (continued)

Authors and year	Diagnosis	No. of patients	Length of coma/neuroinsult prehyperbaric oxygen therapy (HBOT)	Timing of HBOT	HBOT protocol	Results and conclusions
Miura et al. (2002)	Overdose with loss of consciousness and cyanosis x unknown amount of time. Secondary deterioration fifteen days later with akinetic mutism. Measure EEG, MRI, MRS, and SPECT	1	(?)	50 days	HBO 2.0 ATA/90 min, 5 days a week x 71	Progressive improvement through 33 Rxs. Deterioration with strange behavior by 47th Rx. 52nd Rx disoriented, restless, and agitated with decreased memory. Excitability by 71st Rx requiring Valium, Tegretol, and Haldol. Behavior improved post-HBOT but disorientation and amnesia worsened. Nine months later patient better than pre-HBO. MRI, MRS, and EEG tracked patients course
Waalkes et al. (2002)	Cerebral anoxia: 8 with CP, 1 near drowning. Measured GMFm, spasticity, WEEFIM, video exams, parent questionnaire, and time spent in any 24-h. period by caregivers	9	(?)	6.4 years average age	1.7 ATA oxygen/60 min q.d., 5 days a week x 80	58 % average improvement in GMFm, minimal improvement WEEFIM, no change spasticity. Significant reduction in time spent with caregiver in 24-h period. Patients still improving at end of study
Golden et al. (2006)	Chronic brain injury (Children: CP 29 %, TBI 26 %, HIE 17 %, Stroke 12 %, Lyme 7 %, other 9 %; adults: TBI 26 %, stroke 26 %, anoxia 21 %, hypoxia 7 %, other 20 %	21 children, 21 adults, each compared to 42 untreated brain injured and normal children or adults. Prospective, nonrandomized	Not stated	Static level of function for at least 1 year, but many patients were years postinsult. Adults were at least 2y postinsult	Not stated, but HBOT protocol well known at this clinic: 1.15-2.0 ATA/60 q.d.-b.i.d. Children: avg. 28 Rx's in 28 days. Adults: avg. 35 Rx's in 35 days	Children: significant improvement in measures of daily living, socialization, communication, and motor skills. Adults: significant improvements on all neuropsychological measures, including attention, motor, tactile, receptive and expressive language, word fluency, and immediate and delayed memory
Senechal et al. (2007)	Cerebral palsy	Review of literature	Not mentioned	Years postinsult	All published HBOT studies. Compared HBOT studies using the Gross Motor Functional Measures (GMFM) outcome to standard therapies using the GMFM	Significantly greater rate of GMFM improvement compared to all but one study which used dorsal rhizotomy. HBOT was the only therapy that also improved cognition

<p>Harch et al. (1996a, b); Harch and Neubauer (1999; 2004)</p>	<p>Severe chronic TBI, near drowning, CP/autism disorder, CP, battered child. Measure clinical improvement by video. SPECT imaging, and cognitive tests in one</p>	<p>8</p>	<p>6 months–8 years</p>	<p>6 months–8 years</p>	<p>1.5 ATA/60 or 90 min total drive time 1–2x/day × 80 with 3–4 weeks break at approximately halfway point</p>	<p>Significant clinical gains in all patients with concomitant improvement in SPECT or cognitive tests. Reduction in seizures in one, normalization of seizure activity on EEG in another patient</p>
<p>Jiang et al. (2004)</p>	<p>Severe TBI, GCS 3–8. Measure Consciousness Recovery</p>	<p>175</p>	<p>1–12 months</p>	<p>1–12 months</p>	<p>Not stated. HBOT was 1x/day for 90 days</p>	<p>63 % recovered consciousness: 73 % w/1–3 months Coma, 48 % 4–6 months Coma, 27 % 6–12 months Coma. 57 % vs. 78 % with/ vs. w/o brainstem injury; 46 % vs. 75 % with vs. w/o cerebral herniation, 53 % w/ GCS 3–5, 75 % w/ GCS 6–8</p>
<p>Liu et al. (2009)</p>	<p>Persistent coma: trauma (9), CO (1), electrocution (1), ruptured AVM (1). All had 3 months of median nerve stimulation and were still in coma. Patients administered HBO and cervical spinal cord stimulation. Measure EEG, SPECT, GCS, and persistent vegetative state scores</p>	<p>12 patients 12 control</p>	<p>3–12 months</p>	<p>3–12 months</p>	<p>2.5 ATA/90, 1x/day, 5 days/week × 4 weeks, 1 week break, repeat (total 60 HBOTs). Spinal cord electr. stimulation 14 h/day, every day × year. Control: 3 months medial nerve stimulation before 1 year observation</p>	<p>6 patients in HBO emerged from coma, none in control. GCS, SPECT, PVS signif. increased in HBO grp. No tracheostomy or ventilator needed and only 1/12 with nasogastric feeding tube. No apparent improvement in control patients Conclusion: Increase in GCS, cerebral blood perfusion in coma patients with spinal cord stimulation and HBO</p>
<p>Churchill et al. (2013)</p>	<p>Chronic anoxia, stroke, or TBI. Many with initial severe injury (54 % required inpatient rehabilitation. Measure feasibility, cognition, questionnaires, neuro exam, physical function some with speech evaluation and neuroimaging</p>	<p>63</p>	<p>1–29.3 years</p>	<p>1–29.3 years</p>	<p>1.5 ATA/60 min once/day × 60 (60 total HBOTs)</p>	<p>Feasibility was confirmed, although 44 % required additional time to complete. Many reported symptom improvement, but generally not confirmed on standardized testing. Some significant cognitive and speech improvements, but not “clinically significant.” Majority of imaged patients with significant improvement in functional imaging. 93 % would participate again. No significant side effects</p>

Review of Animal Experimental Studies

A review of the studies listed in Table 20.1 leads to the conclusion that HBO is unequivocally beneficial in acute global ischemia/anoxia regardless of treating pressure, frequency, duration, or number of treatments, but is sensitive to time to onset of HBO postinsult. Since the first publication of this chapter in the third edition of the Textbook in 1999, the data has been fortified with each successive edition of the text. Forty-five of forty-seven studies gave positive results, one study did not show any benefit, and one study used normobaric oxygen. In the complete ischemia models nearly all of the studies were performed at 2 ATA. Moody et al. (1970) showed a nearly 50% reduction in mortality without the benefit of artificial ventilation using a prolonged 2 ATA exposure (4 h). Mrcic-Pelcic et al. (2004a) performed two metabolic studies assessing delay to HBOT as long as 168 h and found that HBOT at 2 ATA could prevent decline of ATPase and increase SOD in hippocampus if initiated as late as 24 h and 168 h, respectively. When they looked at the optic nerve (Mrcic-Pelcic et al. 2004b), however, HBO was effective with ATPase only if begun within 6 h of ischemia and had no effect on SOD regardless of time of initiation. Clinical parameters were not measured in either study, but it appears that optic nerve is more sensitive to complete global ischemia. Yatsuzuka (1991) generated a significant decrease in ICP and oxidative stress metabolites with a 2 ATA/170 min staged protocol. The sole lower pressure study by Kapp et al. (1982) measured EEG recovery time and CSF lactate change, demonstrating significant improvement at 1.5 ATA, for a prolonged 2.5 h. Ruiz et al. (1986) was the only insignificant result with a 2 ATA/1 h exposure, but this lack of efficacy may be partially explained by hemodilution with hetastarch prior to HBO.

The studies with possibly the greatest clinical implication for neonatal ischemic/hypoxic birth injury were the two studies by J. Chen et al. (2009), Chen and Chen (2010). Using the pregnant uterine harvest/global ischemia model of Bjelke et al. (1991), Chen demonstrated that HBOT at 2 ATA begun 24 h after ischemia and continued daily for 14 days improved synaptic transmission efficiency, electrophysiologic conduction velocity, reduced neuronal death and improved ultrastructure in the hippocampus, and improved cognition in rats 4 weeks after the hypoxic/ischemic insult. The HBO salvage effect was so extensive that no statistical difference could be measured between control rats and HBO-treated hypoxic/ischemic rats in cognition, hippocampal ultrastructure, and synaptic plasticity. These studies reaffirm the clinical studies in Table 20.2, especially the review of Chinese HBOT neonatal ischemic/hypoxic encephalopathy studies.

Using higher pressures, Takahashi et al. (1992), Iwatsuki et al. (1994), Krakovsky et al. (1998), and Zhou et al. (2003) at 3 ATA, Mink and Dutka (1995a, b) at 2.8 ATA, and Rosenthal et al. (2003) at 2.7 ATA obtained statistically sig-

nificant positive results on survival, neurological recovery, and various physiological or metabolic measures. In the Rosenthal experiment survival improved with increased oxygen extraction ratio but without a change in oxygen delivery or cerebral metabolic rate for oxygen, suggesting an improvement of the microcirculation similar to the Zamboni et al. (1993) HBO/peripheral global ischemia reperfusion model in rats. The Zhou experiment underscored the more permanent gene-signaling trophic effects of early HBO by showing a persistent elevation of Ng-R and RhoA, which are both associated with the inhibition of growth cone collapse, i.e., improvement of growth. Despite the tissue slice model of the (Gunther et al. 2004) experiment the results were interesting because they suggested equal sensitivity of pathological targets to both HBO and NBO very early after ischemia (5 min), but only HBO had a positive effect after 30 min of ischemia. In addition, only the HBO dosage had any effect on morphology regardless of early or later initiation. These results reinforce the points made in the introduction to this chapter about hyperbaric dosage differences with evolving pathology and the possible difference in efficacy of HBO depending on the route of delivery. The dose by aviator mask is lower than by oxygen hood or in a pure oxygen environment. Similarly, the dose of HBO in tissue slices is markedly different when 1 ATA and 3 ATA oxygen are used. Lastly, the study by Mink and Dutka (1995b) had conflicting results with a simultaneous decrease in brain vascular permeability and blood flow while somatosensory evoked potentials were unchanged. This implies concomitant beneficial and detrimental effects which are difficult to explain without more data.

The five Van Meter et al. (1988, 1999b, 2001a, b, 2008) studies are unique in that they showed resuscitation of animals using HBO, rather than delivering HBO after resuscitation as in the Rosenthal article. These combined experiments were dose-response evaluations of HBO at 1.0, 2.0, 2.8, 4.0, and 6.0 ATA. The swine study proved the ability of 4 ATA HBO to resuscitate animals after 25 min of cardiac arrest, simultaneously truncating white blood cell-independent brain lipid peroxidation. This is the longest successful arrest/resuscitation reported in the medical literature and has profound implications for application to human cardiac arrest (see Chaps. 42 and 43, HBO in Emergency Medicine). In 14 of the 20 studies the benefit of HBO was generated with one treatment, in two studies with three treatments, in two studies with seven treatments, and in the remaining two studies with 14 treatments. No consensus emerges for the ideal dose of HBO after complete global ischemia since only one study was done at less than 2.0 ATA, but the Van Meter dose-response study suggests that, at least in one model the maximal beneficial effect may be at doses nearly double the maximal clinical dose (6 ATA). More importantly, in the 20 studies, a beneficial effect on global ischemia, anoxia, and coma was demonstrated even when the ischemic insult was

as long as 1 h (two studies) and the delay to treatment as long as 24 h after the ischemic insult (Zhou et al. 2003; J. Chen et al. 2009, Chen and Chen 2010).

The results are similarly impressive and uniformly positive in the group of incomplete global ischemia/anoxia experiments. As in the complete models no consensus emerges as to best HBO pressure, duration, frequency, or number of treatments, but time to intervention remains a dominant theme. With greater delay to treatment the beneficial effect of HBOT is less; however, this effect can be increased by increasing numbers of treatments out to 96 h postinsult (Wang et al. 2009). Shiokawa et al. (1986) demonstrated an improvement in survival with 2 ATA HBO for only 30 min, with best results at three hours postinsult as opposed to one hour. Weinstein et al. (1986) achieved an 84% reduction in mortality with a 15 min 1.5 ATA treatment and Grigor'eva et al. (1992) demonstrated a superior effect of 1.2 ATA/30 min over 2 ATA/60 min on survival and preservation of neuronal transcription. Yaxi et al. (1995) and Yiqun et al. (1995) both showed improvements in brain enzymatic function from a single HBO treatment at 2.5 ATA with the Yaxi article suggesting a minimum 20–40 min duration of HBO exposure for efficacy. Konda et al. (1996), meanwhile, showed that repetitive HBO at 2 ATA/60 preserves hippocampal neurons and decreases heat shock proteins; there was a greater effect when the HBO was started at 6 h instead of 24 h. Essentially, HBO prevented delayed cell death (apoptosis) without oxygen toxicity. This antiapoptotic effect or preservation of neurons was also proven by Calvert et al. (2002, Calvert and Zhang 2005), Li et al. (2005), indirectly by Liu XH (2006b), Liu M-N (2006a), Liu et al. (2007), Wang et al. (2008), Wang et al. (2009), S Chen et al. (2009), Liu et al. (2013), Malek et al. (2013), Yin et al. (2013), and Zhu et al. (2015). The Zhu study showed that this effect occurred in the absence of oxidative stress despite 7 HBOTs. The Wang et al. (2009) study extended the time window to 96 h postischemia, but showed a waning time-dependent effect that could be increased with repetitive course of HBOT. All of these studies were performed at 2–3 ATA. The Li and S Chen (2009) articles underscored the complexity of the microscopic brain injury milieu and the myriad of possible targets by its beneficial effect on apoptosis while increasing pro-apoptotic Caspase 8 and decreasing antiapoptotic bcl-2 (Li) and the Caspase-3 and Nogo-A pathways (S Chen). In Calvert's 2005 article the antiapoptotic effect occurred with both 3ATA and 1ATA.

All remaining incomplete global ischemia models used 1.2–3 ATA and varying numbers of treatments, indicating that the intermittency of dosing pioneered in HBO therapy maybe more important than the actual dose of oxygen. One study (Malek et al. 2013) suggested that the effect on neuronal survival was secondary to the prevention of brain temperature increase after ischemia which was primarily due to the increase in pressure, not oxygen. The data in these multiple studies sug-

gests that early after incomplete or complete global ischemia pathological targets may be sensitive to a wide range of oxygen and pressure doses as long as they are short.

The clinical importance of all of these incomplete global ischemia studies is that, along with the Hai et al. (2002) study, they used similar animal models to simulate human neonatal ischemia/hypoxia, a research and clinical subject of intense interest that has been heightened by review of the important neonatal resuscitation paper by Hutchison et al. (1963) in the 1999 edition of this textbook. In the Hai study repetitive 2.5 ATA HBO delivered 7 days postinsult had a signal induction effect on brain fibroblastic growth factor (bFGF) while also increasing the amount of bFGF; bFGF increase also occurred in the hyperbaric air group. Most importantly, the studies that concurrently measured apoptosis, neuronal density, and functional (cognitive, motor, and behavior) outcomes showed that the histological improvements co-occurred with the functional improvements. Calvert et al. (2002), Liu XH (2006b), Liu M-N (2006a), Liu et al. (2007), S Chen et al. (2009), and Liu et al. (2013) all showed that the short-term effect on apoptosis, neuronal density, and improved morphology/histology with either one or two early HBO treatments translated to improved behavioral/neurological outcomes at 5–6 weeks. Wang et al. (2008) demonstrated the same effect with seven HBOTs up to 12 h after ischemia, Malek et al. (2013) with three treatments and a 6 h delay, and Zhu et al. (2015) with seven treatments and 72 h delay. Chen and Chen (2009) was able to demonstrate a similar histological effect paired with improved electrophysiological function using 14 treatments 24 h after ischemia, while Wang et al. (2007b) demonstrated white matter preservation and improved cognition/motor function 12 h after ischemia. These studies underscore the Hutchison clinical findings and strongly argue for additional human application of these animal findings. In particular, the white matter preservation in Wang et al. (2007b) has significant implication for the periventricular leukomalacia in cerebral palsy CP.

The remaining significant anatomic benefit of HBOT in the incomplete global ischemia models is the effect on stem cells. The studies by Yu et al. (2006), Wang et al. (2007a), Wang et al. (2008), Yang et al. (2008), and Yin et al. (2013) are important for the demonstration of increased stem cells with 7 HBO treatments at 2 ATA up to 24 h after ischemia. In the Yang study these stem cells migrated to cerebral cortex by 14 days and new tissue growth was seen at 28 days. These findings underscore the known trophic effects of HBOT in noncentral nervous system models and suggest a similar process in the chronic brain injury study of HBO (Harch et al. 2007). The underlying mechanism in the acute phase of injury may be due to HBO effects on HIF-1 α , which was demonstrated at both 2.5 and 1 ATA (Calvert et al. 2006), the Wnt-3 signaling pathway (Wang et al. 2007a), and the bone morphogenetic protein-4 and nestin pathways (Yin et al. 2013).

The only equivocal study (Mickel et al. 1990) showed that normobaric oxygen (NBO) gave mixed results: increased production of white matter lesions while sparing cortical neurons. Lastly, the Wada et al. (1996) study, the only model with pre-ischemic HBO, proved an antiapoptotic effect of HBO. This is somewhat similar to the protective effect of precarbon monoxide exposure HBO in the Thom (1993a) model. Despite the inability to establish clear guidelines regarding HBO parameters in incomplete global ischemia/anoxia, the results of HBO treatment have been uniformly positive across the range of ischemic exposures (up to 3.5 h), with delays in starting HBO treatments up to 7 days, treatment pressures as low as 1.2 ATA and HBO durations as short as 15 min.

Most of the earlier studies initiated HBO within three hours of insult and showed positive results with a maximum of seven treatments and in most cases only one. The exceptions, however, represent 20% of the studies and they demonstrate HBOT-induced improvements in anatomic, biochemical, histological, and genomic parameters with delay to treatment up to 96 h after ischemia and functional improvements up to 72 h after ischemia. Simultaneously, no overt oxygen toxicity has been demonstrated. The near uniform success of all of the earlier animal experiments suggests that preischemic HBO or single HBO soon after ischemia, possibly as late as 6 h, is highly beneficial and probably the most important factor in positive outcomes while the absolute HBO pressure is less important. With increasing delays to treatment greater numbers of treatment are required to obtain the same or near-same result. Even NBO appears to have a positive effect in some models, but the effect is generally much less than the HBO effect. The consistency of data reinforces the earlier discussion (vide supra) where global ischemia may activate the microcirculation and when this occurs, provides a convenient HBO target, white blood cells, however a great diversity of targets is suggested by the gene studies (Godman et al. 2009). The only exceptions to this conclusion are the Van Meter studies which strongly suggest that HBO pressures of at least 2.8 ATA and ideally 4–6 ATA are necessary for resuscitation from cardiac arrest. Interestingly, this model showed no effect on a derivative pathology of WBC involvement, myeloperoxidase.

Review of Human Clinical Studies

The human HBO experience in cerebral ischemia/anoxia and coma is extensive, complicated, incomplete at times, and spread across multiple medical conditions. Despite the heterogeneous group of studies, the data shows a beneficial effect of HBO, especially in the large series and particularly in traumatic brain injury (TBI).

Since the last edition of this chapter a number of important reviews have been published that support HBO across the time spectrum in pediatric neurologic injury. This data is con-

sistent with previous reports and the above-mentioned animal studies. To facilitate review of the literature all reports have been categorized somewhat arbitrarily by amount of time delay to initiation of HBO. Some reports span multiple categories and are unclear about exact times of HBO intervention. In these a rough estimate was attempted based on the implications and inferences in the study, and references to companion articles. The four categories are hyperacute (less than or 3 h postinsult), acute (4–48 h post), subacute (49 h to 1 month post), and chronic (greater than 1 month after insult).

The studies of Mathieu et al. (1987, 2000), Voisin et al. (1973), Hutchison et al. (1963), Kohshi et al. (1993), Shn-Rong (1995), Larcan et al. (1977), Viart et al. (1970), Hayakawa et al. (1971), Saltzman et al. (1966), Ingvar and Lassen (1965), Baiborodov (1981), Sanchez et al. (1999), and Van Meter et al. (1999a) address the hyperacute period of global ischemia/anoxia and coma. The most clear-cut of these are the studies reported by Mathieu et al. (1987) and Hutchison et al. (1963). Mathieu used HBO in 170 cases of unsuccessful hanging, 34 of whom received NBO and 136 HBO, and found statistically significant greater recovery without sequelae if HBO was delivered <3 h posthanging (85 vs. 56%). Worse coma required more treatment, but even the worst only averaged 3.9 HBOs. The 34 NBO patients were those with minor neurological problems; only patients with impaired consciousness received HBO. The pressure used in this study was 2.5 ATA/90 min. HBO for near hanging had become the standard of care at Mathieu's facility in northern France following installation of the HBO chamber in 1968 and the results of their historically controlled study of 1973 (Voisin). The study compared 14 patients with standard treatment (normobaric oxygen) pre-1968 to 35 patients with HBO after 1968. HBO reduced mortality by 39% and neurological sequelae by 59%. The authors stated that HBO provided "a recovery both quicker and of better quality." This series of 170 patients has been extended to 305 patients (Mathieu et al. 2000) with nearly identical results, again strongly arguing for HBO-responsive pathology within the first few hours of rescue from near hanging. These are similar to the initial results (79%) reported by Hutchison et al. (1963) in resuscitation from neonatal asphyxia, but one-third of those patients regressed after the first treatment. Overall, 54% were discharged from the hospital as "well." HBO was used at 2–4 ATA in this study and treatment was initiated 2–38 min after birth. These findings were replicated by Baiborodov (1981) at 2 to 3 ATA and 1.4–1.5 ATA in 555 infants. Although the HBO protocol is confusing and the details of the paper are limited due to publication of only the abstracts [the manuscripts were too numerous (300) and subsequently lost in a fire at one of the editors' homes] the eight-fold reduction in mortality is compelling and consistent with Hutchison's data. More recently (Sanchez et al. 1999) has reported the same positive findings at 2 ATA in a small

number of infants. Altogether these experiences with HBO in neonatal ischemia/hypoxia/"asphyxia" are remarkable and significantly supported by the animal data, particularly the Calvert et al. (2002) model.

Most of the other papers in this group imply hyperacute and acute treatment or do not state the time of HBO intervention. Kohshi et al. (1993) initiated HBO soon after onset of symptomatic vasospasm in subarachnoid hemorrhage post-neurosurgical comatose patients using 2.5 ATA and an average 10 treatments which decreased subsequent progression to infarcts. Shn-Rong (1995) applied HBO in 336 cases of cardiac arrest, near drowning, unsuccessful hanging, electrocution, carbon monoxide, TBI, and other toxic and asphyxial coma patients, implying at least some treatment hyperacutely, with 75–100% recovery rates at 2–2.5 ATA. Best results were with earlier treatment; delays to treatment required greater numbers of HBOs. Most remarkable was the 62.5% resuscitation from cardiac arrest, a rate far exceeding the resuscitation rate from cardiac arrest in developed countries. In the Larcan et al. (1977) paper it appears that only one patient was treated in the hyperacute period with both urokinase and HBO. The result was excellent and the best in their study, but the effect cannot be necessarily attributed to HBO alone. The Viart et al. (1970) paper does not mention time to HBO in the three cases of infant hepatic coma, but the profile of HBO seemed extreme since 1 patient died of pulmonary oxygen toxicity with 36 h of HBO and the other two experienced cardiac conduction abnormalities during HBO, an extremely rare complication of HBO. Despite the apparent complications, all 3 patients had normalization of consciousness, EEG, and neurological exam with HBO, two permanently and one transiently. Hayakawa et al. (1971) performed a single 2ATA/1 h HBO immediately after surgery on four comatose brain tumor patients and 9 acute TBI patients. The time to initiation of HBO was not stated but was probably <3 h in the postoperative patients. The authors found 3 patterns of CSF pressure and clinical response that corresponded to differential effects on normal and injured brain; HBO decreases edema in injured brain and produces edema in normal brain. Most patients had an initial decrease of CSF pressure with HBO and then return to pre-HBO level at the end of HBO. The patients with a major decrease in CSF pressure during HBO had remarkable clinical improvement and a mild neurological deficit. If there was no change in CSF pressure the reverse was true. The duration of the HBO neurological improvement was not mentioned.

The coma case reported by Ingvar and Lassen (1965) showed a transient rapid awakening of a patient with "failing circulation" but died at the conclusion of a 2–2.5 ATA/1.5–2.5 h HBO. This could be the natural history of the patient's disease and/or an oxygen toxicity effect. The other single case reports are of a "dramatic" near-complete cure of a suspected air embolism patient treated with a 2.36 ATA/5 h ses-

sion of HBO (Saltzman et al. 1966) and the example of AGE, massive DCS, and cardiac arrest (Van Meter et al. 1999a). The Saltzman treatment was similar to the United States Navy Treatment Table VI for air embolism and serious decompression sickness and may explain the near-complete cure without oxygen toxicity after a higher pressure very prolonged oxygen exposure (5 h). The Van Meter case also used a very prolonged deep oxygen exposure, 6 ATA pure oxygen on a modified US Navy TT6A extended to a US Navy TT7 with oxygen breathing periods at 3 ATA. This case spawned the guinea pig and swine resuscitation experiments (Van Meter et al. 1988, 1999b, 2001a, b, 2008). The success of the Saltzman and Van Meter cases are likely due to the large proportion of the pathology caused by intravascular gas. Overall, the preponderance of data in these 14 HBO studies and 1,388 global ischemia/anoxia and coma patients is strongly positive with pressures greater than or equal to 2 ATA and a minimum of 1–7 treatments.

The publication of (Liu Z 2006c) deserves particular attention since it is a review of 20 randomized or "quasi-randomized" controlled Chinese studies. While there are many methodological criticisms of the studies, there is an overwhelming consistency of the results between the 20 studies and with the earlier 14 studies in this category, which show a reduction in mortality and neurological sequelae with HBO in term neonates (>36 weeks gestation) with hypoxic/ischemic encephalopathy. It appears likely that most of the patients treated were beyond the 3 h time limit of this category, falling into the acute category. The pressures used were 1.3–1.7 ATA, which is supportive more of the pressures used in the acute category, particularly for TBI. These lower pressures are similar to the pressure (<2 ATA) used by Baiborodov in his pediatric study.

Thirty-six studies fall into the second or acute category. Once again the preponderance of data is positive, either transiently or permanently, regardless of the etiology of coma. Kohshi et al. (1993), Mathieu et al. (1987), Voisin et al. (1973), Shn-Rong (1995), Viart et al. (1970), and Liu Z et al. (2006c) papers span this and the hyperacute period and were already reviewed. The Larcan et al. (1977) study had one patient in the hyperacute period mentioned earlier and 35 coma patients in the acute period. HBO appeared to have no effect and, in fact, was no different from the medical treatment group, but the data is incomplete, lacking a pure urokinase group and exact times to initiation of treatment. All ten severe coma patients died with lesser coma grades I–III showing the best response to combined urokinase plus HBO, and minimization of time to treatment the best predictor of success. The Saltzman et al. (1966) report also had one patient in both the hyperacute and acute periods. The acute patient had an embolic clot CVA and was treated 5 h post-CVA at 2.02 ATA/>1 h with near total permanent improvement. Lastly, nine TBI patients of (Hayakawa et al. 1971) 13

patients were most likely in the acute period, but the results have already been summed earlier.

Of the remaining 24 studies, 15 were at pressures greater than or equal to 2 ATA (Sharp and Ledingham 1962, Heyman et al. 1966; Mogami et al. 1969, Sukoff and Ragatz 1982, Thomson et al. 1992, Dean et al. 1993; Snyder et al. 1995, Yangsheng 1995, Dordain et al. 1969, Illingworth et al. 1961, Koch 1962, Hsu and Li 1987, Smilkstein et al. 1985, Sheffield and Davis 1976); 10 used 1.5 ATA (Holbach et al. 1974, Holbach and Caroli 1974, Holbach et al. 1977a, b, c; Rockswold et al. 1992; Rockswold et al. 2001; Niu et al. 2009; and Rockswold et al. 2010, 2013); 1 used 1.4, 1.5, or 1.6 ATA; and two used 1.6–2 ATA (Belokurov et al. 1988; Isakov et al. 1982); with near uniform transient or permanent positive results. Four of the ten 1.5 ATA reports (Holbach and Caroli 1974; 1977a, b, c) compared 1.5 ATA to either 2, 2.5, or 2–3 ATA and demonstrated better results at 1.5 ATA, using a variety of clinical, biochemical, and physiological outcome measures. Six of the ten studies (Holbach et al. 1974, 1977a, b, c; Rockswold et al. 1992, 2001) initiated treatment >24 h after injury. Three of these (Holbach and Caroli 1974; Holbach et al. 1977b, c) do not mention time to treatment, but imply treatment in the acute period since the patients are neurosurgical cases and they are reported incidentally in the study on cerebral glucose metabolism in acute brain-injured patients which is a preliminary version of patients who were a “few days” postinjury (Holbach et al. 1977a). The fourth and fifth 1.5 ATA papers of Holbach (Holbach et al. 1977b, c; Rockswold et al. 2010, 2013) span the acute and subacute periods and are similar patients to those in the other Holbach and Rockswold papers, respectively. In Holbach and Caroli (1974) 1.5 ATA had significantly better clinical results than 2–3 ATA. This is confirmed with CBF measurements (Holbach et al. 1977b), EEG (Holbach et al. 1977c), and cerebral glucose metabolism (Holbach et al. 1977a) where 15–30 min excursions to 2 and 2.5 ATA caused deterioration in the measured parameters. While the Holbach et al. (1977a) experiment did not explore pressures between 1.5 and 2 ATA, the Belokurov study affirmed the efficacy of 1.7–2 ATA pressures in 23 comatose children with 100% recovery of consciousness. Their results were maximal in TBI (13 of 23 patients) and if initiated <24 h postcoma. Similarly, Isakov et al. (1982) experienced good results between 1.6 and 2 ATA in patients with cerebrovascular accidents.

The final two studies in this category suggest HBOT benefit in a single case of heat stroke using 1.5 ATA for 6 treatments (Niu et al. 2009) and reaffirm HBO benefit in neonatal ischemic/hypoxic encephalopathy (Zhou, et al. 2008). Zhou, et al. (2008) compared 1.4, 1.5, and 1.6 ATA HBOT 1x/day for 7 days and showed improvement in neonatal behavioral neuro assessment in all groups and an improvement in antioxidant and decrease in lipid peroxidation indices. The great-

est effect on antioxidant defense and least lipid peroxidation was in the 1.6 ATA group. These results are consistent with the Liu Z et al. (2006c) review and suggest a beneficial clinical and biochemical effect of HBOT in neonatal ischemic/hypoxic encephalopathy.

The importance of the studies in the Acute Period is the dominant data on HBOT in acute severe TBI. The Rockswold and Holbach studies deserve special emphasis. Both represent a series of progressive studies by independent neurosurgical groups on the same clinical entity, acute severe traumatic brain injury. Holbach demonstrated the benefit of 1.5 ATA HBOT vs. higher doses of HBOT. Rockswold reaffirmed the benefit of 1.5 ATA and refined the dosing of HBOT. Rockswold et al. (2001) was an elegant follow-up study to Rockswold et al. (1992) to evaluate the cerebral and biochemical physiological effects of 1.5 ATA HBO on acute severe TBI. The authors demonstrated that 30 min total dive time had achieved the maximum reduction of elevated ICP in chamber, one HBO recoupled flow/metabolism in injured brain and reduced lactate levels, and the HBO changes persisted at least six h after HBOT. The importance of the study is its duplication of the Holbach studies’ elucidation of HBO effects on pathophysiology in acute severe TBI and the underpinning of all of the clinical studies, most notably the Rockswold et al. (1992) study with its HBO induced 47–59% reduction in mortality. Rockswold et al. (2010) refined the dosing by investigating the combined effects of HBOT and normobaric oxygen vs. HBOT and normobaric oxygen alone. HBO/NBO had the greatest metabolic improvement without signs of oxygen toxicity. Rockswold et al. (2013) confirmed the clinical benefit of improved metabolic indices with a reduction in mortality and improvement in functional outcomes. The TBI studies of Holbach, Rockswold, and Ren et al. (2001) all demonstrated a 50–60% reduction in mortality and improved clinical outcome with HBOT that emphatically argue for HBO in acute severe TBI. 629 of the 877 patients reviewed in this category (excluding Kohshi, Mathieu, Voisin, Shn-Rong, and Viart) had TBI; the data strongly argues for the routine use of HBO in TBI at 1.5 ATA. Overall, treatment courses tended to be longer in the acute category than the hyperacute, using higher HBO pressures earlier (less than or equal to 24 h) and lower pressures later, with overall positive effects regardless of coma etiology: chemical/toxic gas, trauma, CVA, surgery, etc.

In the third category, subacute (49 h–1 month) 16 studies are presented. The papers of Holbach et al. (Holbach and Caroli 1974; Holbach et al. 1974, Holbach et al. 1977b, c), Larcan et al. (1977), Shn-Rong (1995), Isakov et al. (1982), Belokurov et al. (1988), and Liu Z et al. (2006c) were discussed earlier, but to reiterate, many of the TBI cases of Holbach started HBO 2–10 days postinjury. Results were positive and favored treatment at 1.5 ATA for 1–7 times. Lareng et al. (1973) reported two additional late TBI coma

cases and had excellent outcomes with prolonged treatment at 2.0 ATA. In the Shn-Rong series a number of carbon monoxide cases presented with > 6 days of coma. In general, they required more treatment, and one case of 90 day coma was cured finally with normal EEG after 150 treatments in three stages. Three patients with TBI coma of 10, 20, and 30 days regained consciousness after 7–20 treatments. Almost all except the initial few treatments were at 2 ATA. Two additional TBI studies by (Artru et al. 1976a, b) and a study by Nakamura et al. (2008) had mixed results. The first involved 60 TBI patients 4.5 days postinjury, HBO at 2.5 ATA, and an average 10 treatments with multiple breaks in protocol, and few receiving much treatment in the first week. Only one of nine subgroups (brainstem contusion) achieved significant improvement with HBO (see earlier discussion on penumbra/umbra size considerations in brainstem vs. cortical coma). The second study with 6 patients, 5–47 days postinjury, examined blood flow, metabolism, and CSF biochemistry before and after 2.5 ATA HBO. Results were inconclusive, but arterial partial pressure of oxygen declined in 8 of 9 patients, CSF oxygen remained elevated above baseline for 2 h after HBO, and the authors concluded that HBO has different effects on normal and injured brain circulation. Nakamura studied 7 TBI patients with initial GCS less than or equal to 8 with five 2.7 ATA HBOTs. The sole patient still in coma at time of treatment and 2/6 other patients had unfavorable outcomes, despite group improvement in some non-clinical indices. All three of these studies featured high pressure, 2.5 or 2.7 ATA, later in the course of illness and are consistent with an oxygen toxicity effect as Holbach demonstrated in multiple reports earlier.

In contrast, the randomized, prospective-controlled Ren et al. (2001) study reported significant positive results in acute severe TBI using a high-pressure protocol and intensive dosing of HBOT. The treatment regimen was ten 2.5 ATA/60 min HBO treatments in 4 days, repeated in blocks up to a total of 40 HBO treatments. The patients experienced improvement in BEAM, GCS, and Glasgow Outcome Scale. The results are hard to reconcile with the Holbach and Artru data, and questions are raised about the uneven numbers of patients in the control (20) and HBO (35) groups for a randomized study. Despite this intensive high dose of HBO, there was no report of complications in the study.

The final five studies involve subacute global ischemia or coma cases. (Heyman et al. 1966), subarachnoid hemorrhage with postoperative vasospasm (Kawamura et al. 1988), post-hanging (Satoh et al. 1989), status epilepticus/hypoglycemia (Neubauer and James 1998), and central pontine myelinosis coma status postliver transplant (Zhang, et al. 2009). Heyman did not mention immediate effects at 2.02 ATA, Kawamura noted sustained improvement in SSEPs at 2 ATA, Satoh noted “gradual progress” of his unsuccessful hanging patient, Neubauer found significant progress at 1.5 ATA, and Zhang

noted benefit but does not mention the dose of HBOT. In summary, with delay to treatment of 2–30 days generally positive results are achieved with HBO with a tendency to lower pressures and longer treatment courses.

The final category, chronic (>1 month), now has 22 studies, most of which address pediatric brain injury. Six of these are single cases and the remainder are prospective and retrospective case series, prospective controlled and uncontrolled trials, and a review article. All of the reports used 1.5–2.0 ATA oxygen with most <1.75 ATA, except for Golden et al. (2002, 2006) and Miura et al. (2002), which used 1.25–2.5 ATA (2002) or <2.0 ATA (2006) and 2.0 ATA, respectively, Liu et al. (2009) which used 2.5 ATA, and Jiang et al. (2004), which did not mention pressure. Treatment times were mostly <60 min at depth and extended from 1 to over 500 treatments; most involved 40–80 treatments. The 2nd International Symposium studies were grouped together due to their heterogeneity of subjects, protocols, and hypotheses. For example, the Harch (2002) article addressed and identified oxygen toxicity and/or negative side effects of lower pressure HBO in chronic brain-injured patients with prolonged treatment courses at 1.5 ATA (average 119 treatments) and 1.75 ATA (91 treatments) or early in treatment at 1.75 ATA or greater. In addition, a withdrawal syndrome (4 patients) was described in brain-injured individuals habituated to 1.75 ATA HBO. In two of these four cases the author intervened and truncated the neurological deterioration with additional HBO at a lower pressure. These toxicity findings were reaffirmed by Miura et al. (2002) in a case of delayed neuropsychiatric sequelae from drug overdose complicated by hypoxia. The patient recovered acutely then deteriorated to akinetic mutism. The authors initiated HBO at 2.0 ATA/ 90 min and the patient improved then worsened during prolonged HBO, identical to cases in Harch (2002). The behavioral problems slowly abated upon cessation of HBO, but his cognitive decline continued. The case suggests overtreatment with HBO resulting in transient and permanent negative side effects against a background of permanent clinical improvement. MRI FLAIR, MRS, and EEG tracked the clinical course in a manner that was almost identically to the SPECT findings in the cases of Harch (2002). The Liu report is difficult to reconcile with this body of data in that the patients were treated at 2.5 ATA for 60 treatments. Nevertheless, Liu reported improvement in his patients.

The Churchill Study (2013) deserves special mention because it was a prospective study with numerous and detailed functional outcome measures that was designed to test feasibility and to replicate the functional imaging and clinical outcomes reported by Neubauer and Harch in multiple case series and case reports. The study utilized the same 1.5 ATA/60 min dose of HBOT used by Neubauer and Harch, but for only 60 HBOTs instead of the blocks of 40 (typically 80) used by Harch in the Perfusion/Metabolism Encephalopathy Study from 1994

to 1999 (Harch 2010). The majority of patients were survivors of severe anoxia, stroke, or TBI. The results generally duplicated the results reported by Neubauer and Harch with symptomatic improvement, some cognitive and speech improvement, and importantly, functional imaging improvements with the same pattern of normalization of blood flow seen in SPECT images in this text (Harch et al. 1996b; Harch and Neubauer 1999, 2004, Neubauer et al. 2004) and other publications (Harch, et al. 2012, all Neubauer studies earlier). The article concluded that clinically significant improvements were not achieved, but this may be more a reflection of the authors' definition of significant clinical improvement. Patients with chronic neurological residua from severe anoxic, ischemic, and traumatic injuries have lost significant amounts of brain tissue. Although HBOT has trophic stimulatory effects through gene modulation it is unreasonable to expect reinnervation of significantly denervated brains in 3 months, especially long white matter tract growth. It suggests that more treatment and a longer followup may generate further gains.

One of the most important additions to this category is the (Senechal report 2007). This study is described in detail in the chapter on cerebral palsy. In short, improvements in gross motor functional measures were the highest, fastest, and most durable in HBOT studies compared to studies using the GMFM for other types of therapies with the exception of two dorsal rhizotomy studies. The second important addition is the Golden et al. (2006) study, a controlled nonrandomized study of HBOT in a group of children and adults with chronic stable brain injury. Both groups showed significant improvements in nearly all measures after 28–35 HBO treatments at low pressure.

In conclusion, additional experience with HBO in chronic global ischemia, anoxia and coma that was supported by SPECT, standardized motor, and psychometric testing has accumulated in the past 5 years, strongly suggesting a positive trophic effect of HBO. These results are underpinned by the addition of the sole animal study in the literature that demonstrated a highly correlated improvement in vascular density and cognition using an HBO protocol originally designed for humans and used in many of the human studies earlier (Harch et al. 2007). This animal study strongly reinforces the human studies, especially in TBI, and argues for further application of HBO to other chronic forms of brain injury. The consistent findings in all of these studies in the late period were recovery of consciousness and that the longer to initiation of HBOT in patients with persistent coma, the less likely is recovery of consciousness.

Case Studies

To illustrate the effect of HBO in both acute and chronic global cerebral ischemia/anoxia and coma several cases treated by these authors are presented later. In each case the

visual medium of SPECT brain blood flow imaging on a high resolution scanner (7 mm; Picker Prism 3000) registers in a global fashion the neurocognitive clinical improvement experienced by the patients and witnessed by the authors. The SPECT brain scans presented later are CT technology with the patient's left brain on the reader's right and vice versa, with the 30 frame images registering transverse slices from the top of the brain in the left upper corner to the base of the brain in the lower right corner. Images are approximately 4 mm thick. Brain blood flow is color coded from white-yellow to yellow to orange to purple, blue and black from highest brain blood flow to lowest. Normal human brain shows predominantly yellows and oranges, but, more importantly, has a fairly smooth, homogeneous appearance. The companion image (B) to the 30 slice transverse set of images is a three-dimensional surface reconstruction of the transverse images. Abnormalities in perfusion are registered as defects and as coarseness of the brain's surface.

Patient 1: HBO Treatment for Coma Due to Traumatic Brain Injury

A 19-year-old male was inadvertently ejected from a motor vehicle at 65 mph with impact on the left frontal/parietal region of the skull. Within one-half hour Glasgow coma scale was 6–7 and the patient was ventilator dependent. CT of the brain revealed diffuse edema, midline shift, petechial hemorrhages, subarachnoid hemorrhage, small subdural hematoma, and basilar skull fracture. HBO was given 19 h postinjury at 1.75 ATA/90 b.i.d. On the first treatment the patient began to fight the ventilator. Initial SPECT brain imaging obtained 5 days postinjury on a single-head low-resolution scanner was "normal." Repeat SPECT imaging on a triple-head high-resolution scanner occurred 30 days postinjury (Fig. 20.1a, b) and now clearly demonstrated the significant injury to the left frontal area as well as the contra coup injury to the right parietal/occipital area characterized by luxury perfusion. Nine days later and two hours after a fifth additional HBO, SPECT was repeated (Fig. 20.2a, b) and showed a dramatic "filling in" of the injured areas thus giving functional neurophysiological support to the clinical decision to continue HBO. The patient, meanwhile, progressed rapidly on twice daily HBO for 4 weeks with often new neurological or cognitive findings occurring in the chamber and then continued on HBO 4 times a day for 7 weeks, at which time he was conversant and independently ambulatory with slight spasticity. At 11 weeks the patient was transferred to a rehabilitation center and his HBO discontinued by the new medical team. SPECT imaging at this time (Fig. 20.3a–c) registers the patient's clinical progress with a persistent increase in flow to the left frontal region while some deterioration occurs to the area of previous

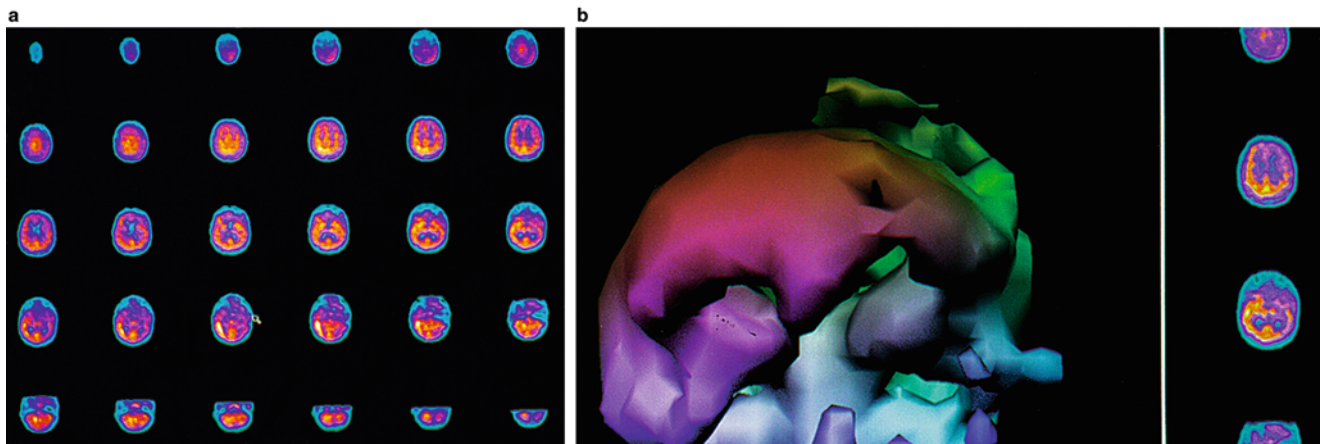


Fig. 20.1 (a) HMPAO SPECT brain imaging, transverse slices, 1 month postinjury. Note severe reduction in left frontal, parietal, and temporal brain blood flow with luxury perfusion in the right occipital

parietal region. (b) Frontal projection three-dimensional surface reconstruction of Fig. 20.1a. Noncerebral uptake is shown in scalp and neck soft tissues

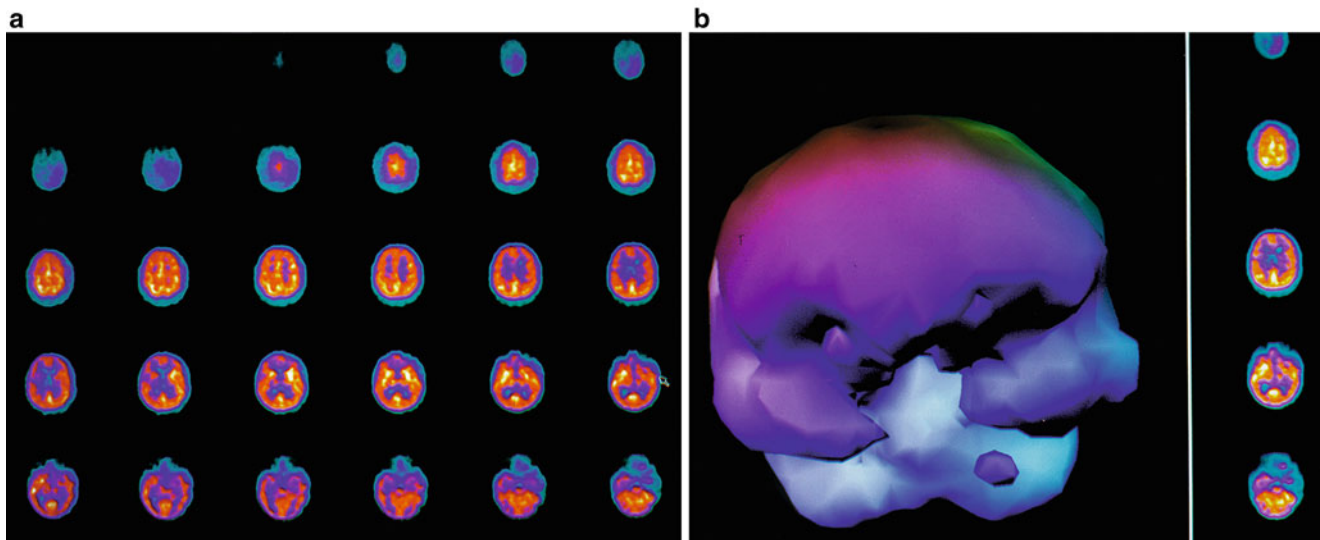


Fig. 20.2 (a) HMPAO SPECT brain imaging, transverse slices, 9 days after Fig. 20.1a, b and 2 h post 5th additional hyperbaric treatment. Note improvement in flow to the left frontal, parietal, and temporal

regions while defects begin to appear in the right frontal and parietal area. Luxury perfusion is no longer evident. (b) Frontal projection three-dimensional surface reconstruction of Fig. 20.2a

luxury perfusion on the posterior right. The patient made transient limited initial progress at the rehabilitation center then quickly leveled off cognitively while his spasticity and balance worsened. Three months after discontinuance of HBO the patient's father requested further HBO and repeat SPECT brain scan (Fig. 20.4a, b), psychometric, and motor testing were obtained. SPECT now demonstrates a significant deterioration in the right frontal and posterior areas, while the left frontal normalization persists. The right posterior area has infarcted on simultaneous MRI. To assess recoverable brain tissue the patient underwent a single 1.75 ATA/90 min HBO followed by SPECT imaging (Fig. 20.5a, b); SPECT showed improvement in the right frontal and parietal/occipital lesions along the ischemic penumbral

margins. HBO was resumed for an additional 80 treatments, once/day at 1.75 ATA/90 min. The patient made a noticeable improvement in cognition (40 percentile gain in written computational mathematics), insight (the patient now verbalized for the first time the understanding that he had sustained a brain injury and could no longer aspire to be a surgeon), and balance (improvement in gait and progression from a 3-wheel tricycle to a 2-wheel bicycle). HBO (188 treatments total) was discontinued when the patient desired enrollment in remedial courses at a community college. SPECT imaging at this time (Fig. 20.6a, b) shows improvement in perfusion in the ischemic penumbral areas of the right-sided lesions. The left hemisphere remains intact. In summary, HBO, when reinstated following SPECT and

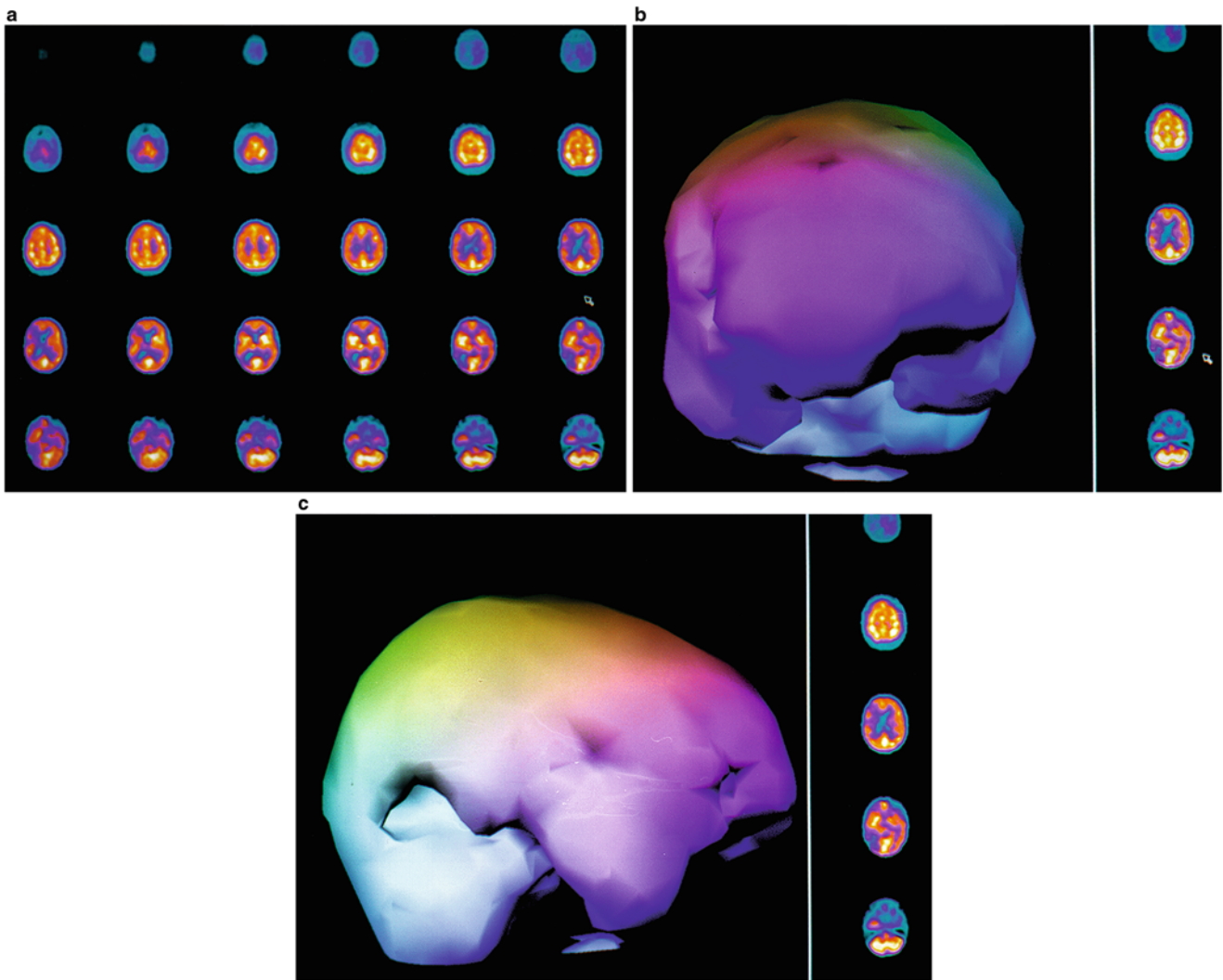


Fig. 20.3 (a) HMPAO SPECT brain imaging, transverse slices, 11 weeks and 108 hyperbaric treatments postinjury. Note maintenance of perfusion in the left frontal, parietal, and temporal regions with further progression of

defects in the right frontal-parietal and posterior parietal-occipital areas. (b) Frontal projection three-dimensional surface reconstruction of Fig. 20.3a. (c) Right lateral projection three-dimensional surface reconstruction of Fig. 20.3a

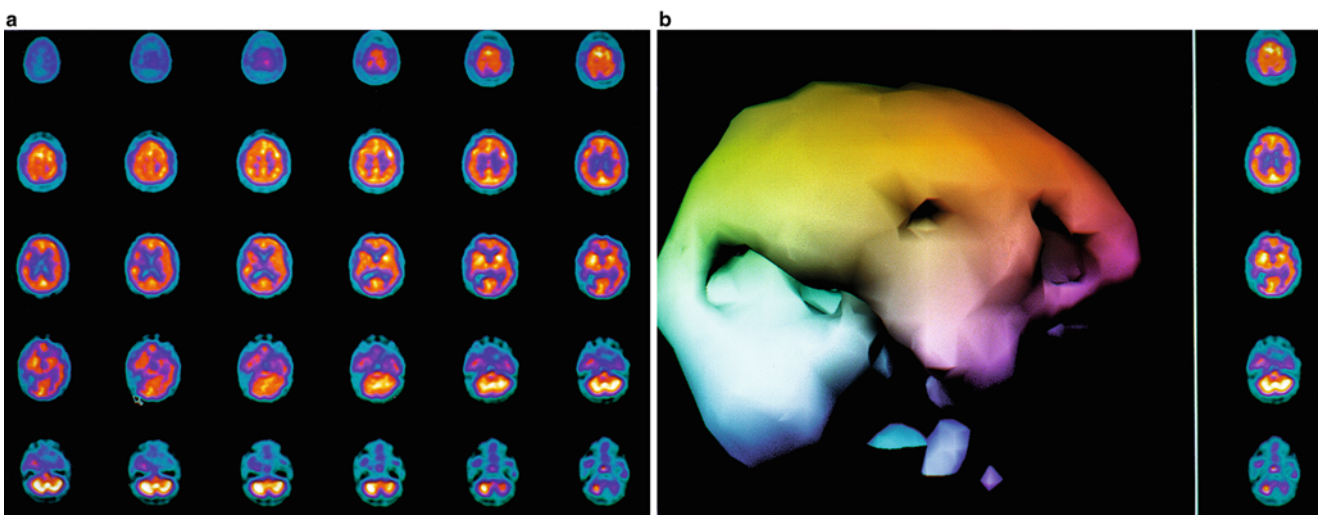


Fig. 20.4 (a) HMPAO SPECT brain imaging, transverse slices, 3 months after Figs. 20.3a–c. Left frontal, parietal, and temporal perfusion is main-

tained with further deterioration of the right frontal and posterior defects. (b) Right lateral projection three-dimensional surface reconstruction of Fig. 20.4a

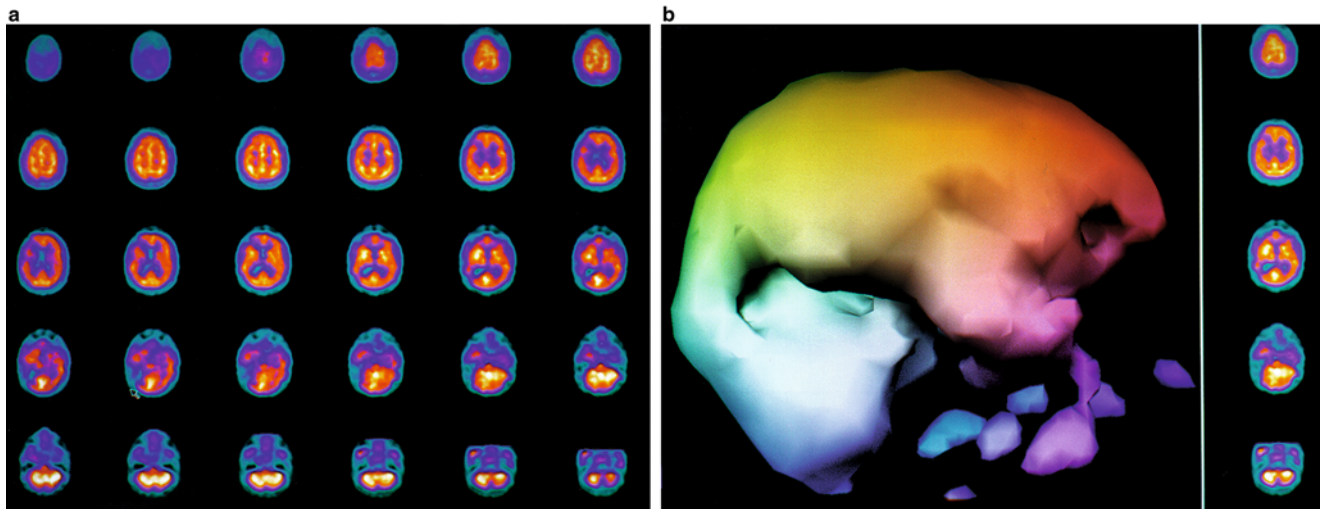


Fig. 20.5 (a) HMPAO SPECT brain imaging, transverse slices, 2 h following single HBO at 1.75 ATA/90 min. Note improvement in the

right frontal and posterior defects. (b) Right lateral projection three-dimensional surface reconstruction of Fig. 20.5a

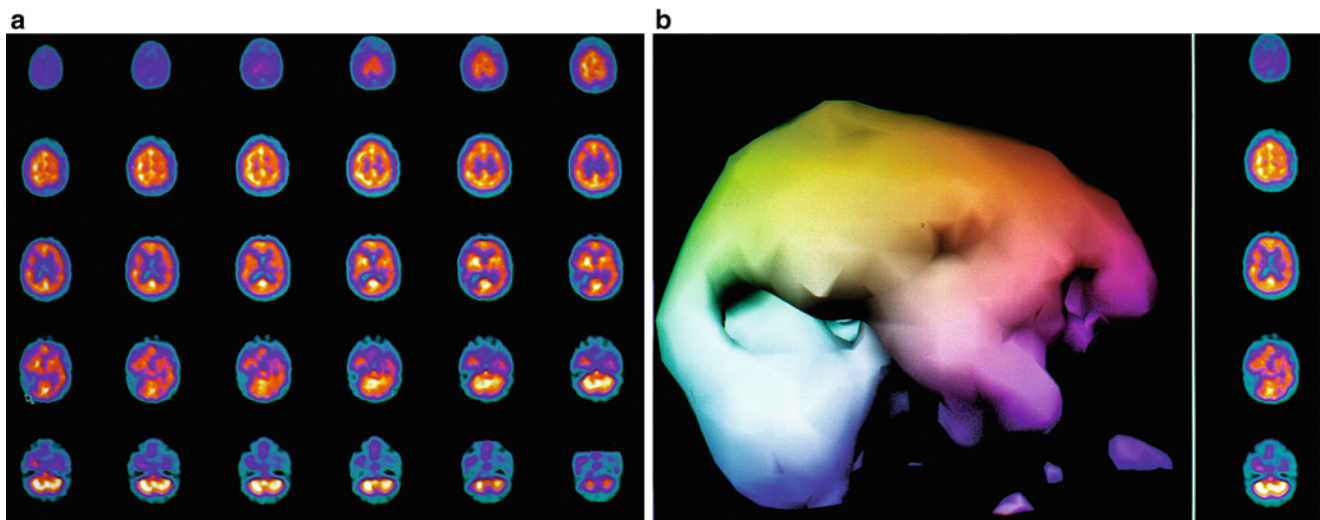


Fig. 20.6 (a) HMPAO SPECT brain imaging, transverse slices, 5 months and 80 HBO's after Fig. 20.4a. Note improvement in flow to the

ischemic margins of the right frontal and posterior defects. (b) Right lateral projection three-dimensional surface reconstruction of Fig. 20.6a

relapse after discontinuation of HBO, prevented further deterioration and improved SPECT image as well as neurocognitive function in TBI, demonstrating the benefit of HBO in the chronic stage of TBI. To see a video of this case from the day of injury go to: https://www.youtube.com/watch?v=OM_omRuWYC4.

Patient 2: Near Drowning, Chronic Phase

The patient is a 4-year-old male who was found at the bottom of a swimming pool after an estimated 5 min of submersion. Resuscitation measures were instituted and a pulse was regained 45 min after removal from the pool. Two years after

the injury, the patient was wheelchair bound with significant motor disabilities, inability to speak and communicate, and problems with drooling, attention span, and swallowing. SPECT brain imaging was performed on a high resolution scanner before (Fig. 20.7a, b) and 2 h after (Fig. 20.8a, b) a session of HBO at 1.5 ATA/60 min. The baseline scan in Fig. 20.7a shows a severe reduction in blood flow to the frontal lobes, while Fig. 20.8a shows a generalized improvement in brain blood flow, particularly to the frontal lobes, and denotes recoverable brain tissue after the single hyperbaric treatment. The patient embarked on a course of 80 hyperbaric treatments at 1.5 ATA/60 min one time/day, 5 days per week with a 3 week break at the 40 treatment point. At the end of 80 treatments, he returned for evaluation and was noted to have a generalized

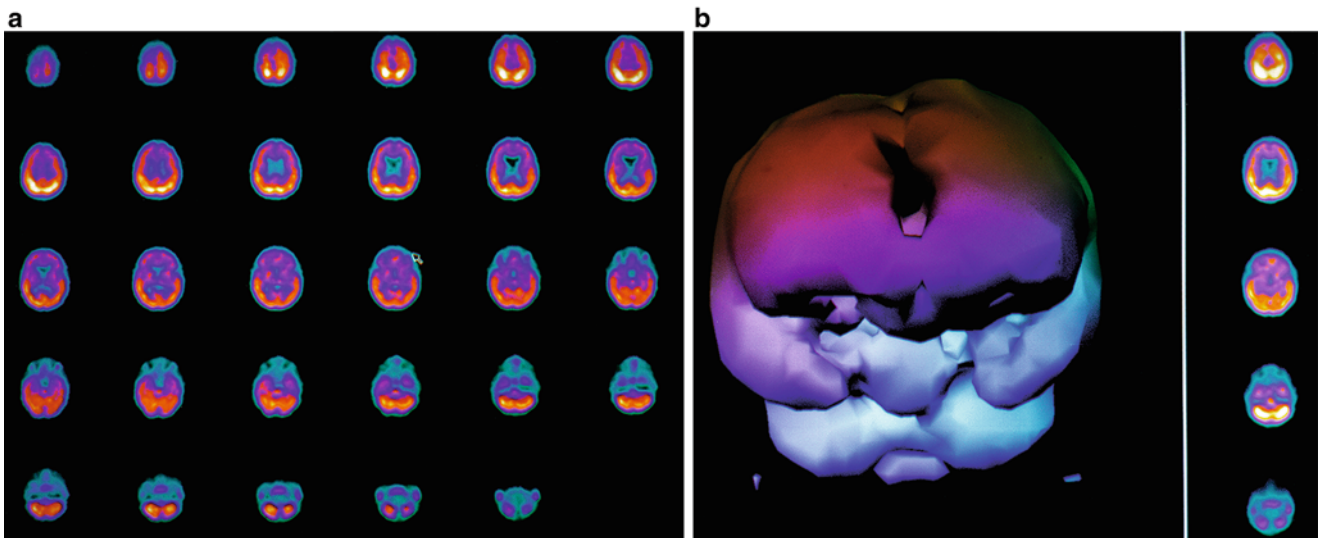


Fig. 20.7 (a) HMPAO SPECT brain imaging transverse slices, baseline study 2 years status post near drowning. Note considerable reduc-

tion in frontal blood flow. (b) Frontal projection three-dimensional surface reconstruction of Fig. 20.7a

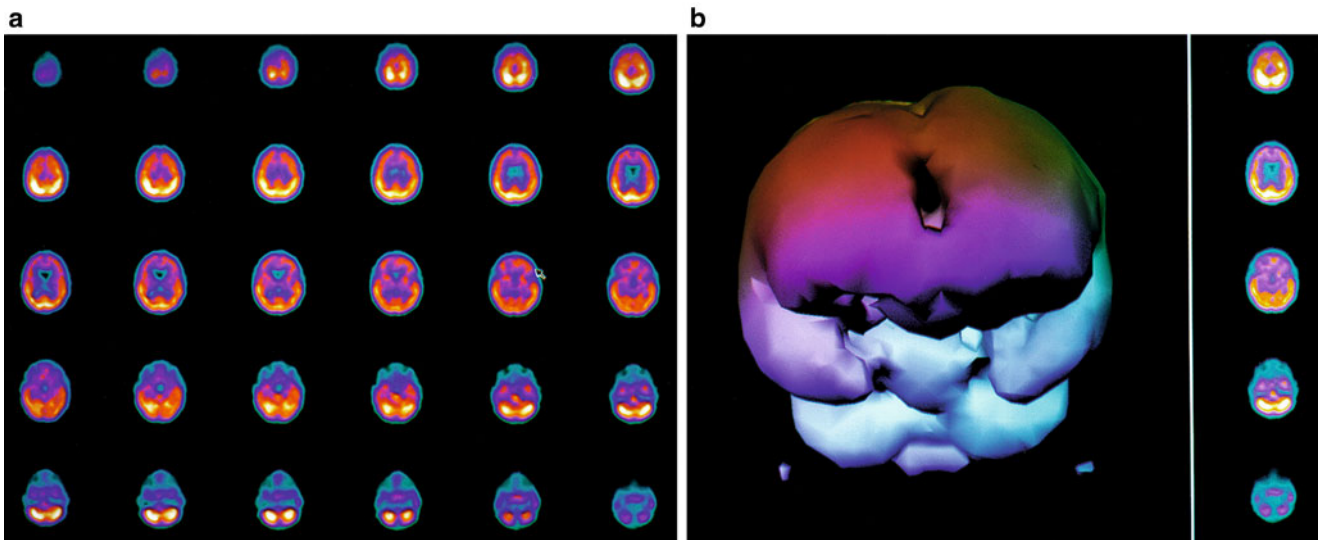


Fig. 20.8 (a) HMPAO SPECT brain imaging, transverse slices, 1 day after Fig. 20.8a and 2 h following single HBO at 1.5 ATA/60 min. Note diffuse increase in perfusion to the frontal lobes and improvement in

overall brain blood flow. (b) Frontal projection three-dimensional surface reconstruction of Fig. 20.8a

improvement in spasticity, movement of all 4 extremities, increase in trunk and head control as well as improvements in swallowing, awareness, nonverbal communication, and attention span. There was a global increase in blood flow on SPECT brain imaging performed at that time (Fig. 20.9a, b).

Patient 3: Near Drowning, Chronic Phase

Case 3: The patient is a 4-year-old boy who is 2 years status post 30 min submersion in a pond. Resuscitation regained a pulse 45 min after removal from the water. Two years later, the child is severely disabled with almost no cognition, frequent postur-

ing, inconsistent tracking, extreme difficulty swallowing fluids, choking, and 10 petit mal seizures a day. Baseline SPECT brain imaging is shown in Fig. 20.10 with prominent abnormalities in the inferior frontal lobes. The patient underwent a single HBO at 1.5 ATA/60 min with repeat SPECT imaging 2 h after chamber exit (Fig. 20.11). A generalized improvement in flow is noted, particularly to the frontal lobes, identifying potentially recoverable brain tissue. The patient underwent a course of 80 hyperbaric oxygen treatments at 1.5 ATA/60 min QD, 5 days per week with approximately 1 month break after 40 treatments. On return evaluation, SPECT brain imaging was repeated (Fig. 20.12). Improvement in frontal lobe blood flow is noted over the baseline scan. The child exhibited greater awareness,

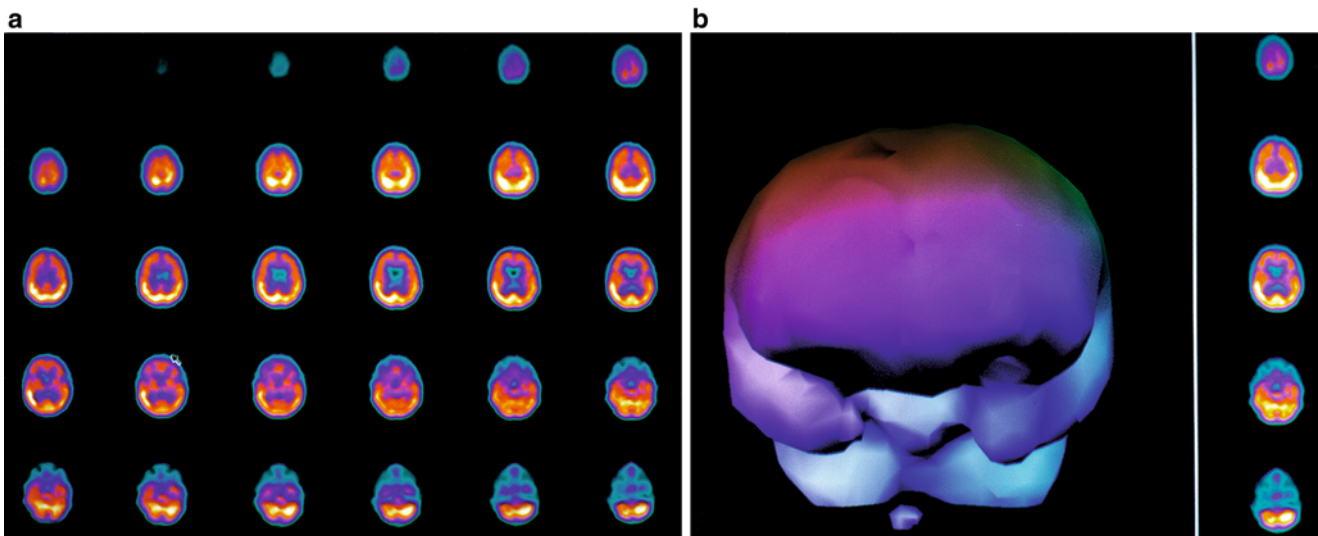
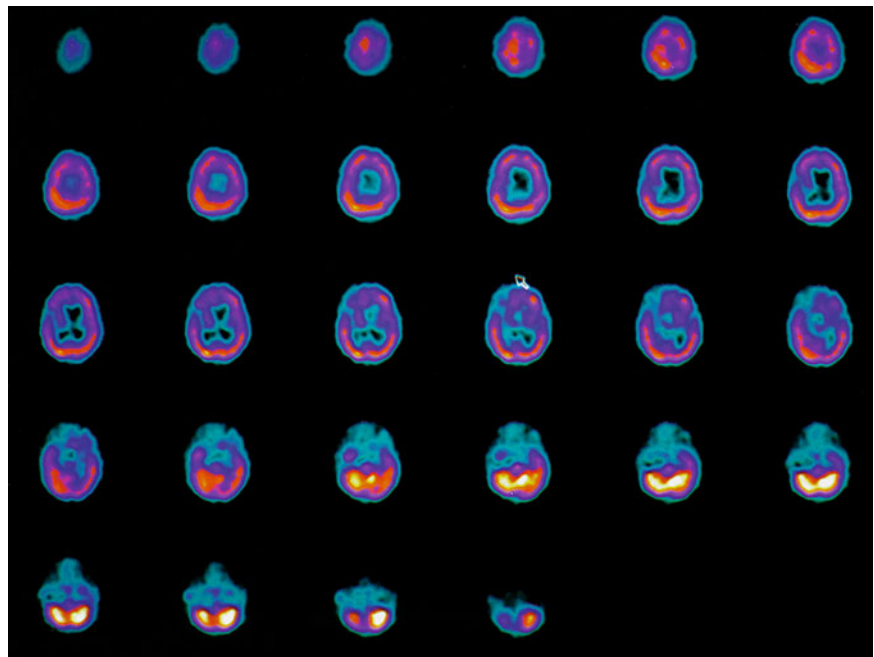


Fig. 20.9 (a) HMPAO SPECT brain imaging, transverse slices, 4 months and 80 HBO's following Fig. 20.9a. Note persistent increase in perfusion to the frontal lobes. (b) Frontal projection three-dimensional surface reconstruction of Fig. 20.9a

Fig. 20.10 HMPAO SPECT brain imaging, transverse slices, baseline study 2 years post near drowning



control of his head, eye tracking, alertness, nonverbal communication, performance of some simple commands, improvement in swallowing, and decrease in seizure frequency.

Patient 4: Battered Child Syndrome

Case 4: The patient is a 6-month-old girl who was slammed against the mattress of her crib by her father on multiple occasions over a 4-day period at 2 months of age. One of the first episodes was characterized by a short period of

apnea; paramedics arrived at the house and found the child to be apparently normal. Three days later another episode of shaking ended with deliberate suffocation and cardiac arrest. Resuscitation was complicated by multiple recurrent arrests en route to and at the hospital. CT of the brain revealed bilateral subdural hematomas and subarachnoid hemorrhage and CT of the cord, L1 to L4 subdural hematoma. The child was ventilator dependent for 12 days. Seizures developed. Repeat CT 18 days after arrest showed severe diffuse encephalomalacia, bilateral infarcts, and bilateral hemorrhages with sparing of the basal ganglia,

Fig. 20.11 HMPAO SPECT brain imaging transverse slices 1 day after Fig. 20.10 and 2 h after a single HBO treatment at 1.5 ATA/60 min. Note generalized improvement to frontal lobe brain blood flow

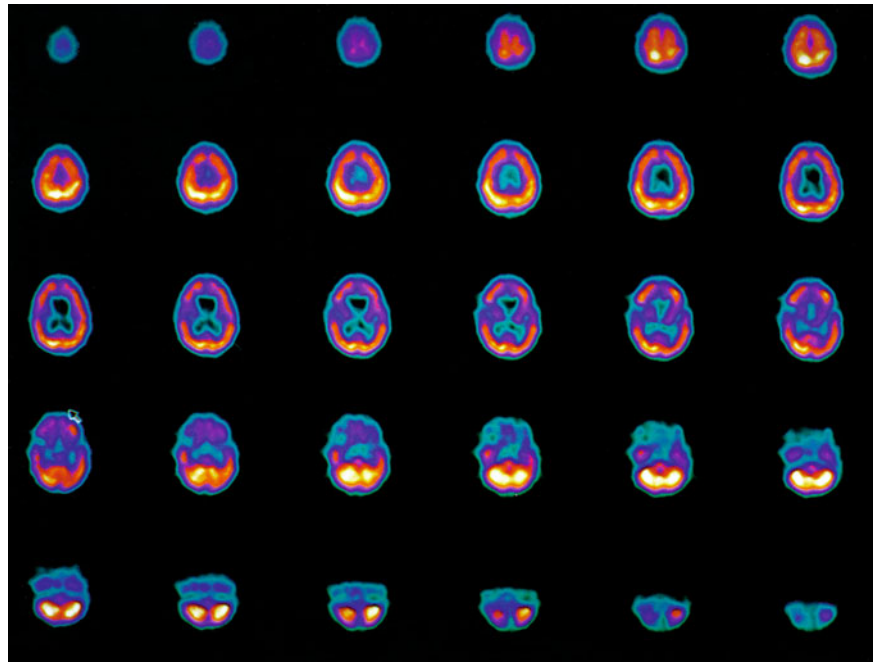
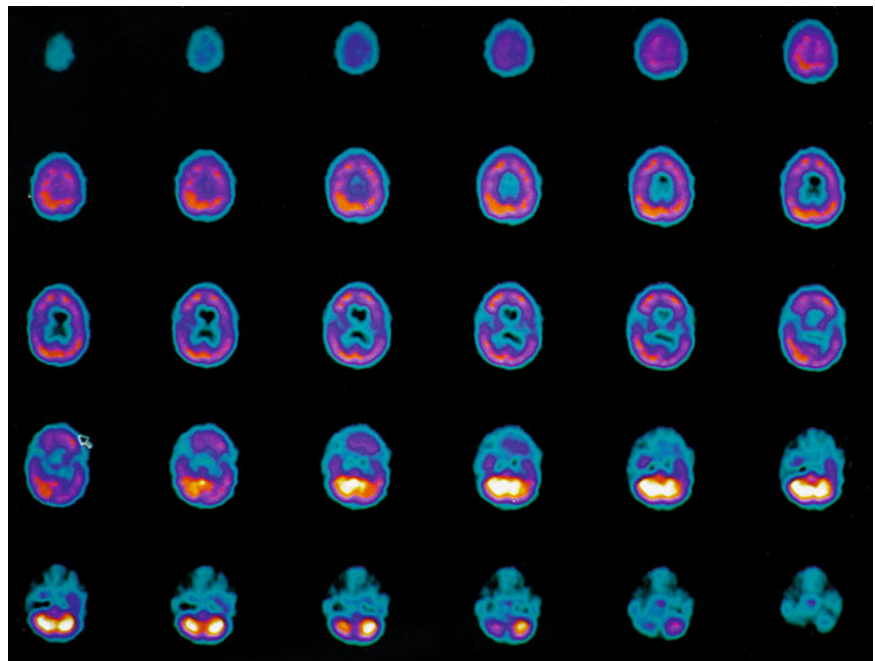


Fig. 20.12 HMPAO SPECT brain imaging transverse slices 4 months and 80 HBO treatments after Fig. 20.10. Note persistent improvement to blood flow to the frontal lobes over baseline scan of Fig. 20.10a



posterior fossa, and brainstem. EEG showed seizure activity on a background of minimal electrical activity. The mother unsuccessfully sought HBO therapy. Four months after the injury the child was stable enough to travel to New Orleans where she was found to be paraplegic with rectal prolapse secondary to loss of sphincter tone. She was unable to suck and was dependent on a feeding tube. She had 5–8 seizures/day and was unable to interact socially. The patient received 38 HBO sessions at 1.5

ATA/60 min TDT, 5 days/week with progressive neurological improvement. She was more awake and aware, starting to interact with her mother, had better head control, use of her arms, and no seizures. SPECT brain imaging reflects this improvement in Fig. 20.13; baseline scan is on the right and one after 38 HBOs is on the left. There is a remarkable diffuse increase in cortical blood flow after HBO with a relative absence of flow on the baseline scan, consistent with the EEG.

Fig. 20.13 ECD SPECT brain imaging transverse slices. Baseline study is on the right and after 38 HBO treatments on the left. Note the predominant thalamic, midbrain, brainstem, and posterior fossa flow and lack of cortical flow on the first study which is augmented by cortical flow on the after HBO study

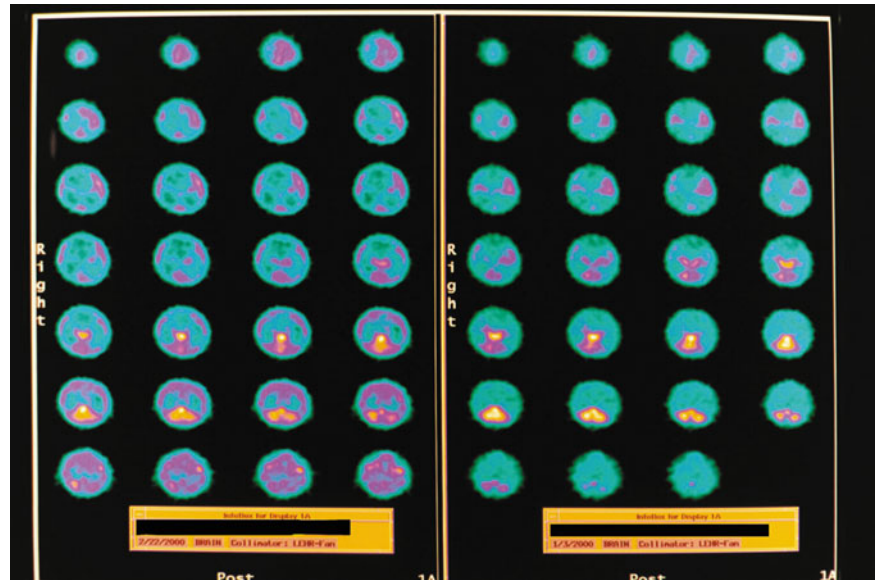
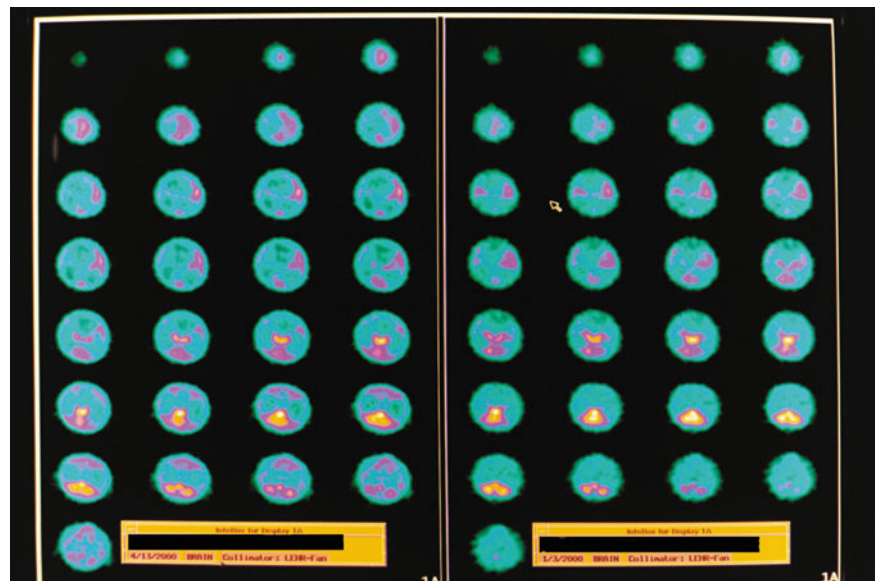


Fig. 20.14 ECD SPECT brain imaging transverse slices. Baseline study is on the right again and study after 80 HBO treatments is on the left. Note the improvement in cortical blood flow after HBO



The day after her 38th HBO treatment the patient began a four-week phenobarbital taper. HBO was reinstated at 1.5ATA/60 q.d., six treatments in 5 days/week for 42 more treatments (total of 80 HBO treatments) 2 weeks into the taper. By the 80th HBO treatment, the patient had begun a phenytoin taper, was eating baby food, had been weaned off Propulsid for her reflux disorder, was much more alert, had increased motor activity, truncal balance, improved social interaction/early smile, much less irritability, a return of rectal tone, and resolution of rectal prolapse, but was still paraplegic. Repeat SPECT brain imaging after 80 HBO treatments again captures this increased clinical activity with increased cortical blood flow in Fig. 20.14 (baseline scan is again on the right and after 80 HBO treatments on the left). Three-

dimensional surface reconstructions of the three scans are shown in chronological order in Figs. 20.15, 20.16, and 20.17. Repeat EEGs after 65 HBO treatments (patient off phenobarbital, now only on phenytoin) and 1 month after her 80th HBO treatment (off all anticonvulsants) showed no seizure activity. EEG also showed new background rhythm and bursts of frontal activity.

Conclusion

There are several causes of coma and global cerebral ischemia/anoxia. HBO has been used in a variety of animal models and in over 2800 patients with these conditions worldwide.

Fig. 20.15 Frontal projection three-dimensional surface reconstruction of baseline study in Fig. 20.13. Note the relative absence of cortical and striatal flow

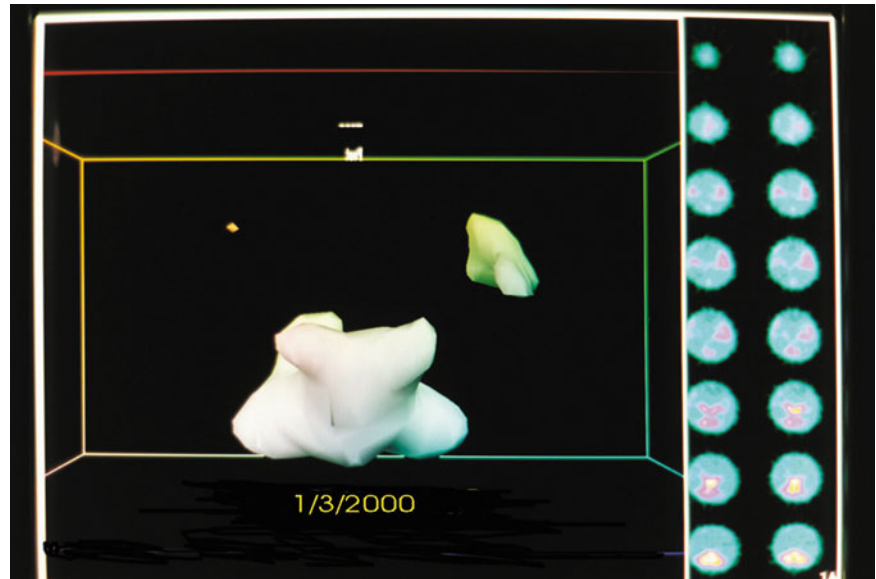
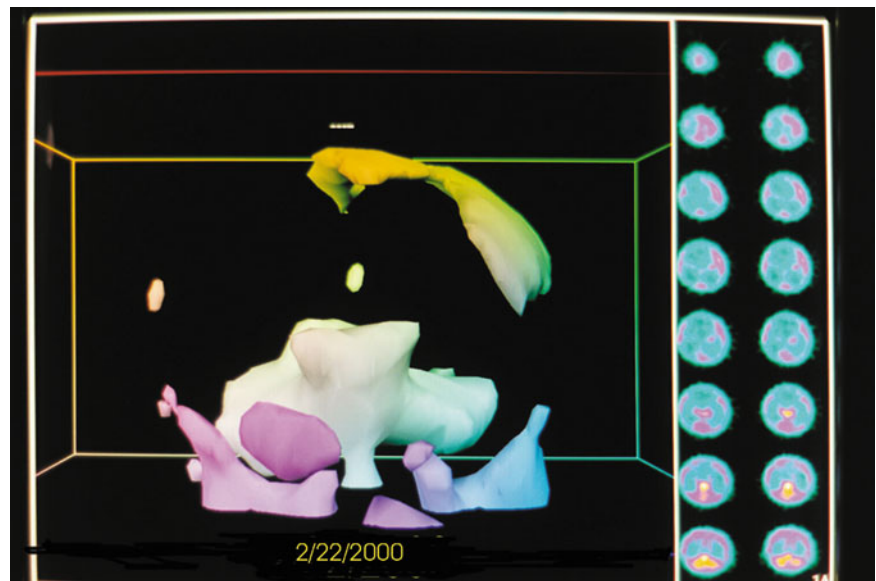


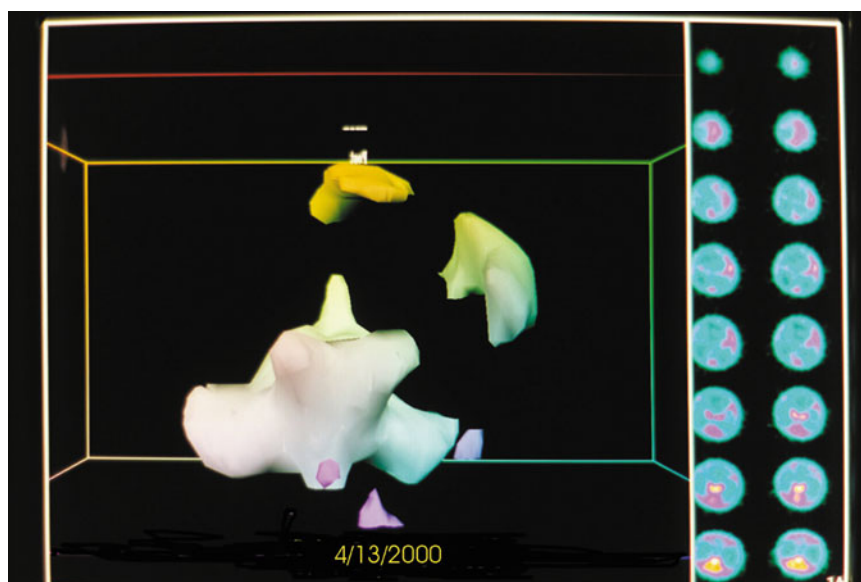
Fig. 20.16 Frontal projection three-dimensional surface reconstruction of second study (after 38 HBO treatments) in Fig. 20.13. The patient has developed some cortical blood flow



Although HBO protocols have varied, the results have been remarkably consistently positive with improvement in a variety of physiological and biochemical measures and outcomes, the most important of which was improvement in overall clinical condition and consciousness. This consistent success rate suggests a generic effect of HBO on common brain pathophysiological processes at different stages in global ischemia/anoxia and coma. Importantly, this review excluded thousands of cases of acute carbon monoxide (CO) coma in the medical literature treated with HBO because of the confusion over HBO effects on the metabolic poison and COHb dissociation vs. hypoxia and other pathophysiology. No doubt hypoxia is a major contributing insult to the patient's overall condition in CO and reperfusion injury is a significant component of the pathophysiology, and both of these are treated

definitively by HBO early after extrication, but many patients arrive for HBO hours after extrication (Thom et al. 1995; Goulon et al. 1969; Raphael et al. 1989), adequately oxygenated, with low or normal COHb levels, and outside the 45 min HBO window identified in Thom's rat model of CO reperfusion injury. Clearly, HBO is effective treatment for CO coma, irrespective of COHb and hypoxia, and it is acting on yet unidentified pathological targets (see Chap. 13). Cerebral arterial gas embolism (CAGE) of diving and nondiving etiology (thousands of cases) similarly was excluded because of the argument that bubbles are the primary pathophysiological target and not ischemia/hypoxia (for discussion see Chap. 12). It has been proposed that most bubbles in CAGE/cerebral decompression sickness have passed the cerebral circulation by the time of HBO and the primary pathological target of

Fig. 20.17 Frontal projection three-dimensional surface reconstruction of third study (after 80 HBO treatments) in Fig. 20.13. Note persistence of cortical blood flow



treatment is reperfusion injury which is responsive to HBO (Harch 1996). In conclusion, the collective experience of HBO in many of the cases of coma due to CO (especially with delayed treatment 6 h or so) and CAGE is strongly positive and further bolsters the earlier conclusion on usefulness of HBO in coma and global ischemia/anoxia.

Another conclusion drawn from this review is that the earlier the HBO intervention the more impressive the results. In particular, if HBO is instituted within about 3 h of cerebral insult, over 75% of patients will be noticeably improved or cured. This finding very strongly suggests targets that are both inhibited and stimulated by oxygen. A single hyperacute HBO greater than or equal to 2 ATA is possibly quenching an on-going injurious cascade, reenergizing stunned neurons similar to the hibernating myocardium reactivation by HBO (Swift et al. 1992), and simultaneously reversing any hypoxia or anoxia. The best examples of this are the resuscitation experiments of (Van Meter et al. 1988, 1999b, 2001a, b) and (Calvert et al. 2002). The Van Meter experiments resuscitated arrested animals 25 min after arrest and truncated brain lipid peroxidation, but had no effect on any white blood cell mediated pathology. The Calvert experiment was a neonatal asphyxia model which inhibited apoptosis. When ischemia is incomplete, prolonged, or treatment is delayed >45 min HBOT likely inhibits reperfusion injury as demonstrated by the animal data of Thom, Zamboni, and other models (Harch 2000).

As treatment is delayed to 6 h, pressures above 2 ATA are still very effective, but they lose their effectiveness as delays approach 24 h. At this time lower pressures and more treatment are required and suggest treatment of different pathology. Most of the data in this time period derives from TBI studies performed at 1.5 ATA; the results show a dramatic reduction in mortality. With delays longer than 1 month, HBO assumes a

trophic role stimulating brain repair and possibly manipulating brain blood flow and metabolism as demonstrated in the Harch et al. (1996a) animal study, which was replicated in Harch et al. (2007). In both of these experiments (same model, larger numbers in the 2007 experiment) a human low pressure (1.5 ATA) protocol successfully employed from 1990 to 1994 was applied to rats with chronic traumatic brain injury. A series of 80 HBO treatment improved cognition and increased blood vessel density in the injured hippocampus. This study duplicates the known trophic effect of HBO in chronic shallow perfusion gradient radionecrosis head wounds (Marx et al. 1990) and likely underpins the mechanism of action of HBO in the multiple subacute and chronic neurological conditions reported in this chapter.

A more obscure point from this chapter that merits attention is the suggestion of an upper limit to HBO dosing in chronic brain injury (Harch 2002). Acute oxygen toxicity (overdose) is well known in HBO such that proper dosing requires a balance of therapeutic benefit with a minimum of negative side effects. Oxygen toxicity in chronic brain injury at pressures <2 ATA has been considered nonexistent in clinical HBO. The 35 examples in the Harch (2002) article and the case of Miura et al. (2002) suggest the opposite in a dose-response fashion. In general, this is consistent with the known oxygen toxicity inverse relationship of pressure and duration at pressure, but this finding requires further confirmation by other authors.

HBO in acute cerebral ischemia/anoxia and coma appears to satisfy the cardinal rule of medicine, *primum non nocere*. In the multitude of cases earlier and those not reviewed (CO and CAGE) the incidence of serious side effects of HBO is surprisingly small. In one review of nearly 1,000 CO poisoned patients (Hampson et al. 1996), the maximum seizure frequency was 3% and only occurred at the highest pressures,

2.8–3 ATA, which is greater than the pressure in the great majority of the human studies in Table 20.2. The rate dropped tenfold to 0.3 % with pressures of 2.4 ATA. These facts alone argue overwhelmingly for a reasonable attempt, without endangering patients in transport, to perform HBO in acute cerebral ischemia/anoxia and coma, especially where no other treatment modality exists or has shown clearcut superiority. In essence, HBO is a simple treatment with potentially profound impact after a single hyperacute administration on devastating incurable neurological conditions that generate monumental long-term tolls of material and human capital and suffering. An increasing number of animal and human experiments/articles are drawing attention to this potential.

HBO in acute cerebral ischemia/anoxia and coma satisfies the second cardinal rule of medicine—treat until the patient no longer benefits from treatment. In many of the hyperacute and acute studies HBO benefit was observed on the first or second treatment and was a prelude to further improvement with 1–2 weeks of treatment. The advance in care levels of such patients makes a powerful cost/effectiveness argument from human and financial perspectives. Unfortunately, the tradition in hyperbaric medicine has been to treat once or twice based on the US Navy’s miraculous early results with hyperacute treatment of decompression sickness and air embolism, results not attained equally in the sport scuba diving arena. This stereotyped thinking has subsequently governed the approach to treatment of carbon monoxide poisoning, stroke, and other neurological maladies, ignoring the fact that HBO initiated at different times after a neurological insult is treating different neuropathology as has been discussed in this chapter. Such an approach may explain the limited positive results of (Saltzman et al. 1966; 11 of 25 patients with temporary improvement after single HBO), and (Rockswold et al. 1992; 47–59 % reduction in mortality with 21 treatments, but no long term effect on functional outcome), among others. The greater consideration of the fixed HBO approach to neurologic injury and the finite, predetermined endpoint of the prospective controlled clinical trial is raised by asking the question of why stop HBO when the patient is continuing to benefit from treatment or showing neurological gains in the chamber at depth (see Patient 1). New neurological activity at depth strongly suggests ischemic neurological tissue, e.g., ischemic penumbra that would benefit from further HBO. This arbitrariness is most evident in DCI and CO poisoning where after 5–10 treatments a treating physician is asked how he knows that the patient would not continue to improve on his own. No one knows for sure with each individual case. However, we ask why this factor is not considered at the outset, or after the 2nd, 4th, 7th, 11th, or any other subsequent HBO treatment when the patient is making stepwise improvement with each or a few HBO treatments, it is known that it takes at least 1 year for a human tissue injury to mature (e.g., wound healing

tensile strength and time for neurological injury to be considered chronic), smoldering inflammatory cascades are the underlying pathology, and the analogy of a single HBO “jump starting a failed engine with a dead battery” is grossly inadequate. In fact, the deciding factor in determining the number of HBO treatments may be the point in the injury process at which HBO is initiated, not financial considerations, a factor increasingly dominating medical decision-making in the United States today.

In our accumulating extensive experience, repetitive HBO appears to be trophic, stimulatory to brain repair, and may not be complete in some cases until 200–300 treatments (see Patient 1). Perhaps the best and most expedient method to assess the HBO potential and endpoint of treatment at any time after injury for any brain pathology is SPECT brain imaging on a high resolution camera (see Figs. 20.1–20.6). SPECT before and after any single HBO at any point in the treatment process may help identify the injured brain’s potential for any or further HBO. HBO can then be initiated or continued and combined with multiple other treatment modalities. This approach may help document cost-effectiveness of prolonged HBO by choosing endpoints. Currently, there are over 1200 hyperbaric centers in the United States but it is estimated that less than 5 % of these routinely treat the neurological conditions addressed in this chapter with the exception of decompression sickness and CO poisoning. In the last edition of this chapter, we wrote that “As hyperbaric medicine continues to experience a resurgence in use and expansion of applications and research, the proliferation of chambers and increasing ease of access will facilitate use of HBO in acute cerebral ischemia/anoxia and coma and will be driven by ever greater lay public and physician knowledge of the earlier data through widespread computer-assisted dissemination.” These words were prophetic as we are now seeing an Internet driven increase in HBO application to chronic neurological conditions. Efforts are currently underway to collect this massive amount of accruing data, publicize the results, leverage scientific proof of efficacy, and achieve reimbursement. The ultimate result will be a retrospective look and application of HBO to the highest impact targets, acute ischemic/hypoxic brain injury and resuscitation. The outcome will be a large scale dramatic improvement in mortality, morbidity, and quality of life. We predict that this will revolutionize the treatment of brain injury.

References

- Artru F, Chacornac R, Deleuze R. Hyperbaric oxygenation for severe head injuries. *Eur Neurol.* 1976a;14:310–8.
- Artru F, Philippon B, Gau F, Berger M, Deleuze R. Cerebral blood flow, cerebral metabolism and cerebrospinal fluid biochemistry in brain-injured patients after exposure to hyperbaric oxygen. *Eur Neurol.* 1976b;14:351–64.

- Astrup J, Siesjö BK, Symon L. Thresholds in cerebral ischemia—the ischemic penumbra. *Stroke*. 1981;12(6):723–5.
- Bai J, Lyden PD. Revisiting cerebral postischemic reperfusion injury: new insights in understanding reperfusion failure, hemorrhage, and edema. *Int J Stroke*. 2015;10(2):143–52.
- Baiborodov BD. Some peculiarities in application of hyperbaric oxygenation during the treatment of acute respiratory insufficiency in newborn infants. In: Abstracts VII Int Cong HBO Medicine, Moscow September 2–6, 1981. p. 368.
- Barrett K, Harch P, Masel B, Patterson J, Corson K, Mader J. Cognitive and cerebral blood flow improvements in chronic stable traumatic brain injury induced by 1.5 ATA hyperbaric oxygen (abstract). *Undersea and Hyperbaric Med*. 1998;25:9.
- Belokurov MI, Stepankov AA, Kirsanov BI. Hyperbaric oxygenation in the combined therapy of comatose states in children. *Pediatririia*. 1988;2:84–7.
- Benson K, Hartz AJ. A comparison of observational studies and randomized, controlled trials. *N Engl J Med*. 2000;342:1878–86.
- Bjelke B, Andersson K, Ogren SO, Bolme P. Asphyctic lesion: proliferation of tyrosine hydroxylase-immunoreactive nerve cell bodies in the rat substantia nigra and functional changes in dopamine neurotransmission. *Brain Res*. 1991;543:1–9.
- Borgens RB, Liu-Snyder P. Understanding secondary injury. *Q Rev Biol*. 2012;87(2):89–127.
- Bulkley BH, Hutchins GM. Myocardial consequences of coronary artery bypass graft surgery: The paradox of necrosis in areas of revascularization. *Circulation*. 1977;56(6):906–13.
- Buras JA, Reenstra WR. Endothelial-neutrophil interactions during ischemia and reperfusion injury: basic mechanisms of hyperbaric oxygen. *Neurol Res*. 2007;29(2):127–31.
- Buras JA, Stahl GL, Svodoba KKH, Reenstra WR. Hyperbaric oxygen downregulates ICAM-1 expression induced by hypoxia and hypoglycemia: the role of NOS. *Am J Physiol Cell Physiol*. 2000;278:C292–302.
- Calvert JW, Zhang JH. Hyperbaric oxygenation restores energy status following hypoxia-ischemia in a neonatal rat model. *FASEB Journal*. 2005;4,S-1(4):A481.
- Calvert JW, Yin W, Patel M, Bader A, Mychaskiw G, Parent AD, et al. Hyperbaric oxygenation prevented brain injury induced by hypoxia-ischemia in a neonatal rat model. *Brain Res*. 2002;951(1):1–8.
- Calvert JW, Cahill J, Yamaguchi-Okada M, Zhang JH. Oxygen treatment after experimental hypoxia-ischemia in neonatal rats alters the expression of HIF-1 α and its downstream target genes. *J Appl Physiol*. 2006;101(3):853–65.
- Chen J, Chen YH. Effects of hyperbaric oxygen on intrauterine hypoxic-ischemic brain damage in neonatal rats. (article in Chinese). *Zhongguo Dang Dai Er Ke Za Zhi*. 2009;11(5):380–3.
- Chen J, Chen YH. Effects of hyperbaric oxygen on synaptic ultrastructure and synaptophysin expression in hippocampus of neonatal rats with hypoxic-ischemic brain damage. *Chin J Pediatr*. 2010;48(3):199–204.
- Chen Y, Nadi NS, Chavko M, Auker CR, McCarron RM. Microarray analysis of gene expression in rat cortical neurons exposed to hyperbaric air and oxygen. *Neurochem Res*. 2009a;34:1047–56.
- Chen S, Xiao N, Zhang X. Effect of combined therapy with ephedrine and hyperbaric oxygen on neonatal hypoxic-ischemic brain injury. *Neurosci Lett*. 2009b;465:171–6.
- Churchill S, Weaver LK, Deru K, Russo AA, Handrahan D, Orrison WW, et al. A prospective trial of hyperbaric oxygen for chronic sequelae after brain injury (HYBOBI). *Undersea Hyperb Med*. 2013;40(2):165–93.
- Collet JP, Vanasse M, Marois P, Amar M, Goldberg J, Lambert J, et al. Hyperbaric oxygen for children with cerebral palsy: a randomized multicentre trial. *Lancet*. 2001;357:582–6.
- Concato J, Shah N, Horwitz RI. Randomized, controlled trials, observational studies, and the hierarchy of research designs. *N Engl J Med*. 2000;342:1887–92.
- Cormio M, Robertson CS, Narayan RK. Secondary insults to the injured brain. *J Clin Neurosci*. 1997;4(2):132–48.
- Dean BS, Verdile VP, Krenzelok EP. Coma reversal with cerebral dysfunction recovery after repetitive hyperbaric oxygen therapy for severe carbon monoxide poisoning. *Am J Emerg Med*. 1993;11(6):616–8.
- Dirnagl U. Cerebral ischemia: the microcirculation as trigger and target. In: Kogure K, Hossmann KA, Siesjö BK, editors. *Progress in brain research, Neurobiology of ischemic brain damage*, vol. 96. Amsterdam: Elsevier; 1993. p. 49–65.
- Dordain M, Humbert G, Robert M, Leroy J, Delaunay P. Coma hépatique par hépatite virale traitée avec succès par l'oxygène hyperbare. *Thérapeutique*. 1969;45(2):184–9.
- Dutka AJ, Kochanek PM, Hallenbeck JM. Influence of granulocytopenia on canine cerebral ischemia induced by air embolism. *Stroke*. 1989;20:390–5.
- Eltorai I, Montroy R. Hyperbaric oxygen therapy leading to recovery of a 6-week comatose patient afflicted by anoxic encephalopathy and posttraumatic edema. *J Hyperbaric Med*. 1991;6:189–98.
- Engler RL, Dahlgren MD, Morris DD, Peterson MA, Schmid-Schonbein GW. Role of leukocytes in response to acute myocardial ischemia and reflow in dogs. *Am J Physiol*. 1986a;251(2 Pt 2):H314–23.
- Engler RL, Dahlgren MD, Peterson MA, Dobbs A, Schmid-Schonbein GW. Accumulation of polymorphonuclear leukocytes during 3-h experimental myocardial ischemia. *Am J Physiol*. 1986b;251(1 Pt 2):H93–100.
- Glantz SA. Experiments when each subject receives more than one treatment. In: *Primer of bio-statistics*. New York: McGraw-Hill; 1992. p. 278–319.
- Godman CA, Chheda KP, Hightower LE, Perdriest G, Shin DG, Giardina C. Hyperbaric oxygen induces a cytoprotective and angiogenic response in human microvascular endothelial cells. *Cell Stress Chaperones*. 2009. doi:10.1007/s12192-009-0159-0.
- Golden ZL, Neubauer R, Golden CJ, Greene L, Marsh J, Mleko A. Improvement in cerebral metabolism in chronic brain injury after hyperbaric oxygen therapy. *Int J Neurosci*. 2002;112:119–31.
- Golden Z, Golden CJ, Neubauer RA. Improving neuropsychological function after chronic brain injury with hyperbaric oxygen. *Disabil Rehabil*. 2006;28(22):1379–86.
- Goulon M, Barois A, Rapin M, Nouailhat F, Grosbuis S, Labrousse J. Carbon monoxide poisoning and acute anoxia due to inhalation of coal gas and hydrocarbons: 302 cases, 273 treated by hyperbaric oxygen at 2 ata. *Ann Med Interne (Paris)*. 1969;120(5):335–49.
- Grigor'eva AV, Kazantzeva NV, Bul'chuk OV, Vikulova TA. Effects of different doses of hyperbaric oxygenation on morphology and transcription of cortical neurons of rats with experimental cerebral ischemia. *Biull Eksp Biol Med*. 1992;113(4):419–21.
- Gunther A, Manaenko A, Franke H, Wagner A, Schneider D, Berrouschot J, et al. Hyperbaric and normobaric reoxygenation of hypoxic rat brain slices—impact on purine nucleotides and cell viability. *Neurochem Int*. 2004;45(8):1125–32.
- Hai YU, Tian RL, Pan XW, Luan Z, Song LW. Effects of hyperbaric oxygen on brain bFGF and bFGF mRNA expression of neonatal grafts after hypoxia/ischemia injury. In: Joiner JT, editor. *Proceedings of the 2nd international symposium on hyperbaric oxygenation for cerebral palsy and the brain injured child*. Flagstaff: Best Publishing; 2002. p. 57–65.
- Hampson NB, Simonson SG, Kramer CC, Piantadosi CA. Central nervous system oxygen toxicity during hyperbaric treatment of patients with carbon monoxide poisoning. *Undersea Hyperb Med*. 1996;23(4):215–9.
- Harch PG. Late treatment of decompression illness and use of SPECT brain imaging. In: Moon RE, Sheffield PJ, editors. *Treatment of Decompression Illness*, 45th Workshop of the Undersea and Hyperbaric Medical Society. Kensington: UHMS; 1996. p. 203–42.

- Harch PG. Generic inhibitory drug effect of hyperbaric oxygen therapy (HBOT) on reperfusion injury (RI) (abstract). *Eur J Neurol*. 2000;7 Suppl 3:150.
- Harch PG. The dosage of hyperbaric oxygen in chronic brain injury. In: Joiner JT, editor. *The Proceedings of the 2nd International Symposium on Hyperbaric Oxygenation for Cerebral palsy and the Brain-Injured Child*. Flagstaff: Best Publishing; 2002. p. 31–56.
- Harch PG. Hyperbaric oxygen therapy in the treatment of chronic traumatic brain injury: from Louisiana boxers to U.S. veterans, an American Chronology. *Wound Care Hyperbaric Med*. 2010;1(4):26–34.
- Harch PG. Hyperbaric oxygen therapy for post-concussion syndrome: contradictory conclusions from a study mischaracterized as sham-controlled. *J Neurotrauma*. 2013;30:1995–9.
- Harch PG. Hyperbaric oxygen in chronic traumatic brain injury: oxygen, pressure, and gene therapy. *Med Gas Res*. 2015;5:9. doi:10.1186/s13618-015-0030-6.
- Harch PG, Neubauer RA. Hyperbaric oxygen therapy in global cerebral ischemia/anoxia and coma, Chapter 18. In: Jain KK, editor. *Textbook of Hyperbaric Medicine*. Gottingen: Hogrefe & Huber; 1999. p. 318–49.
- Harch PG, Neubauer RA. Hyperbaric oxygen therapy in global cerebral ischemia/anoxia and coma, Chapter 18. In: Jain KK, editor. *Textbook of hyperbaric medicine*, 4th revised and expanded. Gottingen: Hogrefe & Huber; 2004. p. 223–61.
- Harch PG, Gottlieb SF, Van Meter KW, Staab P. HMPAO SPECT brain imaging and low pressure HBOT in the diagnosis and treatment of chronic traumatic, ischemic, hypoxic and anoxic encephalopathies. *Undersea Hyperb Med*. 1994a;21(Suppl):30.
- Harch PG, Van Meter KW, Gottlieb SF, Staab P. HMPAO SPECT brain imaging of acute CO poisoning and delayed neuropsychological sequelae (DNSS). *Undersea Hyperb Med*. 1994b;21(Suppl):15.
- Harch PG, Kriedt CL, Weisend MP, Van Meter KW, Sutherland RJ. Low pressure hyperbaric oxygen therapy induces cerebrovascular changes and improves complex learning/memory in a rat open head bonk chronic brain contusion model. *Undersea & Hyperbaric Med*. 1996a;23(Suppl):48.
- Harch PG, Van Meter KW, Neubauer RA, Gottlieb SF. Appendix 2, Use of HMPAO SPECT for assessment of response to HBO in ischemic/hypoxic encephalopathies. In: Jain KK, editor. *Textbook of hyperbaric medicine*, 2nd Revised edn. Gottingen: Hogrefe & Huber; 1996b. p. 480–91.
- Harch PG, Kriedt C, Van Meter KW, Sutherland RJ. Hyperbaric oxygen therapy improves spatial learning and memory in a rat model of chronic traumatic brain injury. *Brain Res*. 2007;1174:120–9.
- Harch PG, Andrews SR, Fogarty EF, Amen D, Pezzullo JC, Lucarini J, et al. A phase I study of low-pressure hyperbaric oxygen therapy for blast-induced post-concussion syndrome and post-traumatic stress disorder. *J Neurotrauma*. 2012;29(1):168–85.
- Hardy P, Collet JP, Goldberg J, Ducruet T, Vanasse M, Lambert J, et al. Neuropsychological effects of hyperbaric oxygen therapy in cerebral palsy. *Dev Med Child Neurol*. 2002;44:436–46.
- Hayakawa T, Kanai N, Kuroda R, Yamada R, Mogami H. Response of cerebrospinal fluid pressure to hyperbaric oxygenation. *Neurol Neurosurg Psychiatry*. 1971;34:580–6.
- Helps SC, Gorman DF. Air embolism of the brain in rabbits pretreated with mechlorethamine. *Stroke*. 1991;22:351–4.
- Heyman A, Saltzman HA, Whalen RE. Use of HBO in treatment of cerebral ischemia and infarction. *Circulation*. 1966;33-34(Suppl II):II-20–7.
- Holbach KH, Caroli A. Oxygen tolerance and the oxygenation state of the injured human brain. In: Trapp WG et al., editors. *Procedures of the 5th international congress on hyperbaric medicine*. Burnaby: Simon Fraser University; 1974. p. 350–61.
- Holbach KH, Wassmann H, Kolberg T. Verbesserte reversibilität des traumatischen mittelhirnsyndromes bei anwendung der hyperbaren oxygenierung. *Acta Neurochir*. 1974;30:247–56.
- Holbach KH, Caroli A, Wassmann H. Cerebral energy metabolism in patients with brain lesions at normo- and hyperbaric oxygen pressures. *J Neurol*. 1977a;217:17–30.
- Holbach KH, Wassmann H, Caroli A. Continuous rCBF measurements during hyperbaric oxygenation. In: *Procedures of the 6th International congress on hyperbaric medicine*. Aberdeen: Aberdeen University Press; 1977b. p. 104–11.
- Holbach KH, Wassmann H, Caroli A. Correlation between electroencephalographical and rCBF changes during hyperbaric oxygenation. In: *Procedures of the 6th International congress on hyperbaric medicine*. Aberdeen: Aberdeen University Press; 1977c. p. 112–7.
- Hsu P, Li H-W, Lin Y-T. Acute hydrogen sulfide poisoning treated with hyperbaric oxygen. *J Hyperbaric Med*. 1987;2(4):215–21.
- Hutchison JH, Ker MM, Williams KG, Hopkinson WI. Hyperbaric oxygen in the resuscitation of the newborn. *Lancet*. 1963;2:1019–22.
- Hyperbaric Oxygen Therapy Indications, 13th Edition: The Hyperbaric Oxygen Therapy Committee Report. In: Weaver LK (ed.). *Undersea and Hyperbaric Medical Society*. North Palm Beach, FL: Best Publishing; 2014.
- Iadecola C, Anrather J. The immunology of stroke: from mechanisms to translation. *Nat Med*. 2011;17:796–808.
- Illingworth CFW, Smith G, Lawson DD, Ledingham IMcA, Sharp GR, Griffiths JC. Surgical and physiological observations in an experimental pressure chamber. *Br J Surg*. 1961;49:222–7.
- Ingvar DH, Lassen NA. Treatment of focal cerebral ischemia with hyperbaric oxygen. *Acta Neurol Scand*. 1965;41:92–5.
- Isakov IV, Pravdenkova SV, Ioffe IS. Effect of hyperbaric oxygenation on respiration in acute cerebral circulatory disorders. *Zh Vopr Neurokhir Im N N Burdenko*. 1982;1:34–9.
- Iwatsuki N, Takahashi M, Ono K, Tajima T. Hyperbaric oxygen combined with nicardipine administration accelerates neurologic recovery after cerebral ischemia in a canine model. *Crit Care Med*. 1994;22(5):858–63.
- Jiang JY, Bo YH, Yin YH, Pan YH, Liang YM, Luo QZ. Effect of arousal methods for 175 cases of prolonged coma after severe traumatic brain injury and its related factors. *Chin J Traumatol*. 2004;7(6):341–3.
- Kapp JP, Phillips M, Markov A, Smith RR. Hyperbaric oxygen after circulatory arrest: modification of postischemic encephalopathy. *Neurosurgery*. 1982;11(4):496–9.
- Kawamura S, Ohta H, Yasui N, Nemoto M, Hinuma Y, Suzuki E. Effects of hyperbaric oxygenation in patients with subarachnoid hemorrhage. *J Hyperbaric Medicine*. 1988;3(4):243–55.
- Khiabani KT, Bellister SA, Skaggs SS, Stephenson LL, Nataraj C, Wang WZ, et al. Reperfusion-induced neutrophil CD18 polarization: effect of hyperbaric oxygen. *J Surg Res*. 2008;150(1):11–6.
- Kiene H, von Schön-Angerer T. Single-case causality assessment as a basis for clinical judgment. *Alt Ther*. 1998;4(1):41–7.
- Kienle GS, Kiene H. Placebo effect and placebo concept: a critical methodological and conceptual analysis of reports on the magnitude of the placebo effect. *Alt Ther*. 1996;2(6):39–54.
- Koch A, Vermeulen-Cranch DME. The use of hyperbaric oxygen following cardiac arrest. *Br J Anaesth*. 1962;34:738–40.
- Kohshi K, Yokota A, Konda N, Munaka M, Yasukouchi H. Hyperbaric oxygen therapy adjunctive to mild hypertensive hypervolemia for symptomatic vasospasm. *Meurol Med Chir (Tokyo)*. 1993;33:92–9.
- Konda A, Baba S, Iwaki T, Harai H, Koga H, Kimura T, et al. Hyperbaric oxygenation prevents delayed neuronal death following transient ischaemia in the gerbil hippocampus. *Neuropathol App Neurobiol*. 1996;22(4):350–60.
- Krakovsky M, Rogatsky G, Zarchin N, Mayevsky A. Effect of hyperbaric oxygen therapy on survival after global cerebral ischemia in rats. *Surg Neurol*. 1998;49:412–6.
- Kunz A, Dirnagl U, Mergenthaler P. Acute pathophysiological processes after ischaemic and traumatic brain injury. *Best Pract Res Clin Anaesthesiol*. 2010;24:495–509.

- Larcan A, Laprevote-Heully MC, Lambert H, Alexandre P, Picard L, Chrismont N. Indications des thrombolytiques au cours des accidents vasculaires cérébraux thrombosants traits par ailleurs par O.H.B (2 ATA). *Therapie*. 1977;32:259–70.
- Lareng L, Brouchet A, Plat JJ. Experience of hyperbaric oxygen therapy in 2 cases of traumatic coma. *Anesth Reanim*. 1973;30:525–32.
- Li Y, Zhou C, Calvert JW, Colohan AR, Zhang JH. Multiple effects of hyperbaric oxygen on the expression of HIF-1 alpha and apoptotic genes in a global ischemia-hypotension rat model. *Exp Neurol*. 2005;191(1):198–210.
- Liu M-N, Zhuang S-Q, Zhang H-Y, Qin Z-Y, Li X-Y. Long-term effects of early hyperbaric oxygen therapy on neonatal rats with hypoxic-ischemic brain damage. *Zhongguo Dang Dai Er Ke Za Zhi*. 2006a;8(3):216–20.
- Liu XH, Zhao YL, Ma QM, Zhou XH, Wang Y. Optimal therapeutic window of hyperbaric oxygenation in neonatal rat with hypoxic-ischemic brain damage. *Zhonghua Er Ke Za Zhi*. 2006b;44(3):177–81.
- Liu Z, Xiong T, Meads C. Clinical effectiveness of treatment with hyperbaric oxygen for neonatal hypoxic-ischaemic encephalopathy: systematic review of Chinese literature. *BMJ*. 2006c;333(7564):374.
- Liu XH, Zhao YL, Ma QM, Zhou XH, Wang Y. Hyperbaric oxygen improves long-term learning-memory deficits and brain injury in neonatal rat with hypoxia-ischemia brain damage. *Sichuan Da Xue Xue Bao Yi Xue Ban*. 2007;38(1):73–7.
- Liu JT, Lee JK, Tyan YS, Liu CY, Chen YH, Lin TB. Neuromodulation on cervical spinal cord combined with hyperbaric oxygen in comatose patients—a preliminary report. *Surg Neurol*. 2009;72 Suppl 2:S28–34.
- Liu XH, Yan H, Xu M, Zhao YL, Li LM, Zhou XH, et al. Hyperbaric oxygenation reduces long-term brain injury and ameliorates behavioral function by suppression of apoptosis in a rat model of neonatal hypoxia-ischemia. *Neurochem Int*. 2013;62:922–30.
- Macdonald AG, Fraser PJ. The transduction of very small hydrostatic pressures. *Comp Biochem Physiol A Mol Integr Physiol*. 1999;122(1):13–36.
- Malek M, Duszczyk M, Zyszkowski M, Ziembowicz A, Salinska E. Hyperbaric oxygen and hyperbaric air treatment result in comparable neuronal death reduction and improved behavioral outcome after transient forebrain ischemia in the gerbil. *Exp Brain Res*. 2013;224:1–14.
- Martin JD, Thom SR. Vascular leukocyte sequestration in decompression sickness and prophylactic hyperbaric oxygen therapy in rats. *Aviat Space Environ Med*. 2002;73(6):565–9.
- Marx RE, Ehler WJ, Tayapongsak P, Pierce LW. Relationship of oxygen dose to angiogenesis induction in irradiated tissue. *Am J Surg*. 1990;160:519–24.
- Mathieu D, Wattel F, Gosselin B, Chopin C, Durocher A. Hyperbaric oxygen in the treatment of posthanging cerebral anoxia. *J Hyper Med*. 1987;2(2):63–7.
- Mathieu D, Bocquillon N, Charre S, Wattel F. Hyperbaric oxygenation in acute ischemic encephalopathy (near-hanging) (abstract). *Eur J Neurol*. 2000;7 Suppl 3:151.
- Mickel HS, Kempfski O, Feuerstein G, Parisi JE, Webster HD. Prominent white matter lesions develop in Mongolian gerbils treated with 100% normobaric oxygen after global brain ischemia. *Acta Neuropathol*. 1990;79(5):465–72.
- Mink RB, Dutka AJ. Hyperbaric oxygen after global cerebral ischemia in rabbits does not promote brain lipid peroxidation. *Crit Care Med*. 1995a;23(8):1398–404.
- Mink RB, Dutka AJ. Hyperbaric oxygen after global cerebral ischemia in rabbits reduces brain vascular permeability and blood flow. *Stroke*. 1995b;26:2307–12.
- Miura S, Ohyagi Y, Ohno M, Inoue I, Ochi H, Murai H, et al. A patient with delayed posthypoxic demyelination: a case report of hyperbaric oxygen treatment. *Clin Neurol Neurosurg*. 2002;104:311–4.
- Mogami H, Hayakawa T, Kanai N, Kuroda R, Yamada R, Ikeda T, et al. Clinical application of hyperbaric oxygenation in the treatment of acute cerebral damage. *J Neurosurg*. 1969;31:636–43.
- Montgomery D, Goldberg J, Amar M, Lacroix V, Lecomte J, Lambert J, et al. Effects of hyperbaric oxygen therapy on children with spastic diplegic cerebral palsy: a pilot project. *Undersea Hyperb Med*. 1999;26(4):235–42.
- Moody RA, Mead CO, Ruamsuke S, Mullan S. Therapeutic value of oxygen at normal and hyperbaric pressure in experimental head injury. *J Neurosurg*. 1970;32(1):51–4.
- Mrsic-Pelcic J, Pelcic G, Peternel S, Pilipovic K, Simonic A, Zupan G. Effects of the hyperbaric oxygen treatment on the Na⁺, K⁺-ATPase and superoxide dismutase activities in the optic nerves of global cerebral ischemia-exposed rats. *Prog Neuropsychopharmacol Biol Psychiatry*. 2004a;28(4):667–76.
- Mrsic-Pelcic J, Pelcic G, Vitezic D, Antoncic I, Filipovic T, Simonic A, et al. Hyperbaric oxygen treatment: the influence on the hippocampal superoxide dismutase and Na⁺, K⁺-ATPase activities in global cerebral ischemia-exposed rats. *Neurochem Int*. 2004b;44(8):585–94.
- Multiple authors (Chavdarov, Harch, Lobov, Neubauer, Zerbini). In: Joiner JT (ed.). *The Proceedings of the 2nd International Symposium on Hyperbaric Oxygenation for Cerebral palsy and the Brain-Injured Child*. Flagstaff, AZ: Best Publishing; 2002.
- Myers RE. A unitary theory of causation of anoxic and hypoxic brain pathology. *Adv in Neurol*. 1979;26:195–213.
- Nakamura T, Kuroda Y, Yamashita S, Kawakita K, Kawai N, Tamiya T, et al. Hyperbaric oxygen therapy for consciousness disturbance following head injury in subacute phase. *Acta Neurochir Suppl*. 2008;102:21–4.
- Neubauer RA. The effect of hyperbaric oxygen in prolonged coma. Possible identification of marginally functioning brain zones. *Medicina Subacquea ed Iperbarica*. 1985;5(3):75–9.
- Neubauer RA. *Interventional brain scanning in neurologic dysfunction*. Lauderdale-by-the-Sea: Ocean Hyperbaric Center; 1995. p. 22.
- Neubauer RA, James P. Cerebral oxygenation and the recoverable brain. *Neurol Res*. 1998;20 Suppl 1:S33–6.
- Neubauer RA, Kagan RL, Gottlieb SF, James P. Delayed metabolism, reperfusion or redistribution in ifofetamine brain imaging after exposure to hyperbaric oxygen, clinical correlations. In: *Proceedings of the XV Annual Meeting of the European Undersea Biomedical Society, EUBS, Eilat, Israel*. 1989. p. 237–43.
- Neubauer RA, Gottlieb SF, Kagan RL. Enhancing “idling” neurons. *Lancet*. 1990;335:542.
- Neubauer RA, Gottlieb SF, Miale A. Identification of hypometabolic areas in the brain using brain imaging and hyperbaric oxygen. *Clin Nucl Med*. 1992;17:477–81.
- Neubauer RA, Gottlieb SF, Pevsner NH. Long-term anoxic ischemic encephalopathy: predictability of recovery. In: Oriani G, Wattel F, editors. *Proceedings of the twelfth international congress on hyperbaric medicine*. Flagstaff, AZ: Best Publishing; 1998. p. 417–29.
- Neubauer V, Harch PG, Neubauer RA. Hyperbaric oxygen therapy in global cerebral ischemia/anoxia and coma, Chapter 21. In: Jain KK, editor. *Textbook of hyperbaric medicine*, 4th revised and expanded. Gottingen: Hogrefe & Huber; 2004. p. 287–96.
- Niu KC, Chang CK, Lin MT, Huang KF. A hyperbaric oxygen therapy approach to heat stroke with multiple organ dysfunction. *Chin J Physiol*. 2009;52(3):169–72.
- Oh S, Lee E, Lee J, Lim Y, Kim J, Woo S. Comparison of the effects of 40% oxygen and two atmospheric absolute air pressure conditions on stress-induced premature senescence of normal human diploid fibroblasts. *Cell Stress Chaperones*. 2008;13(4):447–58.
- Plum F, Pulsinelli WA. Cerebral metabolism and hypoxic-ischemic brain injury, Chapter 90. In: Asbury AK, McKhann GM, McDonald WI, editors. *Diseases of the nervous system, Clinical neurobiology*, vol. 1. Philadelphia: WB Saunders; 1986. p. 1086–100.

- Pundik S, Xu K, Sundararajan S. Reperfusion brain injury. *Neurology*. 2012;79 Suppl 1:S44–51.
- Raphael JC, Elkharrat D, Jars-Guinestre MC, Chastang C, Chasles V, Vercken JB, et al. Trial of normobaric and hyperbaric oxygen for acute carbon monoxide intoxication. *Lancet*. 1989;2(8660):414–9.
- Ren H, Wang W, Zhaoming CE. Glasgow Coma Scale, brain electric activity mapping and Glasgow Outcome Scale after hyperbaric oxygen treatment of severe brain injury (English Edition). *Chin J Traumatol*. 2001;4(4):239–41.
- Rice JE, Vannucci RC, Brierley JF. The influence of immaturity on hypoxic-ischemic brain damage in the rat. *Ann Neurol*. 1981;9:131–41.
- Rockswold GL, Ford SE, Anderson DC, Bergman TA, Sherman RE. Results of a prospective randomized trial for treatment of severely brain-injured patients with hyperbaric oxygen. *J Neurosurg*. 1992;76:929–34.
- Rockswold SB, Rockswold GL, Vargo JM, Erickson CA, Sutton RL, Bergman TA, et al. Effects of hyperbaric oxygenation therapy on cerebral metabolism and intracranial pressure in severely brain injured patients. *J Neurosurg*. 2001;94:403–11.
- Rockswold SB, Rockswold GL, Zaun DA, Zhang X, Cerra CE, Bergman TA, et al. A prospective, randomized clinical trial to compare the effect of hyperbaric to normobaric hyperoxia on cerebral metabolism, intracranial pressure, and oxygen toxicity in severe traumatic brain injury. *J Neurosurg*. 2010;112:1080–94.
- Rockswold SB, Rockswold GL, Zaun DA, Liu J. A prospective, randomized Phase II clinical trial to evaluate the effect of combined hyperbaric and normobaric hyperoxia on cerebral metabolism, intracranial pressure, oxygen toxicity, and clinical outcome in severe traumatic brain injury. *J Neurosurg*. 2013;118:1317–28.
- Rosenthal RE, Silbergleit R, Hof PR, Haywood Y, Fiskum G. Hyperbaric oxygen reduces neuronal death and improves neurological outcome after canine cardiac arrest. *Stroke*. 2003;34(5):1311–6. Epub 2003 Apr 3.
- Rossignol DA. Hyperbaric oxygen therapy might improve certain pathophysiological findings in autism. *Med Hypotheses*. 2007;68:1208–27.
- Rosor MN. Headache, stupor, and coma, Chapter 3.2. In: Walton J, editor. *Brain's diseases of the nervous system*. Oxford: Oxford University Press; 1993. p. 134–41.
- Ruiz E, Brunette DD, Robinson EP, Tomlinson MJ, Lange J, Wieland MJ, et al. Cerebral resuscitation after cardiac arrest using hetastarch hemodilution, hyperbaric oxygenation and magnesium ion. *Resuscitation*. 1986;14:213–23.
- Safar P. Cerebral resuscitation after cardiac arrest: a review. *Circulation*. 1986;74(Suppl IV):IV-138–53.
- Saltzman HA, Anderson B, Whalen RE, Heyman A, Sieker HO. Hyperbaric oxygen therapy of acute cerebral vascular insufficiency. In: Brown IW, Cox BG, editors. *Proceedings of the third international conference on hyperbaric medicine*, publication 1404. Washington, DC: National Academy of Sciences National Research Council; 1966. p. 440–6.
- Sanchez EC, Montes G, Oroz G, Garcia L. Management of intestinal ischaemia, necrotizing enterocolitis and anoxic encephalopathies of neonates with hyperbaric oxygen therapy. *Undersea Hyperb Med*. 1999;26(Suppl):22.
- Sanderson TH, Reynolds CA, Kumar R, Przyklenk K, Huttemann M. Molecular mechanisms of ischemia-reperfusion injury in brain: pivotal role of the mitochondrial membrane potential in reactive oxygen species generation. *Mol Neurobiol*. 2013;47:9–23.
- Satoh J, Murase H, Tukagoshi H. Hanging survivor showing alpha coma—a case report. *Rinsho Shinkeigaku*. 1989;29(5):612–6.
- Schmidt-Kastner R. Genomic approach to selective vulnerability of the hippocampus in brain ischemia-hypoxia. *Neuroscience*. 2015;309:259–79.
- Senechal C, Larivee S, Richard E, Marois P. Hyperbaric oxygenation therapy in the treatment of cerebral palsy: a review and comparison to currently accepted therapies. *J Am Phys Surg*. 2007;12(4):109–13.
- Shandling AH, Ellestad MH, Hart GB, Crump R, Marlow D, Van Natta B, et al. Hyperbaric oxygen and thrombolysis in myocardial infarction: the “hot MI” pilot study. *Am Heart J*. 1997;134(3):544–50.
- Sharp GR, Ledingham I. McA, Norman, JN. The application of oxygen at 2 atmospheres pressure in the treatment of acute anoxia. *Anaesthesia*. 1962;17(2):136–44.
- Sheffield PJ, Davis JC. Application of hyperbaric oxygen therapy in a case of prolonged cerebral hypoxia following rapid decompression. *Aviat Space Environ Med*. 1976;47(7):759–62.
- Shiokawa O, Fujishima M, Yanai T, Ibayashi S, Ueda K, Yagi H. Hyperbaric oxygen therapy in experimentally induced acute cerebral ischemia. *Undersea Biomed Res*. 1986;13(3):337–44.
- Shn-Rong Z. Hyperbaric oxygen therapy for coma (a report of 336 cases). In: *Proceedings of the international congress of hyperbaric medicine*. 1995. p. 279–85.
- Siddiqui A, Davidson JD, Mustoe TA. Ischemic tissue oxygen capacitance after hyperbaric oxygen therapy: a new physiologic concept. *Plast Reconstr Surg*. 1995;99:148–55.
- Siesjö BK, Katsura K, Zhao Q, Folbergrova J, Pahlmark K, Siesjö P, et al. Mechanisms of secondary brain damage in global and focal ischemia: a speculative synthesis. *J Neurotrauma*. 1995;12(5):943–56.
- Smilkstein MJ, Bronstein AC, Pickett HM, Rumack BH. Hyperbaric oxygen therapy for severe hydrogen sulfide poisoning. *J Emerg Med*. 1985;3:27–30.
- Snyder JW, Safir EF, Summerville GP, Middleberg RA. Occupational fatality and persistent neurological sequelae after mass exposure to hydrogen sulfide. *Am J Emerg Med*. 1995;13(2):199–203.
- Sukoff MH, Ragatz RE. Hyperbaric oxygenation for the treatment of acute cerebral edema. *Neurosurg*. 1982;10(1):29–38.
- Swift PC, Turner JH, Oxer HF, O’Shea JP, Lane GK, Woollard KV. Myocardial hibernation identified by hyperbaric oxygen treatment and echocardiography in postinfarction patients: comparison with exercise thallium scintigraphy. *Am Heart J*. 1992;124:1151–8.
- Takahashi M, Iwatsuki N, Ono K, Tajima T, Akama M, Koga Y. Hyperbaric oxygen therapy accelerates neurologic recovery after 15-minute complete global cerebral ischemia in dogs. *Crit Care Med*. 1992;20(11):1588–94.
- Teasdale G, Jennett B. Assessment of coma and impaired consciousness. A practical scale. *Lancet*. 1974;2:81–4.
- Thalman ED. Principles of U.S. navy recompression treatments for decompression sickness. In: *Diving accident management*, 41st Undersea and Hyperbaric Medical Society Workshop. Undersea and Hyperbaric Medical Society publication 78 (DIVACC). 12/1/90. p. 194–221
- Thom SR. Leukocytes in carbon monoxide-mediated brain oxidative injury. *Toxicol Appl Pharmacol*. 1993a;123(2):234–47.
- Thom SR. Functional inhibition of leukocyte B 2 integrins by hyperbaric oxygen in carbon monoxide-mediated brain injury in rats. *Toxicol Appl Pharmacol*. 1993b;123:248–56.
- Thom SR, Taber RL, Mendiguren II, Clark JM, Hardy KR, Fisher AB. Delayed neuropsychologic sequelae after carbon monoxide poisoning: prevention by treatment with hyperbaric oxygen. *Ann Emerg Med*. 1995;25(4):474–80.
- Thomas MP, Brown LA, Sponseller DR, Williamson SE, Diaz JA, Guyton DP. Myocardial infarct size reduction by the synergistic effect of hyperbaric oxygen and recombinant tissue plasminogen activator. *Am Heart J*. 1990;120(4):791–800.
- Thomson LF, Mardel SN, Jack A, Shields TG. Management of the moribund carbon monoxide victim. *Arch Emerg Med*. 1992;9(2):208–13.
- Van Meter K, Gottlieb SF, Whidden SJ. Hyperbaric oxygen as an adjunct in ACLS on guinea pigs after 15 minutes of cardiopulmonary arrest. *Undersea Biomed Res*. 1988;15(Suppl):55.
- Van Meter K, Weiss L, Harch PG. Hyperbaric oxygen in emergency medicine, Chapter 36. In: Jain KK, editor. *Textbook of hyperbaric medicine*. 3rd ed. Gottingen: Hogrefe & Huber; 1999a. p. 586–8.
- Van Meter KW, Sheps SS, Swanson HT, Wilson JP, Barratt DM, Kodu U, Roycraft EL, Moises JP, Nolan TA, Harch PG. A controlled prospective randomized pilot open chest cardiopulmonary resuscitation

- (CPR) comparing use of 100% oxygen in mechanical ventilation of swine at one, two, and four atmospheres ambient pressure after a 25 minute normothermic cardiopulmonary arrest at one atmosphere. *Ann Emerg Med.* 1999b;34(4 Pt. 2):S11.
- Van Meter K, Moises J, Marcheselli V, Murphy-Lavoie H, Barton C, Harch P, Bazan N. Attenuation of lipid peroxidation in porcine cerebral cortex after a prolonged 25-minute cardiopulmonary arrest by high-dose hyperbaric oxygen (HBO). *Undersea Hyperb Med.* 2001a;28(Suppl):83–4.
- Van Meter K, Xiao F, Moises J, Barratt D, Harch P, Murphy-Lavoie H, Bazan N. No difference in leukocyte adherence in the microvasculature in a porcine cerebral cortex by use of normobaric oxygen or low or high-dose hyperbaric oxygen in resuscitation after a prolonged 25 minute cardiopulmonary arrest. *Ann Emerg Med.* 2001b;38(4):S39.
- Van Meter K, Sheps S, Kriedt F, Moises J, Barratt D, Murphy-Lavoie H, et al. Hyperbaric oxygen improves rate of return of spontaneous circulation after prolonged normothermic porcine cardiopulmonary arrest. *Resuscitation.* 2008;78(2):200–14.
- Viard P, Blum D, Thys JP, Dubois J. Exsanguino-transfusions and hyperbaric oxygen in the treatment of hepatic coma in children. *Arch Fr Pediatr.* 1970;27(4):444–5.
- Voisin C, Wattel F, Pruvost P, et al. Interet de l'oxygénothérapie hyperbare dans le traitement de la strangulation par pendaison. A propos de 35 observations. *Maroc Med.* 1973;53:302–5.
- Waalkes P, Fitzpatrick DT, Stankus S, Topolski R. Adjunctive HBO treatment of children with cerebral anoxic injury. *Army Med Dept J PB.* 2002;8:13–21.
- Wada K, Ito M, Miyazawa T, Katoh H, Nawashiro H, Shima K, et al. Repeated hyperbaric oxygen induces ischemic tolerance in gerbil hippocampus. *Brain Res.* 1996;740:15–20.
- Wang XL, Yang YJ, Wang QH, Xie M, Yu XH, Liu CT, et al. Changes of Wnt-3 protein during the proliferation of endogenous neural stem cells in neonatal rats with hypoxic-ischemic brain damage after hyperbaric oxygen therapy. (article is Chinese). *Zhongguo Dang Dai Er Ke Za Zhi.* 2007a;9(3):241–6.
- Wang XL, Yang YJ, Wang QH, Yu XH, Xie M, Liu CT, et al. Effect of hyperbaric oxygen therapy administered at different time on white matter damage following hypoxic-ischemic brain damage in neonatal rats. *Zhongguo Dang Dai Er Ke Za Zhi.* 2007b;9(4):308–12.
- Wang XL, Zhao YS, Yang YJ, Xie M, Yu XH. Therapeutic window of hyperbaric oxygen therapy for hypoxic-ischemic brain damage in newborn rats. *Brain Res.* 2008;1222:87–94.
- Wang QH, Yang YJ, Chen CF, Yao Y, Li M. Protective effects of delayed multiple course hyperbaric oxygen treatment against hypoxic-ischemic brain damage in neonatal rats. *Chin J Contemp Pediatr.* 2009;11(6):464–70.
- Weinstein PR, Hameroff SR, Johnson PC, Anderson GG. Effect of hyperbaric oxygen therapy or dimethyl sulfoxide on cerebral ischemia in unanesthetized gerbils. *Neurosurg.* 1986;18(5):528–32.
- Wu L, Mustoe TA. Effect of ischemia on growth factor enhancement of incisional wound healing. *Surgery.* 1995;117:570–6.
- Yang YJ, Wang XL, Yu XH, Wang X, Xie M, Liu CT. Hyperbaric oxygen induces endogenous neural stem cells to proliferate and differentiate in hypoxic-ischemic brain damage in neonatal rats. *Undersea Hyperb Med.* 2008;35(2):113–29.
- Yangsheng T. Hyperbaric oxygen treatment of acute ischemic and anoxic cerebral injury. In: *Proceedings of the Eleventh International Congress on Hyperbaric Medicine*, President Wen-ren Li, M.D., Secretariat Frederick S. Cramer, M.D. Flagstaff: Best Publishing; 1995. p. 21822.
- Yatsuzuka H. Effects of hyperbaric oxygen therapy on ischemic brain injury in dogs. *Japanese J Anesthesiol.* 1991;40(2):208–23.
- Yaxi Q, Anquan Y, Guangkai G, Yansheng T. The study of the effect of hyperbaric oxygen on cerebral metabolic enzymes and cAMP during acute cerebral ischemia in rabbits. *Proceedings of the Eleventh International Congress on Hyperbaric Medicine*, President Wen-ren Li, M.D., Secretariat Frederick S. Cramer, M.D. Flagstaff: Best Publishing; 1995. p. 194–7.
- Yin X, Meng F, Wang Y, Wei W, Li A, Chai Y, et al. Effect of hyperbaric oxygen on neurological recovery of neonatal rats following hypoxic-ischemic brain damage and its underlying mechanism. *Int J Clin Exp Pathol.* 2013;6(1):66–75.
- Yiqun F, Jingchang L, Weiguang T, Haihong J, Peizhu X, Shilong L, Fenzhou S. Effect of hyperbaric oxygen on brain Na, K-ATPase and ultrastructure of cerebral ischemia gerbils. *Proceedings of the Eleventh International Congress on Hyperbaric Medicine*, President Wen-ren Li, M.D., Secretariat Frederick S. Cramer, M.D. Flagstaff, AZ: Best Publishing; 1995. p. 269–78.
- Yu XH, Yang YJ, Wang X, Wang QH, Xie M, Qi BX, et al. Effect of hyperbaric oxygenation on neural stem cells and myelin in neonatal rats with hypoxic-ischemic brain damage. *Zhongguo Dang Dai Er Ke Za Zhi.* 2006;8(1):33–7.
- Zamboni WA, Roth AC, Russell RC, Graham B, Suchy H, Kucan JO. Morphologic analysis of the microcirculation during reperfusion of ischemic skeletal muscle and the effect of hyperbaric oxygen. *Plast Reconstr Surg.* 1993;91(6):1110–23.
- Zhang ZW, Kang Y, Deng LJ, Luo CX, Zhou Y, Xue XS, et al. Therapy of central pontine myelinolysis following living donor liver transplantation: report of three cases. *World J Gastroenterol.* 2009;15(31):3960–3.
- Zhou C, Li Y, Nanda A, Zhang JH. HBO suppresses Nogo-A, Ng-R, or RhoA expression in the cerebral cortex after global ischemia. *Biochem Biophys Res Commun.* 2003;309(2):368–76.
- Zhou BY, Lu GJ, Huang YQ, Ye ZZ, Han YK. Efficacy of hyperbaric oxygen therapy under different pressures on neonatal hypoxic-ischemic encephalopathy. *Zhongguo Dang Dai Er Ke Za Zhi.* 2008;10(2):133–5.
- Zhu M, Lu M, Li QJ, Zhang Z, Wu ZZ, Li J, et al. Hyperbaric oxygen suppresses hypoxic-ischemic brain damage in newborn rats. *J Child Neurol.* 2015;30(1):75–82.