



Hyperbaric oxygen and carbon monoxide poisoning: a critical review

Kenneth P. Stoller

To cite this article: Kenneth P. Stoller (2007) Hyperbaric oxygen and carbon monoxide poisoning: a critical review, *Neurological Research*, 29:2, 146-155

To link to this article: <http://dx.doi.org/10.1179/016164107X181770>



Published online: 19 Jul 2013.



Submit your article to this journal [↗](#)



Article views: 26



View related articles [↗](#)



Citing articles: 28 View citing articles [↗](#)

Hyperbaric oxygen and carbon monoxide poisoning: a critical review

Kenneth P. Stoller

Hyperbaric Medical Center of New Mexico, 404 Brunn School Rd No. D/E, Santa Fe, NM 87505, USA

CO is likely to be the most common cause of poisoning worldwide and often results in persistent neuropathologic and cognitive sequelae. While the displacement of oxygen from hemoglobin by CO has overshadowed the myriad mechanisms by which CO causes injury, mere oxygen displacement has endured as the etiology of CO poisonings and perpetuated a cascade of misdiagnosis, misunderstandings and confusion regarding how and when to treat CO poisoning. Hyperbaric oxygen benefits the brain more than normobaric oxygen by, e.g. improving energy metabolism, preventing lipid peroxidation and decreasing neutrophil adherence. Randomized controlled trials have definitively shown hyperbaric oxygen as the only efficacious therapy for acute CO poisoning if delayed neurological sequelae are to be minimized. Normobaric oxygen should not be used between multiple hyperbaric oxygen treatments as this can contribute to toxicity. Hyperbaric oxygen seems to also have potential in the delayed treatment of CO poisoning using multiple treatments of low dose of oxygen; however, oxygen dosing issues are not yet fully understood for either acute or delayed treatment. It would behoove medical decision-makers to embrace this important tool and make it more accessible as well as helping to disseminate to the medical community what is now known from the available literature. [Neurol Res 2007; 29: 146–155]

Keywords: Carbon monoxide; cognitive; hyperbaric oxygen; neuropsychologic; poisoning

INTRODUCTION

Carbon monoxide (CO) is well known as a non-irritating, colorless, tasteless and odorless gas. It mixes readily with air and is found wherever organic material is burned under conditions of incomplete combustion, such as exhaust gas from internal combustion engines¹. Concentrations as high as 30% have been measured in automobile exhaust gas. CO is responsible for a larger number of severe chemical poisonings than any other single agent¹; in fact, it is the most common cause of poisoning in the USA and it appears to be the leading cause of injury and death due to poisoning worldwide. In the USA, it results in ~40,000 emergency department visits and 800 deaths per year^{2,3}.

Inadequate venting of furnaces, water heaters and space heaters can cause lethal levels of CO. Smoke has been reported to contain 0.1–10% CO, as well as several other potentially toxic gases⁴.

CO BIOCHEMISTRY

CO has always been thought to act primarily by depriving body cells of oxygen, by excluding oxygen from the tissues through the formation of a reversible complex between CO and the hemoglobin molecule (Hb); this complex is known as carboxyhemoglobin (COHb)⁵. COHb is unable to transport as much oxygen

as normal Hb; because the affinity of Hb for CO is well over 200 times that for oxygen, a small concentration of CO in inspired air can easily take the place of oxygen in circulating Hb⁵. Rapid breathing during heavy exercise can cause a 30% rise in the COHb level after 2 minutes exposure to 1% carbon monoxide⁴. A concentration of CO in air of 0.4% can be fatal after 1 hour because it causes a 30% rise in COHb level⁴.

CO has been observed to have direct toxic effects on mammalian lung tissue through inhibition of the cytochrome chain⁴. CO binds to cardiac and skeletal muscle's myoglobin, with cardiac muscle taking up about three times as much as skeletal muscle⁴. Carboxymyoglobin dissociation is slower than COHb dissociation; accounting for a rebound of COHb to significant levels several hours after normobaric oxygen therapy (NBOT) has lowered the levels of COHb⁴.

COHb is a completely reversible complex; however, cytosol heme concentration in the brain increases ten-fold after CO hypoxia adding to CO toxicity⁶. The understanding of the biochemical paradigm for CO has expanded greatly from the century old Warburg hypothesis of CO binding to heme proteins and competing for space with oxygen, but this understanding has not yet completely trickled down to practical clinical protocols for the heterogeneous presentations of CO poisonings (COP) (*Table 1*).

For a resting adult, 50% washout of COHb occurs after ~4 hours of breathing room air or 40 minutes breathing pure oxygen⁵. The reason why COHb levels correlate so poorly with clinical outcomes is that when

Correspondence and reprint requests to: K. P. Stoller, Hyperbaric Medical Center of New Mexico, 404 Brunn School Rd No. D/E, Santa Fe, NM 87505, USA. [info@hbotnm.com] Accepted for publication 4 April 2006.

blood samples are finally obtained, not only there is significant time elapsed, but often intervention with normobaric oxygen has taken place. This bears repeating, COHb levels do not reflect the severity of poisoning or the potential to develop the most frequent effect of CO poisoning, delayed neurological injuries or secondary sequelae. Furthermore, COHb levels do not account for factors that influence the severity of illness, length of exposure, peak COHb levels, nor the number of total exposures.

Only CO levels taken at the scene of an acute exposure have the potential to reflect the true nature of an acute poisoning. The technology to make such field assessments is just now becoming commercially available with the advent of handheld, non-invasive pulse CO-oximeters (Rad-57 by Masimo), and perhaps these units will eventually become part of the armamentarium of paramedic first-responders. They will need to be if there is insistence on using COHb levels as a criterion for how CO poisoning victims get treated. The first case of the use of this device for continuous monitoring at bedside has been reported⁸ (www.masimo.com; Masimo Corp., Irvine, CA, USA).

CO PATHOPHYSIOLOGY

Initial symptoms of CO poisoning include headache, dizziness, confusion, fatigue, nausea, vomiting, difficulty concentrating, loss of consciousness and coma^{2,9}. Pathophysiology of brain injury following CO poisoning include hypoxia¹⁰, excitotoxicity¹¹, binding to intracellular proteins and disrupting cellular metabolism¹², interference of intracellular enzyme function including P450¹³, lipid peroxidation (degradation of unsaturated fatty acids following peroxide generation) leading to oxidative injury¹⁴, deposition of peroxynitrate which damages blood vessel endothelium¹⁵, apoptosis or programmed cell death¹⁶, cerebral edema leading to secondary vascular effects¹⁷, lactic acidosis¹⁸, and oxidative stress from intracellular iron deposition¹⁹. Decreased glucose metabolism on positron emission tomography²⁰, hypoperfusion on single photon emission computed tomography (SPECT)^{21,22-24} and abnormal electroencephalography (EEG)^{25,26} parallel the focal and diffuse changes observed on structural imaging (Table 2).

CO binds to the same sites on heme proteins as nitric oxide (NO), a much-studied, naturally occurring vasodilator and a signaling molecule¹⁵. With CO poisoning,

Table 1: Biochemical effects of carbon monoxide

Blood	Increased level of carboxyhemoglobin Oxygen dissociation curve shifted to left Increased level of lactate
Cellular	Cytochrome c oxidase inhibition P-450 inhibition Cytosol heme levels increase in brain Glucose metabolism decreased Intracellular iron deposition increased Intercellular increase in nitric oxide

the amount of NO in the cell interior rises because CO usurps the spot of NO on the heme proteins. This imbalance makes NO available for biochemical reactions that would not normally occur within the cell, namely, ones that produce tissue-damaging oxidants and free radicals¹⁵. Thus cells release more NO with exposure to greater and greater concentrations of CO causing apoptosis¹⁵.

Blood vessels are a major site of damage in the brain due to CO exposure, especially the cells that line the inner wall of the vessels, the endothelium¹⁵. This damage occurs relatively early during exposure to CO; therefore, it could also be happening with lower concentrations of CO over longer periods of time, 'chronic' intoxications.

CO also decreases dopamine turnover in the caudate nucleus in a manner different from hypoxia, and the effect outlasts the time of exposure⁵. CO directly inhibits the action of cytochrome oxidase enzyme systems that are iron-containing proteins which get bound by CO⁵. The cytochrome oxidase system is predominant in areas of great metabolic activity; thus, organs with the highest metabolic rate, such as heart and central nervous system (CNS), are affected the most by COP⁵. The binding of CO to the cytochrome oxidase system inhibits cellular respiration by displacing oxygen but how long oxygen remains displaced is unknown.

Thom *et al.*²⁷ found that after COP, myelin basic protein (MBP) reacted with malonyaldehyde (a product of lipid peroxidation) to set off an immunologic cascade that was linked to delayed CO-mediated neuropathology in rats. While multiple mechanisms are involved in CO toxicity, both acute and delayed, underscoring the importance of more aggressive and appropriate treatment options than are used today; the correct diagnosis of CO poisoning is often times elusive, thus making the appropriate and timely treatment even more problematic.

The diagnosis of COP is readily apparent in only certain circumstances. The smoke-inhalation victim or the unconscious patient found in a garage with a running automobile is usually diagnosed at the scene by paramedics or bystanders. Some patients, notably those with long-term (chronic) exposure to low CO levels, will not be so obvious. These patients can present with very non-specific complaints. The symptoms are often of several days or even weeks' duration, perhaps

Table 2: Pathophysiology of CO in the central nervous system

Abnormal EEG
Cerebral edema
Hyperintensities of the periventricular white matter and centrum semiovale, thalamus and hippocampus
Decreases dopamine turnover in the caudate nucleus
Cerebral hypoperfusion
Reduced volume of the hippocampus
Diffuse atrophy
Peroxy-nitrate deposition
Immunologic cascade involving myelin basic protein (MBP) and malonyaldehyde

prejudicing the clinician against the toxic cause. Often, several family members are affected, prompting a diagnosis of 'viral syndrome' or 'gastro-enteritis'²⁸. Failure to diagnose COP may allow the patient to return to the exposure site, sometimes with dire consequences. Thus, COP should be included in the differential diagnosis of all patients presenting to any physician with headache, dyspnea, nausea or altered level of consciousness. Questions about home heating systems, possibility of car exhaust leaks and involvement of other family members, should be included in the history.

Cherry-red mucous membranes that all medical students are taught to look for, may be present only when COHb levels are between 50 and 60%²⁹. The absence of this cherry-red color, therefore, indicates nothing; this finding is rarely seen in a living patient, because COHb levels required to cause it are lethal. Cherry-red lips, skin and mucous membranes are more commonly seen post-mortem²⁹.

In a comprehensive follow-up study of CO exposure, Smith and Brandon³⁰ indicated that 33% of their patients showed personality deterioration and 43% had memory impairment. Other documented sequelae were mental retardation, frank psychosis and visual impairment. Ginsburg and Romano³¹ describe severe psychiatric disturbances in patients who were recovering from COP. In their study, 15–40% of the survivors developed severe neuropsychiatric symptoms after experiencing an 'apparent' recovery.

Delayed neuropsychologic sequelae have been reported in time period after initial exposure ranging from 1 to 40 days, with one report at day 240³². Reported symptoms include apraxia, apathy, gait disturbances, incontinence, movement disorders, seizures, hallucinations, cortical blindness, dementia, symptoms resembling multiple sclerosis, EEG changes and coma, with an incidence of 32–67% (Ref. 32).

An assessment³³ of brain imaging and neuropsychologic function with COP showed CNS neural-anatomical abnormalities affect: basal ganglia, frontal lobes, globus pallidus, mesial temporal lobe, bilateral symmetrical hyperintensities of the periventricular white matter and centrum semiovale, thalamus, hippocampus, cerebral hypoperfusion, and reduced regional cerebral blood flow in the frontal and temporal cortices. Study subjects were 21 patients with moderate to severe COP. The imaging was performed on the average ~2 years post-exposure.

Study results

Neuropsychologic impairment

(1) lowering of IQ by a mean of 10 points; (2) 76% had significant memory impairment; (3) 75% had impaired executive function; (4) 57% had slow mental processing speed; (5) 45% had impaired attention; (6) 95% had affective disturbance.

Neural imaging

(1) 67% had abnormal SPECT findings. Among these patients, the most common area of perfusion defect was

in the frontal (71%) and parietal (57%) regions. In total, 36% had defects in the temporal region and 21% had diffuse cerebral perfusion abnormalities; (2) 88% had abnormal clinical magnetic resonance image (MRI) findings. The most common finding was diffuse atrophy; (3) quantitative MRI (QMRI) found abnormalities (reduced volume) in the hippocampus.

The severe impact a CO poisoning has on the CNS should be a mandate to facilitate accessibility to the only known therapy proven to mitigate this injury.

CO AND HYPERBARIC OXYGEN

Haldane demonstrated that rats survived COP when treated with oxygen at 2 atmospheres absolute (ATA)³⁴. The effectiveness of hyperbaric oxygen was demonstrated again with another animal model³⁵, and the first human was treated successfully³⁶. Yet before 2002 and the publication of the carefully designed double-blind randomized control trial (RCT) by Weaver *et al.*³⁷, the recommended treatment for acute CO poisoning was 100% normobaric oxygen delivered by face mask. Hyperbaric oxygen therapy (HBOT) was recommended, although inconsistently, if there was loss of consciousness or COHb levels were greater than 40% (if a patient required transport to another facility). Regardless that hyperbaric oxygen benefits the brain more than normobaric oxygen by improving energy metabolism, preventing lipid peroxidation and decreasing neutrophil adherence, when to use HBOT has been the subject of debate since it was first used to treat COP⁹. The trial of Weaver *et al.* was not the first controlled trial, but it was the first one that was not plagued with or accused of having methodological flaws.

In the RCT of Weaver *et al.*, it was demonstrated that HBOT at 3 ATA was superior to NBOT in reducing the incidence of cognitive dysfunction at week 6 and month 12 by 46% after acute CO poisoning. Before the RCT of Weaver *et al.*, the majority of HBOT centers (74%) followed the dictum that all COP patients at high risk deserved a single treatment with hyperbaric oxygen, but multiple treatments were reserved for those who did not fully recover on completion of the first treatment³⁸. Weaver *et al.* provided HBOT three times within a 24 hour period, a protocol that was based on Gorman *et al.*³⁹, who found that the relapse rate for cognitive sequelae was lower in patients who were treated two or more times than it was in those treated only once, but Weaver *et al.* did not assess one treatment versus three treatments. It is of interest that the patients in the trial of Weaver *et al.* had nearly normal COHb levels before the first treatment, strongly suggesting that HBOT is therapeutically independent of elevated COHb concentrations. The RCT of Weaver *et al.* did not examine dosing (treatment pressure), so the optimal dose of hyperbaric oxygen for acute CO poisoning is still to be determined (the RCT of Weaver *et al.* took 7 years to complete looking at only one treatment pressure). Two other RCTs found a benefit from hyperbaric oxygen using pressures between 2.5 and 2.8 ATA^{40,41} (Table 3).

Weaver *et al.* found that for every six patients treated, one case of delayed neurological sequelae could be avoided. All treatments were carried out within 24 hours out of concern for compliance. The series of three treatments is now called the Weaver protocol and considered as a gold standard thanks to the large number of patients studied, the use of a sham-treatment control group with blinding of both patients and investigators, the selection of patients who were representative of the seriously poisoned patients that would be encountered in emergency departments, a very high rate of follow-up and explicit definitions of cognitive sequelae.

In a prospective randomized study, Jasper *et al.*⁴² observed the prevalence of depression and anxiety following CO poisoning. Depression and anxiety were present in 45% of patients at week 6, 44% at month 6 and 43% at month 12. CO patients poisoned accidentally were as probably as patients with suicide attempts to have depression and anxiety at months 6 and 12. HBOT given acutely did not reduce the rate of depression and anxiety but did reduce cognitive sequelae. While it is possible that the mechanism(s) by which hyperbaric oxygen reduces cognitive sequelae does not affect depression and anxiety, the patients in the study of Jasper *et al.* with no cognitive sequelae had lower depression and anxiety at week 6 and month 6, so there may be an indirect effect of HBOT.

What is the extent of these indirect effects and what is the therapeutic window to take advantage of them? Harch *et al.*⁴³ made the observation that patients with neurological conditions treated with standard HBOT for chronic wound problems experienced concomitant improvement in their neurological problems. Several years earlier, Neubauer and Gottlieb published several cases using SPECT brain imaging before and after HBOT, stroke, near drowning and natural gas poisoning with recovery of neurological function⁴⁴⁻⁴⁶. Subsequently, Dr Harch and Dr Van Meter performed the same sequence of SPECT scan/HBOT/SPECT scan on commercial divers with brain decompression sickness (DCS) and obtained results similar to those of Neubauer and Gottlieb with acute, subacute and chronic CO patients, acute, subacute and chronic brain decompression illness (DCI) patients and chronic, ischemic, hypoxic, traumatic, and/or hypoxic brain injury patients, respectively^{43,47,48}.

Commercial divers with DCS of the brain or spinal cord were flown in comatose and/or paralyzed from the oil and gas fields of the Gulf of Mexico. The recoveries

of these injured divers showed improvement in neurological levels far exceeding published reports and current expectations. The notable improvement was due to a protocol that treated beyond the medical standard of a few HBOT treatments. Some patients required as many as 100 treatments before reaching a clinical plateau. Minutes to hours after the onset of DCS, tissue damage continues to develop from the secondary damage to the blood vessel caused by the initial passage of bubbles, analogous to CO poisoning, bubbles set off a cascade of problems, yet do not linger but for an ephemeral finite period⁴⁹.

OXYGEN DOSING

The controversy about using HBOT for COP (as there continues to be one), is fueled by the misapplication of oxygen under pressure, in other words, the oxygen dose. The misinterpreted results of the rigorously controlled COP/HBOT study of Scheinkestel *et al.*⁵⁰ is the quintessential example of understanding the importance of oxygen dosing lest one draw inappropriate conclusions that continue to cloud evidence based medicine reviews to this day. Contrary to general perceptions and the conclusions drawn by its authors, the HBOT/COP study of Scheinkestel *et al.* was positive in a number of ways. First, it did not refute the beneficial effect of HBOT in non-severe COP that has been demonstrated in three previous RCT^{41,40,51}.

Scheinkestel *et al.* reported that: 'In this trial...HBO therapy did not benefit, and may have worsened the outcome... We cannot recommend its use in CO poisoning'. This statement is only partially true with respect to the severe COP subgroup (the second positive conclusion of the study). The severe COP group was defined by having any of the following: a mini-mental score 24, COHb level >30%, confusion, focal neurological deficits, loss of consciousness, electrocardiogram abnormalities, arrhythmias, pulmonary edema, metabolic acidosis, hypotension, convulsions, cardiac arrest or requiring ventilation.

However, the authors failed to analyse the non-severe COP subgroup. In a letter to the editor of Undersea and Hyperbaric Medicine, Kehat and Shupak⁵² analysed the non-severely poisoned subgroup of patients and showed that the HBOT group had a 50% incidence of persistent neurological sequelae (PNS) versus an 80% incidence in the NBOT group. This difference was statistically significant.

The data for the severely poisoned group showed a detrimental outcome of HBOT in COP for the first time

Table 3: RCTs that demonstrated benefit of HBOT for acute CO poisoning

Authors	Design	Oxygen dosing	Results
Weaver <i>et al.</i> (2002)	Double-blind RCT studying effect of HBOT on cognitive sequelae	3 ATA	Three HBOTs in 24 hours reduced cognitive sequelae at week 6 and month 12
Thorn <i>et al.</i> (1995)	Prospective, randomized studying effect of HBOT on delayed neurological sequelae	2.8 ATA for 30 minutes + 2 ATA for 90 minutes	HBOT decreased incidence of delayed neurological sequelae
Ducasse <i>et al.</i> (1995)	Randomized studying immediate post-treatment outcomes and at week 3	2.5 ATA for 2 hours	HBO reduces the time of initial recovery and the number of delayed functional abnormalities

in the history of HBOT, and has been the major source of misunderstanding. It has also inadvertently misled the emergency and hyperbaric medicine community and has been generalized and misapplied to all COP patients. In fact, the data actually positively contribute to the medical literature in HBOT/COP by providing an extreme data point on the oxygen dose response/toxicity curve that illustrates an HBOT protocol which should be avoided in severe COP. Three 2.8 ATA HBOT treatments in the first 48 hours interspersed with 3 days of high-flow 100% NBOT and a repeat of this HBOT/NBOT dose if the patient is still symptomatic at day 3 is a protocol that has never been routinely applied in the history of HBOT/COP. Other hyperbaric physicians have also noted this fact⁵³. Therefore, to pick this protocol to answer the question of efficacy of HBOT in COP was inappropriate. In addition, no evidence exists to argue for 3 days of continuous NBOT.

Last, the rationale for three high pressure (dose) HBOTs was based on a misquotation, erroneous summarization or flawed extrapolation of Gorman and Runciman's⁵⁴ recommendation for '...administration of hyperbaric oxygen (at either 2 or 3 ATA for one to two hours) on admission to hospital, and repeated either daily or as made necessary by the patient's condition...' The study of Scheinkestel *et al.* misquoted that passage as '...HBO at 2–3 ATA for 1–2 hours on three or more occasions...' Gorman and Runciman cited seven studies as the basis for their recommendation^{55–61}, none of which support the study protocol of Scheinkestel *et al.* Scheinkestel *et al.* changed the highly individualized dose recommended by Gorman and Runciman⁵⁴ to a higher fixed dose by adding continuous NBOT to three mandatory 2.8 ATA HBOTs in 48 hours. Holbach⁶² has shown that a single 10–15 minute 2.0 ATA dose of HBOT 'a few days' after acute severe brain injury is toxic. In other words, there is a finite window where high dose oxygen can be therapeutic after an acute injury, followed by another window where a high dose is not therapeutic. In addition, a review of 900 CO cases by Hampson revealed that the extreme manifestation of oxygen toxicity, seizures, increases ten-fold when the HBO pressure is increased from 2.4 to 2.8 ATA⁶³. Spread over a 48–72 hour time frame, three 2.8 ATA HBOTs plus 3 days of continuous high-flow NBOT is a far greater dose which should generate at least some degree of sub-seizure toxicity. The experimental design then amplifies these probably oxygen toxicity effects in the HBOT arm, by directing those patients with residual signs and symptoms (after 3 days, i.e. possible oxygen toxicity), to the greater toxicity of an additional three high dose HBOTs and 3 days of high flow NBOT. The statistically significant increase in the number of HBOT patients abnormal after 3 HBOTs and 3 days of NBOT who then required the full 6 day treatment course, and the overall worse outcome of the severely poisoned HBOT group, strongly support this hypothesis.

Of equal or greater contribution to oxygen toxicity in the severely poisoned group is the continuous delivery of NBOT. Intermittent administration of HBOT has been the foundation of hyperbaric medicine from its

inception and accepted as standard of care for resolution of both acute and chronic ischemic CNS and non-CNS wounds⁶⁴. One of the best examples in CNS wounding is acute neurological DCI where all modern treatment protocols involve intermittent HBOT treatment tables with intervening air breaks within and between the HBOT tables. These air breaks are required to deter oxygen toxicity effects⁶⁵. On the other hand, continuous NBOT is only used in acute DCI as a temporizing therapy until HBOT is available and thereafter only if systemic hypoxia is present. Similarly, acute COP treatment protocols feature NBOT until HBOT is available then intermittent dosing of HBOT⁶⁶. The same concept of intermittent HBOT without intervening NBOT has become the essence of tailing hyperbaric treatments that are now standard of care in cerebral DCI⁶⁷. Continuous NBOT on top of intermittent high dose HBOT violates these historical precepts and the data on oxygen toxicity. The absence of air breaks increases the probability that acute and chronic wound resolution will cease or even worsen⁶⁸, as seen in the severe COP group of this study. In addition, uninterrupted NBOT with intermittent HBOT seems to, by induced oxygen toxicity, have masked of any benefit that intermittent HBOT might have had in severe COP, benefit clearly present with the study of Weaver *et al.* that also treated three times and at an ever higher pressure; however, all are within the first 24 hours.

The perplexing aspect of the study of Scheinkestel *et al.* is that the high dose of HBOT/NBOT was differentially toxic to the severely poisoned patients. This is somewhat consistent with the above findings of Holbach⁶² and may simply reflect differential toxicity based on the volume of injured brain. On the other hand, the findings in severe COP may be irrelevant to non-severe COP⁵⁴ due to differences in pathology. More probably, the toxicity in the severe group is due to a combination of these factors and a delay to treatment which directly relates to different evolving pathologic targets in CO poisoning⁶⁹. Specifically, the study claimed no difference in PNS between NBOT and HBOT treatment unless one analysed the severely poisoned group. There was no difference in PNS between NBOT and HBOT in the severely poisoned group if patients were treated within 4 hours of poisoning. Therefore, the preponderance of toxicity appears to be in the severe group treated beyond 4 hours, which is roughly the time period in which four of five other HBOT/COP studies have argued decreasing efficacy with delay to HBOT^{39,40,70–72}. The study of Scheinkestel *et al.* indicates the second demonstration of HBOT toxicity in the history of HBOT/COP⁶³. It appears that the combination of delay and extreme oxygen dose describes the far right of the continuum of decreasing efficacy of HBOT with delay to treatment similar to the peak and downslope of a Starling curve. A similar argument was made for HBOT in acute global ischemia, anoxia and coma using a 3 hour cutoff⁷³. In this review, a single high pressure dose of HBOT (greater than or equal to 2.0 ATA) within the first 3 hours after cerebral insult was curative in the great majority of patients,

implying a differential sensitivity of the pathologic targets to an early single dose of HBOT. This is also true in DCS and air embolism where single dose cure occurs in over 90% of patients treated within 1 hour of their accident⁷⁴. Delay to treatment worsens outcome and demands additional treatment due to the change in pathologic targets⁷⁵.

The high dose of oxygen in the study of Scheinkestel *et al.* coupled with a delay to treatment spread out over 48 hours plus continuous normobaric oxygen between treatments appears toxic to patients with severe COP. The effective dose is still unknown, but note again that Weaver *et al.* showed that three high dose treatments within the first 24 hours (but without additional normobaric oxygen) is therapeutic, and Weaver was treating severely poisoned patients. The important conclusion then is that the study of Scheinkestel *et al.* is positive in many ways and reinforces the existing literature: it reaffirms the necessity of minimizing delay to definitive treatment, does not refute the standard of care of HBOT in acute non-severe COP and suggests that 72 hours of continuous NBOT has therapeutic benefit for severe COP.

What the studies of Scheinkestel *et al.* and Weaver *et al.* show is that for first treatment in COP, high dose HBOT, at 2.8–3.0 ATA, may be the clear choice in the first four hours, even in the first 24 hours. The question of whether or not to treat two more times within the first 24 hours was not answered by Weaver *et al.* as they did not have a single treatment group. It would have been interesting to have had that group as the question of whether such a group would have fared even better than those that received three treatments in 24 hours still remains unanswered. What we do know is that multiple high dose treatments carried out outside the first 24 hours with continuous NBOT are not therapeutic to severely poisoned patients. The bottom-line is that the Scheinkestel protocol provides an extreme therapeutic point on the dose-response curve of oxygen and should never be used.

HBOT could be delivered according to patient response as Gorman and Runciman⁵⁴ recommended above, or as per Weaver *et al.* In some cases, this might require prolonged tailing treatments at half the pressure used by Weaver *et al.*^{47,76–79}.

Unfortunately, the results of Scheinkestel *et al.* continue to be interpreted as compelling pseudo-proof of the ineffectiveness of HBOT in acute COP. The specific negative effect of this protocol in severe COP was generalized by the authors and misapplied to all COP patients. This misinterpretation and misapplication has had profound far-reaching consequences internationally in emergency medicine as a growing number of physicians have altered their practice to no longer refer acute COP patients for HBOT or even see a reason to have hyperbaric chambers available in their emergency departments.

In a presentation at a HBOT conference in Columbia, SC, USA, one of the co-authors⁸⁰ of the study of Scheinkestel *et al.* stated that acute COP is no longer treated with HBOT in his province of Victoria, Australia

(population: 4.5 million). That author's facility not only has stopped treating COP with HBOT, but also inexplicably does not use the reportedly more effective normobaric protocol in the study of Scheinkestel *et al.* to treat severe COP patients.

The study of Scheinkestel *et al.* had unequivocal positive findings and has the potential to someday contribute significantly to science and the standard of care in acute COP when and if the data are understood correctly. Specifically, the study did not refute the standard of care of a beneficial effect of HBOT in non-severe acute COP, demonstrated a detrimental and possible toxic dose of HBOT that should be avoided in severe COP, argued strongly for minimizing delay to definitive treatment and suggested a beneficial NBOT dose in severe COP. Nevertheless, it may take some time before evidence-based medicine reviewers understand the positive implications of the study of Scheinkestel *et al.*

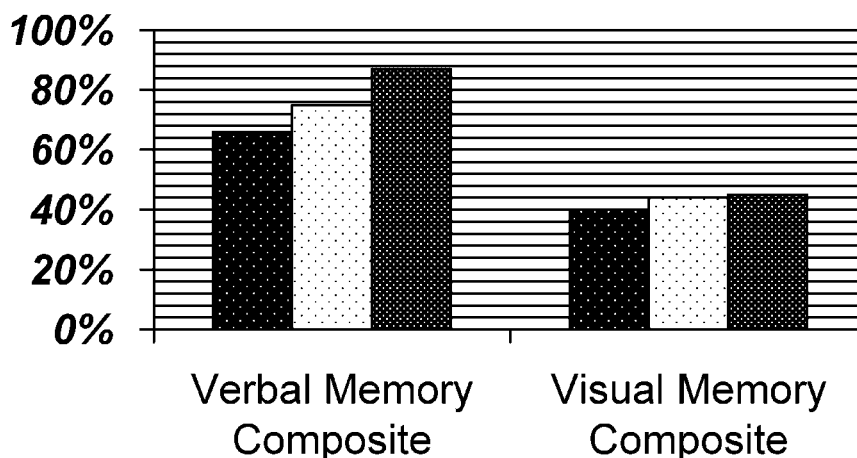
LOW-PRESSURE (DOSE) HYPERBARIC OXYGEN: A CASE REPORT

The author was able to demonstrate that a 15 year matured brain injury in a teenager with fetal alcohol syndrome responded with sustained neurocognitive improvements to low-pressure hyperbaric oxygen⁸¹. Fetal alcohol syndrome is considered as the ultimate example of a non-treatable, static and incurable brain injury. The above is relevant because no efficacious treatment is currently being offered to COP victims that develop late sequelae, whether or not they received acute intervention.

The author successfully adapted⁸² a computerized neuropsychologic test battery to evaluate COP victims before and after HBOT that had been originally developed to evaluate sports concussions at the University of Pittsburgh Medical Center (UPMC) for Sports Medicine Sports Concussion Program^{83,84}. The software evaluates and documents multiple aspects of neurocognitive functioning including memory, brain processing speed, reaction time and post-concussive symptoms. Furthermore, unlike standard neurocognitive testing modalities, the immediate post-concussion assessment and cognitive testing (ImPACT) has shown itself to be a reliable evaluation tool with virtually no practical effect on score stability⁸⁵ (www.impacttest.com; ImPACT Applications, Hilton Head Island, SC, USA).

There is little doubt that an accessible and easy-to-use tool to assess neurocognitive function will be important to any emergency department that desires to appropriately evaluate COP victims. In the following illustrative case, documented neurocognitive changes are documented even though HBOT was initiated 7 months after an acute exposure.

In 2001, a previously healthy 48 years old man, with a post-graduate degree, was exposed to CO levels greater than 225 ppm while at home enjoying a Christmas Eve fire with his wife and their poorly designed chimney. While he remained apparently asymptomatic, his wife lost consciousness and received



	Verbal Memory Composite	Visual Memory Composite
■ Pre-HBOT 07/29/02	66%	40%
□ after 40 HBOT 08/27/02	75%	44%
■ after 80 HBOT 01/31/02	87%	45%

Figure 1: ImPACT neurocognitive test scores in the verbal and visual memory modules. Normalized high school and college mean scores for verbal memory are 87%, but visual memory is 77%. The visual memory score in this case is severely impaired despite modest improvement

a single 2 hour treatment with hyperbaric oxygen with apparent full recovery, but her husband was not evaluated nor worked up as a patient presumably because he had no symptoms. One week later, he began to develop symptoms consistent with Parkinson’s disease.

Seven months after his COP, he exhibited symptoms of severe Parkinsonism: compromised gait, no facial affect, no blink reflex and severely impaired scores on the neurocognitive evaluation. He was treated with HBOT (40 treatments at minute 60/1.5 ATA 100% O₂; once a day). His exit testing showed improvement in all components of the ImPACT test. He was retreated again 1 year after his poisoning and his scores improved further with verbal memory now on par with high school and college mean scores, an improvement from 66 to 87% (high school mean=87.49%; college mean=86.98%). All other scores, while improved, remained well below high school mean and his visual memory remained severely impaired (*Figure 1*). His gait had returned to normal after his first 40 treatments and he displayed facial expression including a restored blink reflex during the course of his HBOT.

The axiom that old injuries are somehow static or irreversible is untenable. It is now recognized in neurology that deterioration due to brain damage at birth may take place over 28 years⁸⁶. This mirrors the adult situation⁸⁷. Further, over the last decade, stem or progenitor cells have been found in the adult brain and they can result in neural regeneration⁸⁸. This recovery process is oxygen-dependent regardless of how old the injury is. Therefore, it is in the best interest of COP patients, whether they have been mistreated or never treated, to further explore the viability of using extended low-pressure HBOT as a treatment for their injuries.

Using 1.3–1.5 ATA may one day be found to be a beneficial treatment pressure for severe COP as well.

The ImPACT computer assessment used in this case appears to be a very useful tool for following changes in neurocognitive function after brain injury, and has application beyond the evaluation of sports-related concussions. There are mounting case reports that HBOT may still be useful in the treatment of neurological injury from COP even if applied in the non-acute period^{89–91} as it was with the above patient. DCS cases sometimes needed to be treated 100 times before clinical plateau was reached; thus, the optimal number of treatments for late neurological sequelae has yet to be determined. The lack of appreciation in the pathologic differences in acute versus chronic brain injury has produced a legacy of equivocal results. Dosage matters with HBOT and treating a chronic brain injury at a pressure used for diabetic foot ulcers (2.4 ATA), acute DCS or COP (2.8 ATA), is not going to, in all likelihood, produce the desired healing, but these are questions which have not been answered in a RCT.

Being acute or chronic, oxygen dosing (hyperbaric pressure), first and foremost, is what provides the signaling at a cellular level, including the subcellular level of mitochondria, which reverses the injuries incurred from COP. For example, in a prospective study of 163 patients with acute CO poisoning, different doses of supplemental normobaric oxygen, from room air, nasal cannulae, non-rebreathing reservoir face mask and endotracheal tube, were not associated with different 6 week post-treatment cognitive sequelae⁹². Clearly, normobaric oxygen is not the answer to non-severe CO poisoning.

As COHb levels cannot be used as a guide for treatment, at least until field readings become standard,

and the severity of symptoms cannot be used as a reliable selection criterion for treatment, then do we treat everyone with a history of acute exposure? The answer is that every emergency department needs a reliable screening tool. The ImpACT test certainly should be considered as a prototype as such a screening modality. There would be no baseline evaluation before CO exposure, but that is where a good history would come to the fore, for example, one should not be performing below normalized values for one's educational level. Perhaps, the triage of COP patients will eventually rely on a biomarker of CO-induced brain injury, such as the S-100B protein⁹³.

Last, it should be noted that a prospective uncontrolled study on 44 pregnant women using HBOT for acute COP was well tolerated without any untoward effects on either fetus or mother⁹⁴.

DISCUSSION

HBOT is the only available therapy that has shown itself to be efficacious for the treatment of acute CO poisoning and should be considered in the treatment of all patients with COP, but NBOT should not be used between multiple high pressure (dose) treatments, and high pressure treatments should probably not be administered beyond the first 24 hours even when the first treatment takes place within the first 4 hours after poisoning. What remains unknown is whether a single high pressure treatment is adequate or superior to high pressure treatments given in the first 24 hours. Low-pressure HBOT, on the other hand, appears to hold great promise for the delayed treatment of acute exposures and chronic exposures as well. COHb levels must be abandoned as a criterion for treating with HBOT unless the level is taken acutely in the field. It would behoove medical decision-makers to embrace this important tool and make it more accessible as well as helping to disseminate to the medical community what is now known from the literature. Lest we forget, this is the most common poisoning in the world and the occult economic burden that society shoulders when even just one individual develops mild cognitive sequelae can be substantial regardless of the cause. The question remains how to mitigate misinterpreted and inappropriately applied literature reviews and assessments (based on misunderstood data) from causing HBOT to be withheld from COP patients. How aggressive will the medical community be in promoting this proven, humanitarian tool so that it can be made available in a timely manner without the encouragement or clarification of a corporate sponsor? Last, who will advocate for the throngs of brain injured victims of COP who continue to fall through the chasms of modern medicine?

ACKNOWLEDGEMENTS

The author would like to recognize the inspiration of the late Patrick McKinney, MD, Medical Director of the NM Poison Control Center, and thank Paul Harch, MD, Clinical Assistant Professor, Emergency Department, Louisiana State University (LSU), and Director, Hyperbaric

Medicine Fellowship, LSU, School of Medicine, for his sage advice, analysis and expertise.

REFERENCES

- 1 Raub JA, Mathieu-Nolf M, Hampson NB, *et al*. Carbon monoxide poisoning – a public health perspective. *Toxicology* 2000; **145**: 1–14
- 2 Weaver LK. Carbon monoxide poisoning. *Crit Care Clin* 1999; **15**: 297–317
- 3 Hampson NB, ed. *Hyperbaric Oxygen Therapy: 1999 Committee Report*, Kensington, MD: Undersea Hyperbaric Medical Society, 1999: pp. 9–12
- 4 Dolan MC. Carbon monoxide poisoning. *Can Med Assoc J* 1985; **133**: 392–399
- 5 Gosselin RE, Smith RP, Hodge HC, eds. *Clinical Toxicology of Commercial Products*, 4th edn, Baltimore, MD: Williams and Wilkins, 1984
- 6 Cronje FJ, Carraway MS, Freiburger JJ, *et al*. Carbon monoxide actuates O₂-limited heme degradation in the rat brain. *Free Radic Biol Med* 2004; **37**: 1802–1812
- 7 Seger D, Welch L. Carbon monoxide controversies: Neuropsychologic testing, mechanisms of toxicity, and hyperbaric oxygen. *Ann Emerg Med* 1994; **23**: 242–248
- 8 Plante T, Harris D, Monti J, *et al*. Carbon monoxide poisoning detected and monitored continuously and noninvasively: A case report. *Respir Care* 2005; **50**: 1480
- 9 Piantadosi CA. Carbon monoxide poisoning. *N Engl J Med* 2002; **347**: 1054–1055
- 10 Caine D, Watson JD. Neuropsychological and neuropathological sequelae of cerebral anoxia: A critical review. *J Int Neuropsychol Soc* 2000; **6**: 86–99
- 11 Jarrard LE, Meldrum BS. Selective excitotoxic pathology in the rat hippocampus. *Neuropathol Appl Neurobiol* 1993; **19**: 381–389
- 12 Piantadosi CA. Carbon monoxide, oxygen transport, and oxygen metabolism. *J Hyperb Med* 1987; **2**: 27–44
- 13 Coburn RF. Mechanisms of carbon monoxide toxicity. *Prev Med* 1979; **8**: 310–322
- 14 Thom SR. Antagonism of carbon monoxide mediated brain lipid peroxidation by hyperbaric oxygen. *Toxicol Appl Pharmacol* 1990; **105**: 340–344
- 15 Thom SR, Garner S, Fisher D, *et al*. Vascular nitrosative stress from carbon monoxide (CO) exposure. *Undersea Hyperb Med* 1998; **25**: 47
- 16 Piantadosi CA, Zhang J, Levin ED, *et al*. Apoptosis and delayed neuronal damage after carbon monoxide poisoning in the rat. *Exp Neurol* 1997; **147**: 103–114
- 17 Imaizumi H, Tsuruoka K, Ujike Y, *et al*. [Hypoxic brain damage after prolonged arrest during anesthesia – changes in CT and serum NSE concentration]. *Masui* 1994; **43**: 1256–1260
- 18 Sutariya B, Penney D, Dunbar J, *et al*. Comparing Evans' index and computerized axial tomography in assessing relationship of ventricular size to brain size. *Neurology* 1992; **26**: 231–233
- 19 Piantadosi CA. Carbon monoxide poisoning. *Undersea Hyperb Med* 2004; **31**: 167–177
- 20 De Reuck J, Decoo D, Lemahieu I, *et al*. A positron emission tomography study of patients with acute carbon monoxide poisoning treated by hyperbaric oxygen. *J Neurol* 1993; **240**: 430–434
- 21 Gale SD, Hopkins RO, Weaver LK, *et al*. MRI, quantitative MRI, SPECT and neuropsychological findings following carbon monoxide poisoning. *Brain Inj* 1999; **13**: 229–243
- 22 Choi IS, Kim SK, Lee SS, *et al*. Evaluation of outcome of delayed neurologic sequelae after carbon monoxide poisoning by technetium-99m hexamethylpropylene amine oxime brain single photon emission computed tomography. *Eur Neurol* 1995; **35**: 137–142
- 23 Choi IS, Lee MS, Lee YJ, *et al*. Technetium-99m HM-PAO SPECT in patients with delayed neurologic sequelae after carbon monoxide poisoning. *J Korean Med Sci* 1992; **7**: 11–18
- 24 Hurley RA, Hopkins RO, Bigler ED, *et al*. Applications of functional imaging to carbon monoxide poisoning. *J Neuropsychiatry Clin Neurosci* 2001; **13**: 157–160
- 25 Garland H, Pearce J. Neurological complications of carbon monoxide poisoning. *Q J Med* 1967; **36**: 445–455

- 26 Min SK. A brain syndrome associated with delayed neuropsychiatric sequelae following acute carbon monoxide intoxication. *Acta Psychiatr Scand* 1986; **73**: 80–86
- 27 Thom SR, Bhopale VM, Fischer, D, et al. Delayed neuropathology after carbon monoxide poisoning is immune-mediated. *Proc Natl Acad Sci USA* 2004; **101**: 13660–13665
- 28 Qureshi ST, Mahajan P. Carbon monoxide poisoning: Clues to unmasking the great masquerader. *Consult Pediatr* 2005; **4**: 477–482
- 29 Myers RAM. Carbon monoxide poisoning. In: Nelson RN, Rund DA, Keller MD, eds. *Environmental Emergencies*, Philadelphia, PA: WB Saunders Company, 1985
- 30 Smith SJ, Brandon S. Morbidity from acute carbon monoxide poisoning at three year follow-up. *Br Med J* 1973; **1**: 318–221
- 31 Ginsburg R, Romano J. Carbon monoxide encephalopathy: Need for appropriate treatment. *Am J Psychiatry* 1976; **133**: 317–320
- 32 Tibbles PM, Perrotta PL. Treatment of carbon monoxide poisoning: A critical review of human outcome studies comparing normobaric oxygen with hyperbaric oxygen. *Ann Emerg Med* 1994; **24**: 269–276
- 33 Gale SD, Hopkins RO, Weaver LK, et al. MRI, quantitative MRI, SPECT and neuropsychological findings following carbon monoxide poisoning. *Brain Inj* 1999; **13**: 229–243
- 34 Haldane JS. *Admiralty Report on Deep Water Diving*, London: HMSO, 1907: CN 1549
- 35 End E, Long CW. HBO in carbon monoxide poisoning. I. Effect on dogs and guinea pigs. *J Ind Hyg Toxicol* 1942; **24**: 302–306
- 36 Smith G, Ledingham IM, Sharp GR, et al. Treatment of coal-gas poisoning with oxygen at 2 atmospheres pressure. *Lancet* 1962; **1**: 816–818
- 37 Weaver LK, Hopkins RO, Chan KJ, et al. Hyperbaric oxygen for acute carbon monoxide poisoning. *N Engl J Med* 2002; **347**: 1057–1067
- 38 Thom SR. Hyperbaric-oxygen therapy for acute carbon monoxide poisoning. *N Eng J Med* 2002; **347**: 1105–1106
- 39 Gorman DF, Clayton D, Gilligan JE, et al. A longitudinal study of 100 consecutive admissions for carbon monoxide poisoning to the Royal Adelaide Hospital. *Anaesth Intensive Care* 1992; **20**: 311–316
- 40 Ducasse JL, Celsis P, Marc-Vergnes JP. Non-comatose patients with acute carbon monoxide poisoning: Hyperbaric of normobaric oxygenation? *Undersea Hyperb Med* 1995; **22**: 9–15
- 41 Thom SR, Taber RL, Mendiguren II, et al. Delayed neuropsychologic sequelae after carbon monoxide poisoning: Prevention by treatment with hyperbaric oxygen. *Ann Emerg Med* 1995; **25**: 474–480
- 42 Jasper BW, Hopkins RO, Duker HV, et al. Affective outcome following carbon monoxide poisoning: A prospective longitudinal study. *Cogn Behav Neurol* 2005; **18**: 127–134
- 43 Harch PG, Gottlieb SF, Van Meter KW, et al. HMPAO SPECT brain imaging and low pressure HBOT in the diagnosis and treatment of chronic traumatic, ischemic, hypoxic and anoxic encephalopathies. *Undersea Hyperb Med* 1994; **21** (Suppl.): 30
- 44 Neubauer RA, Gottlieb SF, Kagan RL. Enhancing “idling” neurons. *Lancet* 1990; **335**: 542
- 45 Neubauer RA, Gottlieb SF, Miale A, Jr. Identification of hypometabolic areas in the brain using brain imaging and hyperbaric oxygen. *Clin Nucl Med* 1992; **17**: 477–481
- 46 Neubauer RA. Severe natural gas poisoning successfully treated with hyperbaric oxygen: 2 years later. Present at the 5th International Congress on Neurotoxicity and Occupational Neurology, 1990, Prague, Yugoslavia
- 47 Harch PG, Gottlieb SF, Van Meter KW, et al. HMPAO SPECT brain imaging of acute CO poisoning and delayed neuropsychological sequelae (DNSS). *Undersea Hyperb Med* 1994; **21** (Suppl.): 15
- 48 Harch PG, Gottlieb SF, Van Meter KW, et al. The effect of HBOT tailing treatment on neurological residual and SPECT brain images in type II (cerebral) DCI/CAGE. *Undersea Hyperb Med* 1994; **21** (Suppl.): 22
- 49 Francis TJR, Gorman DF. Pathogenesis of the decompression disorders. In: Bennett PB, Elliot DH, eds. *The Physiology and Medicine of Diving*, 4th edn, London: WB Saunders, 1993: pp. 454–480
- 50 Scheinkestel CD, Bailey M, Myles PS, et al. Hyperbaric or normobaric oxygen for acute carbon monoxide poisoning: A randomised controlled clinical trial. *Med J Aust* 1999; **170**: 203–210
- 51 Mathieu D, Wattel F, Mathieu-Nolf M, et al. Randomized prospective study comparing the effect of HBO versus 12 hours NBO in non-comatose CO poisoned patients: Results of the interim analysis. *Undersea Hyperb Med* 1996; **23** (Suppl): 7–8
- 52 Kehat I, Shupak A. Hyperbaric oxygen vs. normobaric oxygen in carbon monoxide intoxication. *Undersea Hyperb Med* 2000; **27**: 47
- 53 Sperling J, Olmedo R. HBO still standard for carbon monoxide poisonings. *Emerg Med News* 2000; XXII: 2, 31
- 54 Gorman DF, Runciman WB. Carbon monoxide poisoning. *Anaesth Intensive Care* 1991; **19**: 506–511
- 55 Myers RAM, Snyder SK, Emhof TA. Subacute sequelae of carbon monoxide poisoning. *Ann Emerg Med* 1985; **14**: 1163–1167
- 56 Norkool DM, Kilpatrick JN. Treatment of acute carbon monoxide poisoning with hyperbaric oxygen: A review of 115 cases. *Ann Emerg Med* 1985; **14**: 1168–1171
- 57 Sawada Y, Takahashi M, Ohashi N, et al. Computerised tomography as an indication of long-term outcome after acute carbon monoxide poisoning. *Lancet* 1980; **12**: 783–784
- 58 Yang ZD, Sun CQ, Cao XI. Clinical analysis of the effect of hyperbaric oxygen therapy in 672 cases with acute carbon monoxide poisoning. Present at the 5th Chinese Conference on Hyperbaric Medicine, 1986, Fuzhou, China
- 59 Mathieu D, Nolf M, Durocher A, et al. Acute carbon monoxide poisoning. Risk of late sequelae and treatment by hyperbaric oxygen. *Clin Toxicol* 1985; **23**: 315–324
- 60 Zhang JD, Qu ZK, Jia SJ. Fifty cases of HBO composite treatment of severe carbon monoxide intoxication. Present at the 5th Chinese Conference on Hyperbaric Medicine, 1986, Fuzhou, China
- 61 Timchuk ID, Luchko AS, Palamarchuk VN, et al. Hyperbaric oxygenation in complex treatments of acute poisonings. Present at the 7th International Congress on Hyperbaric Medicine, 1981, Moscow, USSR
- 62 Holbach KH, Caroli A, Wassman H. Cerebral energy metabolism in patients with brain lesions at normo- and hyperbaric oxygen pressures. *J Neurol* 1977; **217**: 17–30
- 63 Hampson NB, Simonson SG, Kramer CC, et al. Central nervous system oxygen toxicity during hyperbaric treatment of patients with carbon monoxide poisoning. *Undersea Hyperb Med* 1996; **23**: 215–219
- 64 Brosemer RW, Rutter WJ. The effect of oxygen tension on the growth and metabolism of a mammalian cell. *Exp Cell Res* 1961; **25**: 101–113
- 65 Moon RE, de Lisle DG, Stolp BW. Treatment of decompression illness and iatrogenic gas embolism. *Respir Care Clin N Am* 1999; **5**: 93–135
- 66 Hampson NB, Dunford RG, Norkool DM. Treatment of carbon monoxide poisonings in multiplace hyperbaric chambers. *J Hyperb Med* 1992; **7**: 165–171
- 67 Van Meter KW. Medical field management of the injured diver. *Respir Care Clin N Am* 1999; **5**: 137–177
- 68 Sheffield PJ. Tissue oxygen measurements. In: Davis JC, Hunt TK, eds. *Problem Wounds: The Role of Oxygen*, New York: Elsevier, 1988: pp. 17–51
- 69 Thom SR. Functional inhibition of leukocyte beta 2 integrins by hyperbaric oxygen in carbon monoxide-mediated brain injury in rats. *Toxicol Appl Pharmacol* 1993; **123**: 248–256
- 70 Goulon M, Barrios A, Rapin M. Carbon monoxide poisoning and acute anoxia due to breathing coal gas and hydrocarbons. *J Hyperb Med* 1986; **1**: 23–41
- 71 Oriani G, Michael M, Tuscano R, et al. Outcome of patients suffering from CO poisoning. *Undersea Hyperb Med* 1996; **23** (Suppl.): 83
- 72 Pracyk JB, Stolp BW, Fife CE, et al. Brain computerized tomography after hyperbaric oxygen therapy for carbon monoxide poisoning. *Undersea Hyperb Med* 1996; **22**: 1–7
- 73 Harch PG, Neubauer RA. Hyperbaric oxygen therapy in global cerebral ischemia/anoxia and coma. In: Jain KK, ed. *Textbook of Hyperbaric Medicine*, 3rd edn, Seattle, WA: Hogrefe & Huber Publishers, 1999: pp. 319–349

- 74 Thalmann ED. Principles of U.S. navy recompression treatments for decompression sickness. In: Moon RE, Sheffield PJ, eds. *Treatment of Decompression Illness*, Kensington, MD: Undersea and Hyperbaric Medical Society, 1996: pp. 194–221
- 75 Harch PG. Late treatment of decompression illness and use of SPECT brain imaging. In: Moon RE, Sheffield PJ, eds. *Treatment of Decompression Illness*, Kensington, MD: Undersea and Hyperbaric Medical Society, 1995: pp. 203–242
- 76 Van Meter K. Carbon monoxide poisoning. In: Tintinalli J, ed. *Emergency Medicine: A Comprehensive Study Guide*, 5th edn, New York: McGraw-Hill, 2000: pp. 1302–1306
- 77 Van Meter KW, Weiss L, Harch PG. Hyperbaric oxygen in emergency medicine. In: Jain KK, ed. *Textbook of Hyperbaric Medicine*, 3rd edn, Seattle, WA: Hogrefe & Huber Publishers, 1999: pp. 557–587
- 78 Shn-rong Z. Hyperbaric oxygen therapy for coma (a report of 336 cases). Present at *the 11th International Congress on Hyperbaric Medicine*, 1995, Fuzhou, China
- 79 Myers RAM, Thom S. Carbon monoxide and cyanide poisoning. In: Kindwall EP, ed. *Hyperbaric Medicine Practice*, 2nd edn, Flagstaff, AZ: Best Publishing, 1995: pp. 343–372
- 80 Millar I. Carbon monoxide poisoning, the Australian clinical trial. Present at *Hyperbaric Medicine 2000 Advanced Topics Symposium*, 2000, Columbia, SC, USA
- 81 Stoller KP. Quantification of neurocognitive changes before, during, and after hyperbaric oxygen therapy in a case of fetal alcohol syndrome. *Pediatrics* 2005; **116**: e586–e591
- 82 Stoller KP. Quantification of neurocognitive changes before and after delayed hyperbaric oxygen therapy in a case of carbon monoxide poisoning. Present at *the Undersea and Hyperbaric Medical Society Gulf Coast Chapter 2004 Annual Scientific Meeting*, 2004, Dallas, TX, USA
- 83 Collins MW, Lovell MR, Mckeag DB. Current Issues in managing sports-related concussion. *JAMA* 1999; **282**: 2283–2285
- 84 Collins MW, Grindel SH, Lovell MR, et al. Relationship between concussion and neuropsychological performance in college football players. *JAMA* 1999; **282**: 989–991
- 85 Iverson GL, Lovell MR, Collins MW. Interpreting change on ImPACT following sport concussion. *Clin Neuropsychol* 2003; **17**: 460–467
- 86 Saint Hilaire MHS, Burke RE, Bressman SB, et al. Delayed-onset dystonia due to perinatal or early childhood asphyxia. *Neurology* 1991; **41**: 216–222
- 87 Burke RE, Fahn S, Gold AP. Delayed-onset dystonia in patients with “static” encephalopathy. *J Neurol Neurosurg Psychiatry* 1980; **43**: 789–797
- 88 Steindler DA, Pincus DW. Stem cells and neurogenesis in the adult human brain. *Lancet* 2002; **359**: 1047–1054
- 89 Ziser A, Shupak A, Halpern P, et al. Delayed hyperbaric oxygen treatment for acute carbon monoxide poisoning. *Br Med J (Clin Res Ed)* 1984; **289**: 960
- 90 Ersanli D, Yildiz S, Togrol E, et al. Visual loss as a late complication of carbon monoxide poisoning and its successful treatment with hyperbaric oxygen therapy. *Swiss Med Wkly* 2004; **134**: 650–655
- 91 Gibson AJ, Davis FM, Ewer T, et al. Delayed hyperbaric oxygen therapy for carbon monoxide intoxication—two case report. *N Z Med J* 1991; **104**: 64–65
- 92 Weaver LK, Hopkins RO, Chan KJ, et al. Carbon Monoxide Research Group, LDS Hospital, Utah in reply to Scheinkestel et al. and Emerson: The role of hyperbaric oxygen in carbon monoxide poisoning. *Emerg Med Australa* 2004; **16**: 394–399
- 93 Brvar M, Mozina H, Osredkar J, et al. The potential value of the protein S-100B level as a criterion for hyperbaric oxygen treatment and prognostic marker in carbon monoxide poisoned patients. *Resuscitation* 2003; **56**: 105–109
- 94 Elkharrat D, Raphael JC, Korach JM, et al. Acute carbon monoxide intoxication and hyperbaric oxygen in pregnancy. *Intensive Care Med* 1991; **17**: 289–292